

Invited Review

Barrett esophagus and cancer: pathogenesis, carcinogenesis, and diagnostic dilemmas

W. Polkowski^{1,2,3}, J.J.B. van Lanschot¹ and G.J.A. Offerhaus²

Departments of ¹Surgery and ²Pathology, Academic Medical Center, University of Amsterdam, The Netherlands and

³Second Department of General Surgery, Medical Academy in Lublin, Poland

Summary. A metaplastic process, in which native squamous epithelium of the distal esophagus is replaced by columnar epithelium, is known as Barrett esophagus (BE). Over the past years, intestinal metaplasia was recognized as a marker for BE. The risk for the development of esophageal adenocarcinoma in a patients with BE is much higher when compared to the normal population. Duodeno-gastro-esophageal reflux is supposed to play a role in the pathogenesis of BE and rising incidence of adenocarcinoma of the esophagus. With current therapeutic options, when clinical manifestation of this cancer occurs, it is too late for cure in the majority of patients. Therefore, attention should be focused on early diagnosis, for which molecular genetic techniques might become available. Current data on genetic alterations involved in carcinogenesis of BE are discussed. Grading of dysplasia in BE carries important clinical consequences for the individual patient: intensification of endoscopic surveillance or 'prophylactic esophagectomy'. Several morpho- and/or cytometric parameters may be used for discrimination between different grades of dysplasia in BE. Therefore, a new and original algorithm for the potential application of quantitative pathology in grading of dysplasia in patients with BE has been proposed. Molecular biology together with image analysis of histological spectrum of BE enable better understanding of the mechanisms of malignant degeneration and might ultimately lead to targeted cancer prevention and/or therapeutic interventions.

Key words: Barrett esophagus, Adenocarcinoma, Pathogenesis, Molecular biology, Dysplasia

Introduction

A metaplastic process, in which native squamous epithelium of the distal esophagus is replaced by columnar epithelium, was already described at the beginning of this century (Tileston, 1906). Initially, attention was paid to the presence of peptic ulcers in the esophagus, lined with gastric-type mucosa (Lyall, 1937; Allison, 1948). In 1950, Norman Barrett interpreted this condition as a tubular segment of the stomach transposed within the chest due to a congenitally short esophagus (Barrett, 1950). Since 1953, when Allison and Johnston suggested the concept of an esophagus lined with columnar epithelium and referred to it as "Barrett ulcer" in their publication, Barrett's name was erroneously connected to this condition (Allison and Johnstone, 1953). In the same year, Morson and Belcher described cases of esophageal adenocarcinoma arising in 'ectopic' gastric mucosa (Morson and Belcher, 1952). After 45 years, the clinical relevance of Barrett esophagus (BE) is its malignant potential rather than ulceration (Komorowski et al., 1996). Most adenocarcinomas of the esophagus or gastro-esophageal junction (GEJ) arise in the background of BE (Hamilton et al., 1988). This so-called Barrett cancer is now the most rapidly increasing malignancy in the Western world (Hesketh et al., 1989; Blot et al., 1991, 1993; Powell and McConkey, 1992; Pera et al., 1993). The prevalence of BE in patients undergoing upper gastro-intestinal endoscopy has been estimated at 0.7% (Cameron and Lomboy, 1992). The prevalence of BE in autopsy series is over 20 times greater than expected based on observations in living subjects (Cameron et al., 1990). The true prevalence of BE is unknown because the metaplastic mucosa seems to be more resistant to the components of gastro-esophageal reflux and therefore is frequently asymptomatic. Patients without complications (ulcer, stricture, carcinoma) often do not seek medical help. Therefore, presumably the overwhelming majority of patients with BE remain undiagnosed. The premalignant character of this condition was established by a 10%

Offprint requests to: Wojciech Polkowski, M.D., Ph.D., 2nd Department of General Surgery, Medical Academy in Lublin, Staszica 16, 20-081 Lublin, Poland. Fax: +48 81 53 288 10. e-mail: wojpolk@panaceum.am.lublin.pl.

incidence of adenocarcinomas in a series of 140 cases of extensive columnar metaplasia (Naef et al., 1975). The risk for the development of an adenocarcinoma in a patient with BE is 30-125 times higher when compared to the normal population (Haggitt, 1994). The average time-interval from the development of BE (median age: 40) to the clinical presentation of Barrett cancer (mean age: 64) was estimated at 20-30 years (Cameron, 1993). With current therapeutic options, when clinical manifestation of this cancer occurs, it is too late for cure in the majority of patients. Therefore, attention should be focused on early diagnosis, for which molecular genetic techniques might become available. Moreover, molecular biology enables us to better understand the mechanisms of malignant degeneration in BE and might ultimately lead to targeted cancer prevention and/or therapeutic interventions.

Definition of Barrett esophagus

In 1976, the histological features of BE were classified by Paull et al. who described three types of columnar epithelia lining the distal esophagus: 1) a cardiac- or junctional-type, 2) a fundic-type (both also called gastric-type), and 3) a specialized (intestinal-type) columnar epithelium (Paull et al., 1976). The last type resembles intestinal mucosa and is characterized by the presence of goblet cells. This intestinal metaplasia is readily distinguishable from the two former types usually found in the gastric cardia or fundus, and therefore it was also called distinctive-type epithelium. The risk for the development of an adenocarcinoma is specifically increased in patients with this distinctive-type epithelium. Initially, it was generally accepted that 1-2 cm length of the distal esophagus is normally lined with columnar epithelium. In 1983, to avoid a false-positive diagnosis of BE, an arbitrary definition of at least 3 cms of circumferential columnar lining of the tubular esophagus was proposed (Skinner et al., 1983). At the beginning of the 1990s, it became clear that adenocarcinoma of the esophagus or GEJ can arise from a so-called short segment of BE or even a tongue of BE (Schnell et al., 1992). However, the extension of Barrett mucosa appeared a significant risk factor for malignant degeneration (Menke-Pluymers et al., 1993). On the other hand, the histological prevalence of intestinal metaplasia at the GEJ in patients without an endoscopically apparent BE was recently found to be unexpectedly high (7%-36%) (Spechler et al., 1994; Johnston et al., 1996; Chalasani et al., 1997; Morales et al., 1997; Nandurkar et al., 1997; Trudgill et al., 1997). Thus, extensive (long) segments of BE carry a high risk of malignant transformation, but they are presumably easy to recognize during endoscopy and occasionally symptomatic (e.g. ulcer - pain, stricture - dysphagia) (Macdonald et al., 1997). Although (ultra-)short segments of BE or even microscopic foci of intestinal metaplasia at the GEJ may be common, their presence may not be related to subjective symptoms of reflux

(Clark et al., 1994; Nandurkar et al., 1997). In this regard intestinal metaplasia at the GEJ might therefore carry a relatively high risk of developing 'undetected' cancer. However, it has been shown that the prevalence of high-grade dysplasia or adenocarcinoma in patients with traditional long segment BE (11/60; 18%) was higher than in patients with short segment BE (0/59; 0%) (Weston et al., 1997b). In a prospective follow-up study (12-40 months), out of 26 patients with short segment BE neither high-grade dysplasia nor cancer developed in any of these patients; in contrast, out of 29 patients with traditional long segment BE high-grade dysplasia or intramucosal carcinoma developed in three patients (Weston et al., 1997a). Moreover, BE is found most commonly in patients thought to be at risk for esophageal adenocarcinoma (Caucasians with reflux symptoms; 28%). BE is rarely seen in an other group with lower risk for this malignancy (Afro-American nonrefluxers; 0%). Conversely, intestinal metaplasia at the GEJ is common in both aforementioned groups (10% and 11%, respectively) and is of questionable significance (Chalasani et al., 1997). Intestinal metaplasia at the GEJ may affect even one third of the population, but the incidence of adenocarcinoma at the GEJ is only 2-4 cases per 100,000 (Blot et al., 1991; Nandurkar et al., 1997).

The most recent definition of BE has been proposed by Spechler: "the condition in which the distal esophagus is lined by metaplastic columnar epithelium that predisposes to the development of adenocarcinoma" (Spechler, 1997a). This definition does not explicitly take into account two aspects which usually occur in the definitions proposed so far, i.e. the presence of "goblet cells" and the "acquired" nature of BE.

The columnar esophageal mucosa with goblet cells carries the risk of malignant degeneration. In the distal 2 cm of the esophagus only fundic or cardiac (both called: gastric-) type may occur without the presence of intestinal-type BE. Above this 2 cm zone the gastric-type mucosa is virtually never present alone, i.e. without intestinal metaplastic epithelium (goblet cells) (Haggitt, 1994). A histological diagnosis of the distinctive-type epithelium was conventionally used to prove that an endoscopic biopsy comes from the esophagus, and not from a sliding herniated stomach. The central argument was that intestinal metaplasia supposedly does not occur at the GEJ. As discussed above, this argument is no longer valid. In patients without endoscopically apparent BE, specialized intestinal metaplasia at the GEJ can be found on average in 20% of patients (Spechler et al., 1994; Johnston et al., 1996; Chalasani et al., 1997; Morales et al., 1997; Nandurkar et al., 1997; Spechler, 1997b; Trudgill et al., 1997). In BE mucosa, the epiphenomenon of goblet cells may be less prominent than the presence of immature metaplastic columnar cells secreting acidic mucins staining positive with alcian blue pH 2.5, which are also considered to be specific for intestinal metaplasia (see below) (Offner et al., 1996). This might especially be true in the region of

the GEJ. Surveillance biopsy specimens of BE mucosa frequently demonstrate an absence of goblet cells in patients with short segment BE compared with patients with traditional long segment BE (Weston et al., 1997a). This might explain why, over the past years, intestinal metaplasia was recognized as a marker for BE and was missed at the GEJ. Regular use of alcian blue staining for endoscopic biopsies may double recognition of intestinal metaplasia at the GEJ (Nandurkar et al., 1997).

Like the upper respiratory tract, the fetal esophagus is lined with columnar ciliated epithelium that is replaced with squamous epithelium before birth (Johns, 1952). Congenital islands (rests) of a columnar lining without intestinal metaplasia can occasionally be seen in the esophagus of children without gastro-esophageal reflux (Rector and Connerley, 1941). Another possibility for the presence of columnar epithelium in the esophagus, is gastric heterotopia (ectopia), which presumably is the result of misplacement during embryonic development (Hamilton, 1990). In adults, these 'inlet patches' (uniformly fundic-type gastric mucosa) are usually located in the upper part of the esophagus (Borhan-Manesh and Farnum, 1991). Both in children and in adults, distinctive-type epithelium in the esophagus is a consequence of reflux and not of congenital origin (Dahms and Rothstein, 1984; Hassall, 1993).

Pathogenesis of Barrett esophagus

Metaplasia is a transition from the original tissue into another that is normally not encountered at that particular site. It is felt to be an adaptation to environmental noxious stimuli and is an acquired condition during life (Jankowski, 1993). This contrasts with *ectopia (heterotopia)* which is congenital and refers to misplacement of tissue that does not belong to the particular site. In the process of metaplasia, progenitor stem cells differentiate into a phenotype other than that normally constituting the organ. It has been speculated that in BE this multipotential cell may originate either from the basal layer of adjacent intact squamous epithelium, or from the ducts of superficial esophageal mucous glands (Gillen et al., 1988). Recently, an intermediate stage in this transformation process has been characterized by electron microscopy (Sawhney et al., 1996). Within BE, a multilayered epithelium consisting of these transitional hybrid cells was shown to express concurrently both squamous and glandular cytokeratin markers (Boch et al., 1997).

The association between GERD and BE is usually explained by a role of the gastric content, being constantly refluxed into the esophagus, and leading to inflammatory destruction of the esophageal squamous epithelium. However, it remains unclear why pathological gastro-esophageal reflux results in squamous esophagitis in some persons and in specialized columnar metaplasia in others. Probably, gastric acid alone does not contribute by itself to the development of

BE, since BE is uncommon in patients with Zollinger-Ellison syndrome who have a normally functioning lower esophageal sphincter (LES) (Strader et al., 1995). A mechanically defective LES, as well as functional disorders (like frequent transient LES relaxations and motor disorders of the esophageal body) promote pathological gastro-esophageal reflux and/or poor esophageal clearance. The severity of acid reflux in patients with uncomplicated BE was not greater than in patients with reflux esophagitis of comparable age (Neumann and Cooper, 1994). It has been suggested that the depth of mucosal injury determines either squamous, or columnar re-epithelialization (Li et al., 1994). The degree of mucosal damage (as found in BE) increases when duodenal juice is refluxed into the esophagus (Kauer et al., 1995). The reflux of gastric juice contaminated with duodenal contents is probably the most important determinant for the mucosal injury in GERD and the ultimate development of BE in a subset of refluxers (Stein et al., 1992; Kauer et al., 1995). There is increasing interest in the role of bile, as one of the crucial components of BE-inducing refluxate (Marshall et al., 1997). It may well be that a specific composition of the refluxate is responsible for the intestinal phenotype of columnar metaplasia in the esophagus. This duodenal-like composite is characterised by proteo- and lipolytic activity that theoretically might have at least three possible sources: 1) bile with pancreatic enzymes secreted to the duodenum; 2) enzymes produced by the gastric mucosa; and 3) *Helicobacter pylori (H. pylori)*.

Especially patients with duodeno-gastro-esophageal reflux ultimately seem to develop BE and its complications (Attwood et al., 1993). Previously, it has been suggested that bile and trypsin are not important in the pathogenesis of BE, since esophageal bile acid concentrations were shown not to be different in patients with normal esophageal lining or with BE, and trypsin was found in only 5% of the esophageal aspirates (Gotley et al., 1992). These data, at least concerning the role of bile, have recently been challenged by Vaezi et al. and by Kauer et al. who used more sophisticated technology (Kauer et al., 1995; Vaezi and Richter, 1995). The positive correlation between total bilirubin content and the concentrations of pancreatic enzymes contained in the esophageal refluxate suggests that bilirubin is a good tracer for duodenal reflux into the esophagus (Stipa et al., 1997). Patients with BE had a higher prevalence of abnormal esophageal bilirubin exposure than patients with no injury (Kauer et al., 1995). Using a radioisotope technique it has been shown that duodeno-gastric reflux might be involved in the development of BE and might be related to complications of BE (Liron et al., 1997). Patients after previous gastric resection form an optimal population to study duodeno-gastro-(esophageal) reflux. Bile and pancreatic enzyme concentrations of esophageal fluid samples were found to be higher in patients after gastrectomy compared to patients with an intact stomach. However, with regard to the prevalence

of BE, no significant differences were found between a group of patients after previous gastric surgery and a group of patients with an intact stomach (Parrilla et al., 1997). Moreover, previous gastric surgery rarely leads to esophageal adenocarcinoma (Birgisson et al., 1997). This suggests that gastric surgery and its associated duodeno-gastric reflux do not play a role in the etiology and rising incidence of adenocarcinoma of the esophagus. Apparently, there must be factors other than bile and pancreatic juice, involved in the pathogenesis of BE.

One of these factors could be gastric lipase. Lipase is an enzyme which is active both in the duodenum (of pancreatic origin), and in the stomach (of gastric origin). In adult humans, gastric lipase is the first lipolytic enzyme involved in the digestion of dietary lipids along the gastrointestinal tract. In healthy subjects, nearly 20% of lipids are digested by gastric lipase (Carriere et al., 1993). In contrast to enzymes of pancreatic origin, 70-90% of gastric lipase activity can be recovered at pH values below 6 during a test meal (Carriere et al., 1993). However, it has also been reported that, in the absence of food, simultaneous secretion of gastric acid counteracts the lipolytic activity of gastric lipase (Wojdemann et al., 1995). Experimental data on the protective role of gastric juice for the development of esophageal metaplasia and adenocarcinoma are of special interest in this regard (Ireland et al., 1996). Human gastric lipase can be immunolocalized in the chief cells of the fundic-type gastric mucosa (Moreau et al., 1988, 1989). Recently, the presence of pancreatic (acinar) metaplasia producing different pancreatic enzymes (trypsin, amylase, lipase) has been described in the gastric mucosa (Doglioni et al., 1993). Not only focal, but also diffuse pancreatic metaplasia of the gastric mucosa has been observed (Stachura et al., 1995). Pancreatic metaplasia most frequently occurs in the cardia, and it is associated with the presence of intestinal metaplasia at the GEJ (Wang et al., 1996). Pancreatic metaplasia has also been described in BE (Krishnamurthy and Dayal, 1995). The extent of enzymatic activity originating from these metaplastic acinar cells, as well as the optimal pH spectrum, are not known.

The third possible source of proteo- and lipolytic activity in the stomach and/or in BE, might be *H. pylori* which by weakening of the integrity of the mucous layer can render the underlying epithelium more vulnerable to noxious luminal contents (Slomiany et al., 1994). The microorganism is able to colonize not only the human stomach (thereby surviving in a strongly acidic gastric luminal environment), but also BE epithelium. The prevalence of *H. pylori* was found to be similar in patients with BE and in patients with esophagitis (Loffeld et al., 1992). It was assumed that the finding of *H. pylori* in BE epithelium reflects a shift of the bacterium from the gastric antrum and/or corpus. However, as long as the lower esophageal sphincter (LES) is competent, none of the components of gastric juice (acidic niche for *H. pylori*) will be present in the

esophagus. Moreover, duodeno-gastric (alkaline) reflux, which might be needed to induce BE in some cases, would eventually wipe out *H. pylori* from the stomach. The hypothetical role of *H. pylori* in the pathogenesis of BE is questioned. There is lack of any causal relationship between *H. pylori* infection either in the stomach or in the esophagus, and BE or subsequent adenocarcinoma (Csendes et al., 1997; Quddus et al., 1997). The intriguing hypothesis that *H. pylori* "protects" against GEJ cancer is based on a belief that the bacterium plays a suppressive role in the tumor progression. An experimental study in rats revealed the protective role of gastric acid for the development of esophageal adenocarcinoma (Ireland et al., 1996). In humans, *H. pylori* in BE might rather be an epiphenomenon of gastro-esophageal (acidic) reflux and a sign of inflammation in the cardia (Morales et al., 1997).

A recent hypothesis has postulated a relationship between two events: on the one hand the biological sequence of LES relaxation (gastro-esophageal reflux) eventually leading to the development of BE, and on the other hand the time sequence of the increasing use of pharmaceutical agents that (un-) intentionally relax the LES (Wang et al., 1994). For example, calcium-channel inhibitors (e.g. nifedipine) are used to treat arterial hypertension, but they are also effective in mild achalasia. It is also known that inhibition of nitric oxide synthesis, which is an inhibitory neurotransmitter of LES relaxation, facilitates mucosal injury (Stark and Szurszewski, 1992). Clinical states associated with nitric oxide deficiency are often accompanied by vasoconstriction, which can be reversed by nifedipine (Dijkhorst-Oei et al., 1997).

In the era of (over-)use of antisecretory drugs (H_2 -receptor antagonists/proton pump inhibitors), it is intriguing to speculate that gastric proteo- and/or lipolytic enzyme activity, unopposed by an acidic environment, together with LES incompetence and inflammation at the GEJ, may be responsible for the development of BE even without duodeno-gastro-esophageal reflux.

Intestinal metaplasia can be recognized by the presence of goblet cells, which are interspaced by numerous columnar cells. Intestinal metaplasia in the esophagus, as it was originally described for gastric intestinal metaplasia, can be generally divided into complete and incomplete types (Filipe, 1989). The columnar epithelial cells of the complete-type are well-differentiated, with a delicate brush border (absorption). The incomplete-type intestinal epithelium is immature, less differentiated than its completely intestinalized counterpart, and it is characterized by mucus-producing columnar cells (staining positive with alcian blue pH 2.5). An additional feature of this immaturity is a disruption of the intercellular junctions. Most cells continue their vital activities, such as differentiation and proliferation, while maintaining homeostasis, through intercellular communication *via* gap junctions (Loewenstein, 1981). These gap junctions are

Barrett esophagus and cancer

Table 1. Current data on genetic alterations involved in carcinogenesis of BE.

	METAPLASIA (without dysplasia)	LOW-GRADE DYSPLASIA	HIGH-GRADE DYSPLASIA	ADENOCARCINOMA
<i>Growth Factors</i>				
TGF α				100% (Yacoub et al., 1997)
EGFR	20% (al-Kasspooles et al., 1993)			31% (al-Kasspooles et al., 1993); 64% (Yacoub et al., 1997)
<i>Mismatch Repair Genes</i>				
microsatellite instability	7% (Meltzer et al., 1994)			13% (Keller et al., 1995) 22% (Meltzer et al., 1994) 35% (Muzeau et al., 1997)
<i>Tumor Suppressor Genes</i>				
p53 mutations	0 (Schneider et al., 1996; Gonzalez et al., 1997)	0 (Schneider et al., 1996; Gonzalez et al., 1997)	33% (Schneider et al., 1996)	46% (Schneider et al., 1996)
p53 LOH (17p)	0 (Gonzalez et al., 1997)			90% (Gonzalez et al., 1997) 100% (Barrett et al., 1996a)
p53 protein accumulation*	4%	21%	65%	64%
APC mutations	0 (Gonzalez et al., 1997)	0 (Gonzalez et al., 1997)		7% (Gonzalez et al., 1997)
APC LOH (5q)	0 (Gonzalez et al., 1997)	0 (Gonzalez et al., 1997)		60% (Gonzalez et al., 1997) 80% (Barrett et al., 1996a)
CDKN2 deletions	0 (Gonzalez et al., 1997)			21% (Gonzalez et al., 1997)
CDKN2 LOH (9p)		9% (Gonzalez et al., 1997)		64% (Barrett et al., 1996a) 91% (Gonzalez et al., 1997)
			100% (Barrett et al., 1996b)**	
DPC4 mutations				0 (Barrett et al., 1996c)
DPC4 LOH (18q)				46% (Barrett et al., 1996c)
<i>Oncogenes</i>				
cyclin D1 (Arber et al., 1996)		25%-38%		
c-erbB-2		0 (Hardwick et al., 1995)		11%-73%***
bcl-2 (Katadav 1997)	72%	100%	25%	20% - 40%
c-myc (Abdelatif et al., 1991)	-	+	+	+
K-ras	0 (Lagorce 1995) 0,4% (Trautmann 1996)	0 (Meltzer et al., 1990; Lagorce et al., 1995); 4% (Trautmann et al., 1996)		0 (Lagorce et al., 1995) 36% (Trautmann et al., 1996)
H-ras (Abdelatif et al., 1991)	-	-	+	+
N-ras (Meltzer et al., 1990)		-		
src	3-4 x higher than in controls (Kumble 1997)			6 x higher than in controls (Kumbl et al., 1997) 20% (Jankowski et al., 1992a)
<i>Cell adhesion molecules</i>				
E-cadherin		reduced expression (Bongiorno 1995; Swami 1995)		74% (Krishnadath et al., 1997)
β -catenin				72% (Krishnadath et al., 1997)
CD44H (Castella et al., 1996)	focal	diffuse	75%	
CD44v3 (Castella et al., 1996)				60%
Aneuploidy (Reid et al., 1993)	0	7%	40%	71%; 86% (Nakamura et al., 1994)

Data on MCC, IRF-1, and Rb genes are not indicated in the Table, since reports on these genes included both squamous cell carcinomas and adenocarcinomas of the esophagus; separation of the data was not possible. *: cumulative data (Jankowski, 1992; Ramel, 1992; Flejou, 1993; Younes, 1993; Casson et al., 1994; Hamelin et al., 1994; Hardwick et al., 1994; Jones et al., 1994; Moore et al., 1994; Rice et al., 1994; Symmans et al., 1994; Krishnadath et al., 1995). **: premalignant Barrett epithelium. ***: (Jankowski et al., 1992a; al-Kasspooles et al., 1993; Flejou et al., 1994; Nakamura et al., 1994; Hardwick et al., 1995, 1997; Duhaylongsod et al., 1995)

occasionally seen between absorptive columnar cells with villi (complete-type intestinal metaplasia), but not on the membranes of goblet cells (Ohkusa et al., 1993). Non-intestinalized, gastric-type mucosa can prevent diffusion of potentially noxious substances from the foregut lumen, by these tight intercellular gap junctions (Powell, 1981). These tight junctions are markedly reduced or absent in intestinal metaplasia (Uchida et al., 1995). Thus, noxious substances of the gastric refluxate can probably penetrate into a deeper layer of intestinalized (especially incomplete-type) mucosa of the esophagus (lamina propria), which may be a source of growth-factor-related signals for proliferation (see below) (Jankowski, 1993).

Carcinogenesis in Barrett esophagus

Why is the distinctive-type epithelium (especially incomplete-type intestinal metaplasia) in the esophagus or at the GEJ a soil from which adenocarcinomas arise? The rapid epithelial renewal after mucosal injury caused by the (duodeno-)gastro-esophageal reflux may explain some aspects of the malignant potential of this epithelium.

Under normal circumstances cell proliferation is influenced by external growth stimuli which are transduced to the cell nuclei through growth factors and their receptors. Epidermal growth factor (EGF), its receptor (EGFR), and transforming growth factor alpha (TGF α) have been investigated extensively and are structurally and functionally related (Jankowski et al., 1991; Poller et al., 1992; Yacoub et al., 1997). Both EGF and TGF α have been demonstrated in BE mucosa, indicating the possibility of auto-/paracrine growth regulation. Intestinal-type BE is characterized by a greater expression of TGF- α , EGFR, and a higher proliferation rate as expressed by the Ki-67 labelling index, in comparison with normal gastric mucosa and with fundic- or cardiac-type BE epithelium (Jankowski et al., 1991). Amplification of the EGFR gene was found both in BE, and in over 30% of esophageal adenocarcinomas (al-Kasspoles et al., 1993). Increased mitogenesis *per se* is felt to lead to increased mutagenesis (Ames and Gold, 1990).

Cancer is a genetic disease, caused by an accumulation of genome alterations (genetic instability) and characterized by a dysregulation of cell proliferation. In general, there are three genetic routes which contribute to genetic instability and uncontrolled neoplastic proliferation: 1) inactivation of DNA (mismatch) repair genes which normally limit the mutation rate of growth controlling genes; 2) inactivation of tumor suppressor genes which regulate cell growth by inhibition of proliferation; and 3) activation of oncogenes which stimulate cell growth. Recently, a fourth class of genes, mitotic checkpoint genes, was described (Cahill et al., 1998). These latter genes are dominant and lead to chromosomal instability (aneuploidy). Both the mismatch repair genes and the

tumor suppressor genes are recessive genes. This implies that loss of both gene copies (by deletion and/or mutation) is necessary for their inactivation. The deletion of one allele leads to loss of heterozygosity (LOH). It has been suggested that allelic deletions of several loci on which tumor suppressor genes reside (p53, Rb, APC, MCC, and DCC) are important in the initiation and/or progression of most esophageal cancers (Huang et al., 1992). In case of a proto-oncogene (dominant gene), mutation of only one copy makes it (over-) active, and switches it into an oncogene. A constellation of several independent mutations occurring in one cell, gives this cell growth and survival advantage and promotes its neoplastic clonal expansion. In addition to subtle mutational changes and (micro-)deletions, gross chromosomal change is also encountered and both losses and gains can occur. Such genome perturbances lead to genetic instability as reflected by aneuploidy, which can be measured by flow cytometry or determined by karyotyping. Further progression of the malignancy and its invasion beyond the esophageal wall, as well as lymphatic and/or hematogenic spread, might be influenced by aberrations of cell adhesion molecules. Current data on genetic alterations involved in carcinogenesis of BE are summarized in Table 1.

Mismatch repair genes and microsatellite instability

A generalized genetic instability (e.g. through mismatch repair gene defects) leading to an increased cellular mutation rate, may underlie an accumulation of genetic alterations (Loeb, 1994). Microsatellite instability (or replication error phenotype) is a newly recognized molecular phenotype of a substantial fraction of human cancers. The mismatch repair gene defects in these cancers can be recognized by microsatellite instability, i.e. alterations in regions of the genome consisting of short sequences of repeated DNA-nucleotides. At least four different human mismatch repair (MMR) genes (PMS1, PMS2, MLH1, MSH2) have been identified and constantly they are associated with microsatellite instability (Chung and Rustgi, 1995). Recently, the MSH6 gene was added to this group (Edelmann et al., 1997). Microsatellite instability was found in 13%-35% of BE-associated adenocarcinomas (Meltzer et al., 1994; Keller et al., 1995; Muzeau et al., 1997). However, the majority of these tumors demonstrate a low level of microsatellite alterations, at only few loci. Therefore, genetic defects in the DNA mismatch repair system probably do not play an important role in esophageal adenocarcinomas (Gleeson et al., 1996; Muzeau et al., 1997).

Tumor suppressor genes

Mutations of the p53 tumor suppressor gene appear to be the most common genetic lesion in cancer of adult humans. The product of an intact p53 gene, the so-called wild-type protein, restrains cells with damaged DNA

from entering the S-phase of the cell cycle at the G1 checkpoint, and thus allows for DNA repair. In detail, wild-type p53 protein provides its normal function by inducing various proteins leading to cell cycle arrest, DNA repair, and apoptosis (Fig. 1). Alterations of the p53 gene result in the production of a mutant peptide, which is deprived of its normal regulatory function of suppression of cell turnover. The mutant peptide is characterized by a prolonged half-life time due to increased post-translational stability, and therefore it can be visualized by immuno-histochemistry (IHC). In contrast, wild-type protein is normally not detectable by IHC due to a very short half-life time (Rodrigues et al., 1990). Undoubtedly, the most reliable method to investigate p53 mutations is DNA sequencing. Although the sensitivity of IHC for detection of p53 mutations is relatively low, as critically reviewed by Ireland et al., the obvious advantage of this rapid technique is its wide availability in most laboratories (Ireland et al., 1997). Moreover, it may well be that IHC which explores p53 at the protein level is a better test in some cases because mechanisms other than mutation may lead to stabilization and dysfunction of the p53 protein. Several studies using IHC showed increasing p53 accumulation in the dysplasia-carcinoma progression of BE (Flejou et al., 1993; Younes et al., 1993; Hamelin et al., 1994; Hardwick et al., 1994; Jones et al., 1994; Rice et al., 1994; Symmans et al., 1994; Krishnadath et al., 1995; Polkowski et al., 1995). A similar trend was demonstrated in a large prospective multicenter study using DNA sequencing (Schneider et al., 1996). However, no p53 mutations were found in metaplasia or low-grade dysplasia in patients with no concomitant invasive carcinoma (Schneider et al., 1996; Gonzalez et al., 1997). LOH of the p53 gene locus was found in 3 out of 11 (27%) patients with low-grade dysplasia (Gonzalez et al., 1997). On the other hand, it has been shown that patients with p53-immunoreactive low-grade dysplasia progress more rapidly to high-grade dysplasia and/or carcinoma (Younes et al., 1997). In patients with high-grade dysplasia and/or carcinoma, p53 mutations can be found even in diploid cell populations (Neshat et al., 1994). The most frequent site of LOH in esophageal adenocarcinoma is chromosome 17p at the p53 locus (Blount et al., 1991, 1994; Barrett et al., 1996a,b,c). The 17p allelic losses typically occur before 5q (which can

harbour the MCC-, the APC-, and the IRF-1-genes; see below) losses during neoplastic progression of BE, suggesting that p53 inactivation is a relatively early event (Ramel et al., 1992; Blount et al., 1993).

It is generally accepted that in BE, tumor progression via dysplasia into carcinoma is the result of a stepwise accumulation of genetic alterations, including specific mutations and a generalized increasing genetic instability. In this neoplastic process p53 is thought to be a key factor. It has been shown that p53 gene inactivation may be responsible for an accumulation of genetic alterations reflected by increased 4N (G2/tetraploid) cell populations which precede a progression to aneuploidy in BE (Galipeau et al., 1996). The p53 tumor suppressor gene inactivation removes a block to the proliferation of cells that have suffered carcinogenic mutations, and allows for further carcinogenic hits when cells divide. Failure of p53 results in unopposed stimulation by growth factors and oncogenes (like EGFR, *c-erbB-2*, and cyclin D1; see below), and locks the "suicidal" pathway of apoptosis.

The MCC (mutated in colorectal carcinoma) gene is located on chromosome 5q. LOH at the MCC locus occurred in 63% of cases with esophageal carcinoma. It has been suggested that allelic deletion involving MCC may not occur independently of deletions involving other tumor suppressor genes (p53, Rb, DCC) in human esophageal cancer (Huang et al., 1992). Besides the MCC gene, the adenomatous polyposis coli (APC) gene is also a target of the LOH of chromosome 5q frequently observed in gastrointestinal malignancies. While mutations of the APC gene were found frequently in colorectal carcinoma, a low rate of APC mutations in esophageal carcinomas was subsequently identified (Powell et al., 1994). Allelic losses of APC were not detected in patients with BE (metaplasia) or low-grade dysplasia (Gonzalez et al., 1997). This raised the possibility that a gene distinct from APC may be the target of the frequent LOH of chromosome 5q, and that the concomitant loss of the APC gene may just result from a large deletion on this chromosome. This hypothesis was recently confirmed and the minimally lost region common for all cases with LOH at chromosome 5q was identified (5q31.1) as the Interferon Regulatory Factor 1 (IRF-1) gene locus (Ogasawara et al., 1996). Thus, the IRF-1 gene may be the true target of frequent deletions of chromosome 5q in esophageal adenocarcinomas. A possible cooperation of the p53 and IRF-1 genes in response to DNA damage has been suggested (Tanaka et al., 1996).

The frequency of LOH involving chromosome 18q in esophageal adenocarcinoma was estimated at 43% (Barrett et al., 1996a). The principal target genes for these allelic losses may be DCC (deleted in colorectal carcinoma) or DPC4 (deleted in pancreatic carcinoma). In about one fourth of the patients with squamous cell esophageal carcinoma the DCC gene is deleted (Miyake et al., 1994). However, there is a lack of data on the DCC gene status in esophageal adenocarcinoma. The

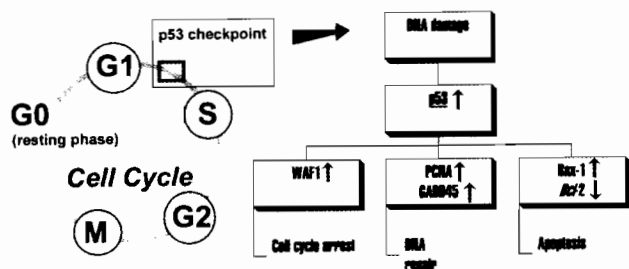


Fig. 1. p53 and cell cycle regulation.

DPC4 gene is similar in sequence to genes implicated in a TGF β -like signalling tumor suppressor pathway. The locus of the DPC4 tumor suppressor gene has been identified at 18q21.1 (Hahn et al., 1996). Mutational analysis of the DPC4 gene as well as allelic loss at 18q21.1 have been investigated in diploid and aneuploid cell populations of (pre-)malignant BE of 35 patients (Barrett et al., 1996c). Allelic loss was found in 16 patients (46%), including 7 patients with premalignant BE only. Moreover, allelic loss was present not only in aneuploid but also in diploid cells of three patients. Mutational analysis of DPC4 did not reveal any inactivating alterations in the gene of these patients. Thus, allelic losses at 18q are frequent in the neoplastic progression of BE, but the targeted gene remains to be identified.

The retinoblastoma (Rb) susceptibility gene protein is permanently present in normal cells, and its activity depends on phosphorylation by cyclin-dependent kinases (cdk). In the G0 phase, dephosphorylated Rb binds to, and holds inactive, gene regulatory proteins that stimulate transcription of target genes (such as *myc*) required for cell proliferation. Phosphorylated Rb releases the stimulating proteins that activate proliferation (Alberts et al., 1995) (Fig. 2). The Rb gene resides on chromosome 13q, and allelic losses of this chromosome were estimated at 43% in esophageal adenocarcinoma (Barrett et al., 1996a). LOH of Rb, as well as point mutations of this gene, were found in patients with esophageal carcinomas (predominantly squamous cell) (Huang et al., 1993). In another study on esophageal carcinoma, 17% of tumor samples did not show expression of the Rb protein (Jiang et al., 1993). Other investigators reported absence of the Rb protein in esophageal tumors, none of which had aberrations of the p53 gene (Esteve et al., 1993).

The CDKN2 (MTS1) gene encodes a 16 kDa protein which belongs to a family of cdk inhibitors (Fig. 2). Inactivation of this gene may lead to uncontrolled cell

growth. The CDKN2 gene is located on chromosomal band 9p21, a locus at which frequent allelic loss occurs in cell lines of esophageal squamous cell carcinomas. In one study from Japan esophageal (squamous cell) carcinomas frequently showed CDKN2 gene mutations, unlike gastric adenocarcinomas (Igaki et al., 1995). In other series of esophageal carcinomas (including adenocarcinomas) reported from Europe, neither allelic loss nor CDKN2 gene mutations were detected (Esteve et al., 1996). However, in a more recent study specifically on Barrett adenocarcinoma both 9p21 LOH and homozygous deletions of the CDKN2 gene were found in 91% (10/11) and 21% (3/14) of tumors, respectively (Gonzalez et al., 1997). These genetic alterations were not present in patients with non-dysplastic BE and in 91% (10/11) of patients with low-grade dysplasia (Gonzalez et al., 1997). This contrasts with the finding by Barrett et al. (1996b) who detected allelic loss of 9p21 within premalignant epithelium in all seven (100%) patients, before cancer had developed. Allelic loss of 9p21 preceded the development of aneuploidy in 13 out of 15 patients (87%) who had aneuploid cell populations detected in premalignant epithelium. About one fourth of aneuploid populations with 9p21 loss had somatic mutations in the remaining CDKN2 allele. The same mutations and 9p21 allelic losses were also found in the corresponding diploid cells from premalignant epithelium. These results suggest that 9p21 allelic losses and CDKN2 mutations are early events (occurring in diploid cells prior to aneuploidy and cancer) during neoplastic progression of BE (Barrett et al., 1996b). Hypermethylation of the promoter region of p16 together with 9p21 LOH is an alternative mechanism for inactivation of MTS1 gene occurring in 38% of esophageal (Barrett) adenocarcinomas (Wong et al., 1997).

A family of polypeptides, known as transforming growth factor beta (TGF β), is the most potent auto-/paracrine inhibitor of the cell cycle progression of epithelial cells. An escape of malignant cells from TGF β -mediated control is postulated to be an important step in tumor progression. These factors act by binding to three types of cell surface receptors (RI, RII, and RIII) (Brattain et al., 1996). There is increasing evidence that the gene encoding TGF β -RII acts as a tumor suppressor gene in colon carcinomas displaying microsatellite instability (Markowitz et al., 1995). Mismatch repair failure makes the TGF β -RII gene particularly prone to mutations and may provide one of the pathways for the development of intestinal-type gastric carcinoma (Chung et al., 1996). Recently, loss of expression of the TGF β -RII gene was shown to be the predominant mechanism through which TGF β -RII is inactivated in esophageal cancer (Garrigue-Antar et al., 1996). An association between microsatellite instability and TGF β -RII inactivation has been assumed in the development of colorectal and gastric cancers, but the role of TGF β -RII in the progression of adenocarcinoma arising in BE still needs to be clarified.

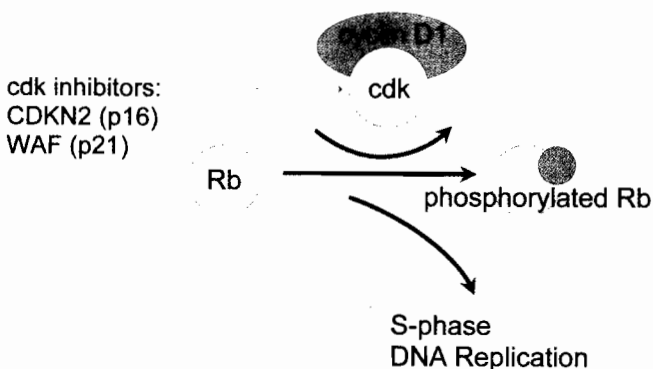


Fig. 2. Mechanism of cyclin D1 action. Cell cycle progression into S-phase requires activation of specific cyclin-dependent kinases (CDK) in association with cyclin D1. This active complex phosphorylates the retinoblastoma (Rb) susceptibility gene protein. Phosphorylated Rb protein releases transcription factors (S-phase effectors).

Oncogenes

The mutated versions of human cellular genes (proto-oncogenes) are termed oncogenes. The proto-oncogenes encode a group of proteins that are normally involved either in signal transduction (from the plasma membrane to the nucleus; Fig. 3) or the regulation of gene expression. The activating mutations of oncogenes increase the activity of these proteins, which results in an excessive stimulus that facilitates uncontrolled cellular proliferation.

The cyclin D1 gene is a candidate proto-oncogene. The cyclin D1 gene encodes the regulatory subunit of the cyclin D1-dependent kinase required for phosphorylation of the Rb protein (Fig. 2). Cyclin D1 is an important regulator of the G1-S phase transition in the cell cycle. Aberrant expression of cyclin D1 on the gene-, mRNA-, and/or protein-level is commonly observed in malignancies of diverse histogenesis (Bartkova et al., 1995). Using immunohistochemistry, increased nuclear expression of the cyclin D1 protein was found in 46% of both dysplastic and non-dysplastic samples of BE (Arber et al., 1996). The authors suggested that cyclin D1 overexpression might predispose BE epithelium to malignant transformation, and that it is an early event in the carcinogenesis of esophageal adenocarcinomas.

The *c-erbB-2* proto-oncogene (also known as HER2/neu) encodes a 185-kDa transmembrane glycoprotein with intrinsic tyrosine kinase activity that is homologous to, but distinct from, the EGFR (Schechter et al., 1984). The *c-erbB-2* protein is activated by specific ligands (neu-differentiation/activating factor, heregulin), but the intracellular mitogenic signal-transduction pathway is incompletely understood. Aberrant *c-erbB-2* protein overexpression governed by amplification of the *c-erbB-2* oncogene occurs in several human adenocarcinomas. The prevalence of *c-erbB-2* overexpression in esophageal adenocarcinoma varies widely between 11% and 73% (Jankowski et al., 1992a; al-Kasspoles et al., 1993; Flejou et al., 1994; Nakamura et al., 1994; Duhaylongsod et al., 1995; Hardwick et al., 1995, 1997). Since *c-erbB-2* overexpression was demonstrated in a proportion of invasive adenocarcinomas but in none of the dysplastic areas, it has been suggested that it is a late event in the dysplasia-carcinoma sequence of BE (Hardwick et al., 1995).

The three isoforms (H-, K-, and N-) of *ras* proteins are cytoplasmic mediators which transmit transduction signals from upstream tyrosine kinases to downstream serine/threonine kinases ultimately leading to a change in gene expression. Mutational activation of *K-ras* proto-oncogenes into oncogenes is thought to promote cell growth even in the absence of extracellular stimuli, and may thereby contribute to initiation and/or progression of tumors (Waldmann and Rabes, 1996). Analysis of 46 resection specimens with various grades of dysplasia and/or invasive cancer in BE did not show any *K-ras* gene mutations (Lagorce et al., 1995). However, other

investigators found amplification of the *K-ras* gene in 4 out of 10 esophageal adenocarcinomas (Galiana et al., 1995). Analysis of *K-ras* mutations in an early phase of carcinogenesis (dysplasia) revealed that this is a rare event (Meltzer et al., 1990; Trautmann et al., 1996). *H-ras* was overexpressed in high-grade dysplasia and carcinoma, but not in low-grade dysplasia or non-dysplastic BE (Abdelatif et al., 1991). Moreover, 4 patients in whom a relative increase in *H-ras* expression was observed, progressed to invasive carcinoma.

The activated cytoplasmic phosphorylation cascade induces an activation of the gene sequence from early- (like *myc*) to late-response genes in the nucleus (Fig. 3). When the *myc*-proto-oncogene is activated by mutation, it prevents the cell from entering the G0-resting phase. Expression of *myc* was not detected in non-dysplastic BE mucosa, but its overexpression was consistently observed in all grades of dysplasia and carcinoma (Abdelatif et al., 1991).

Src family kinases are a group of non-receptor tyrosine kinases that mediate signal transduction

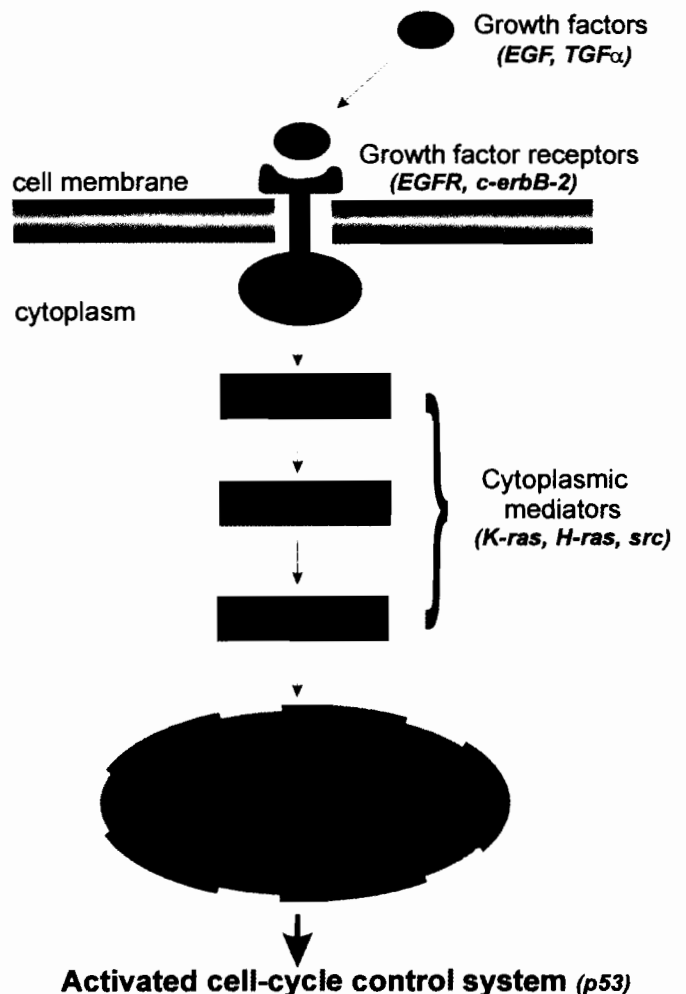


Fig. 3. Signal transduction from the cell membrane to the nucleus.

pathways involved in the growth and differentiation of normal tissues. Considerable evidence suggests a role of these proteins in the neoplastic progression within various organ systems including the gastrointestinal tract (Banker et al., 1996). The *src*-specific activity was found to be 3-4 fold higher in BE and 6-fold higher in esophageal adenocarcinoma than in control tissues. It was suggested that *src* activation occurs prior to the development of dysplasia or carcinoma in BE (Kumble et al., 1997). Three out of 15 (20%) esophageal adenocarcinomas were found to be *c-src*-positive (Jankowski et al., 1992a).

Unlike most oncogenes which increase the rate of cellular proliferation, the *bcl-2* protein decreases the rate of (programmed) cell death by preventing apoptosis. If the *bcl-2* gene is overexpressed together with oncogenes, which induce proliferation, the excess progeny cells will survive because secondary apoptosis is now prevented. Balance between *bcl-2* and *bax-1* determines apoptotic activity, and normally this balance is in favor of *bax-1*. By upregulation of *bax-1*, p53 pushes the cell into the apoptotic pathway (Fig. 1). The *bcl-2* protein has been found abnormally overexpressed as an early event in the dysplasia-carcinoma sequence of gastric cancer. However, in 36 esophageal resection specimens containing BE mucosa, *bcl-2* immunoreactivity was not seen in any of the cases with or without dysplasia or carcinoma (Goldblum and Rice, 1995). In contrast to this report, *bcl-2* overexpression resulting in inhibition of apoptosis was found predominantly early in the dysplasia-carcinoma sequence of BE (Katada et al., 1997). Positive *bcl-2* staining was seen in 72% of lesions with metaplasia, 100% with low-grade dysplasia, 25% with high-grade dysplasia, 40% with well- or moderately differentiated adenocarcinoma, and 20% with poorly differentiated adenocarcinoma. These authors suggested that the prolongation of cell survival promotes neoplastic progression, and that cells acquire other ways of avoiding apoptosis as malignancy appears. Mismatch repair defects may also induce mutations in *bax-1*, thereby avoiding apoptosis (Yamamoto et al., 1997).

Cell adhesion molecules

Cadherins are a family of transmembranous glycoproteins responsible for calcium-dependent intercellular adhesion. E-cadherin has been considered a key factor in the intercellular physical adhesion of cancer cells (Shiozaki et al., 1991). The cytoplasmic domain of E-cadherin forms complexes with α -, β -, and γ -catenin/plakoglobin, which are essential for the adhesive function by connecting cadherin to other integral membrane proteins, such as Na^+/K^+ -ATPase (Takayama et al., 1996). There is a significant correlation between reduced expression of E-cadherin and loss of tumor differentiation (Shiozaki et al., 1996). Loss of or reduced E-cadherin expression may play a role in the progression of Barrett metaplasia to adenocarcinoma (Swami et al., 1995). E-cadherin

function is downregulated through the tyrosine phosphorylation of β -catenin induced by growth factors (EGFR) or oncoproteins (*c-erbB-2*). Reduced expression of E-cadherin was found in 86% of esophageal adenocarcinomas, in correlation with stage of disease (Bongiorno et al., 1995). Reduced β -catenin expression was observed in 72% of these cancers and this was adversely correlated with survival, independent of stage (Krishnadath et al., 1997).

The CD44 protein family has been implicated in lymphocyte homing, cell-extracellular matrix interactions, tumor invasiveness, and dissemination (Lesley et al., 1993). This cell surface glycoprotein is expressed as multiple isoforms in many normal and neoplastic tissues (Sy et al., 1997). CD44 and its abnormal transcripts have been described in both squamous and glandular type of esophageal carcinoma. It has been suggested that especially CD44v3 may play a role in the development of esophageal carcinoma of both squamous and glandular types (Castella et al., 1996).

Diagnostic dilemmas associated with dysplasia in Barrett esophagus

Unlike various research tools (e.g. p53 and aneuploidy), dysplasia in BE is presently the only clinically accepted marker of neoplastic potential. In the course of time, patients with dysplasia progress to carcinoma (Miros et al., 1991). Therefore, patients with Barrett metaplasia are offered endoscopic surveillance (Provenzale et al., 1994). When a diagnosis of low-grade dysplasia is made, the surveillance should be intensified by shortening the time intervals between consecutive endoscopies and by applying more aggressive biopsy sampling (Tytgat and Hameeteman, 1992; Tytgat, 1995). It has been generally accepted that high-grade dysplasia indicates occult presence of or imminent progression into invasive carcinoma (Altorki et al., 1991; Pera et al., 1992; Rice et al., 1993; Rusch et al., 1994; Edwards et al., 1996; Heitmiller et al., 1996). When the diagnosis of persistent high-grade dysplasia is confirmed by two independent GI pathology experts in a patient fit for major surgery, a so-called 'prophylactic' esophagectomy should be undertaken in an institution with low postoperative mortality. However, the effectiveness of such therapeutic strategy is hampered by substantial diagnostic variability in grading dysplasia (Reid et al., 1988; Sagan et al., 1994).

Dysplasia is usually defined as a process of unequivocal neoplastic proliferation, with loss of differentiation and/or maturation gradient (Riddell et al., 1983; Hermanek, 1987). The diagnosis of high-grade dysplasia or intramucosal carcinoma can be made with a high inter-observer reproducibility between expert pathologists (85-87%), especially if they come from the same institution (Sagan et al., 1994). However, diagnostic variability creates a difficult problem in lower grades of dysplasia (Reid et al., 1988). It can be difficult to distinguish reactive inflammatory changes from

Barrett esophagus and cancer

genuine dysplasia. This can be partially overcome by microscopic re-assessment after short-term anti-reflux medical therapy. However, we do not deal with distinct categories, but with a continuous spectrum from metaplasia, through low-, (intermediate-), and high-grade dysplasia to invasive carcinoma. Because of lack of definitive histological criteria and their loose interpretation, both intra- and inter-observer variability are inherent to this scoring system.

With all shortcomings of the 'gold standard' (i.e. subjective grading of dysplasia on H&E-stained sections) in mind, some new possibilities have become available recently. Dysplasia, by definition, represents loss of a differentiation/maturation gradient. Mucin histochemistry (like alcian blue pH 2.5/PAS) allows for demonstration of maturation loss in BE (Lapertosa et al., 1992). Moreover, features of differentiation and/or maturation can be objectively evaluated by means of morphometry. Morphometry enables the measurement of geometric features of tissue components, like stratification of nuclei within the epithelium and nuclear size-related features (nuclear area and nuclear volume) (Baak et al., 1991). It has been shown that, using

morphometry, incomplete intestinal metaplasia of the gastric mucosa should be classified as, and is comparable to low-grade dysplasia (Tosi et al., 1993). If the same holds true for BE, then morphometry might also be useful as an additional diagnostic tool for grading dysplasia.

Another feature of dysplasia is increased proliferation. This can be assessed by counting the mitotic figures on H&E sections, or by using special stains which enable the demonstration of cells that have entered the cell cycle (Nucleolar Organizer Regions Antigen - AgNORs; Proliferating Cell Nuclear Antigen - PCNA; Ki67; MIB1). Flow cytometry for this purpose is discouraged because of the loss of histological context (Fennerty et al., 1989). With the use of proliferative markers it is possible to localize rapidly dividing cells within dysplastic epithelium. In BE epithelium, the proliferative compartment is normally restricted to the bottom of the crypts (progenitor stem cells) (Eastwood, 1995). An expansion of this zone (i.e. an upward shift of proliferating cells towards the luminal surface) is a characteristic feature of premalignant mucosa of the gastrointestinal tract (Wesdorp et al., 1981). The

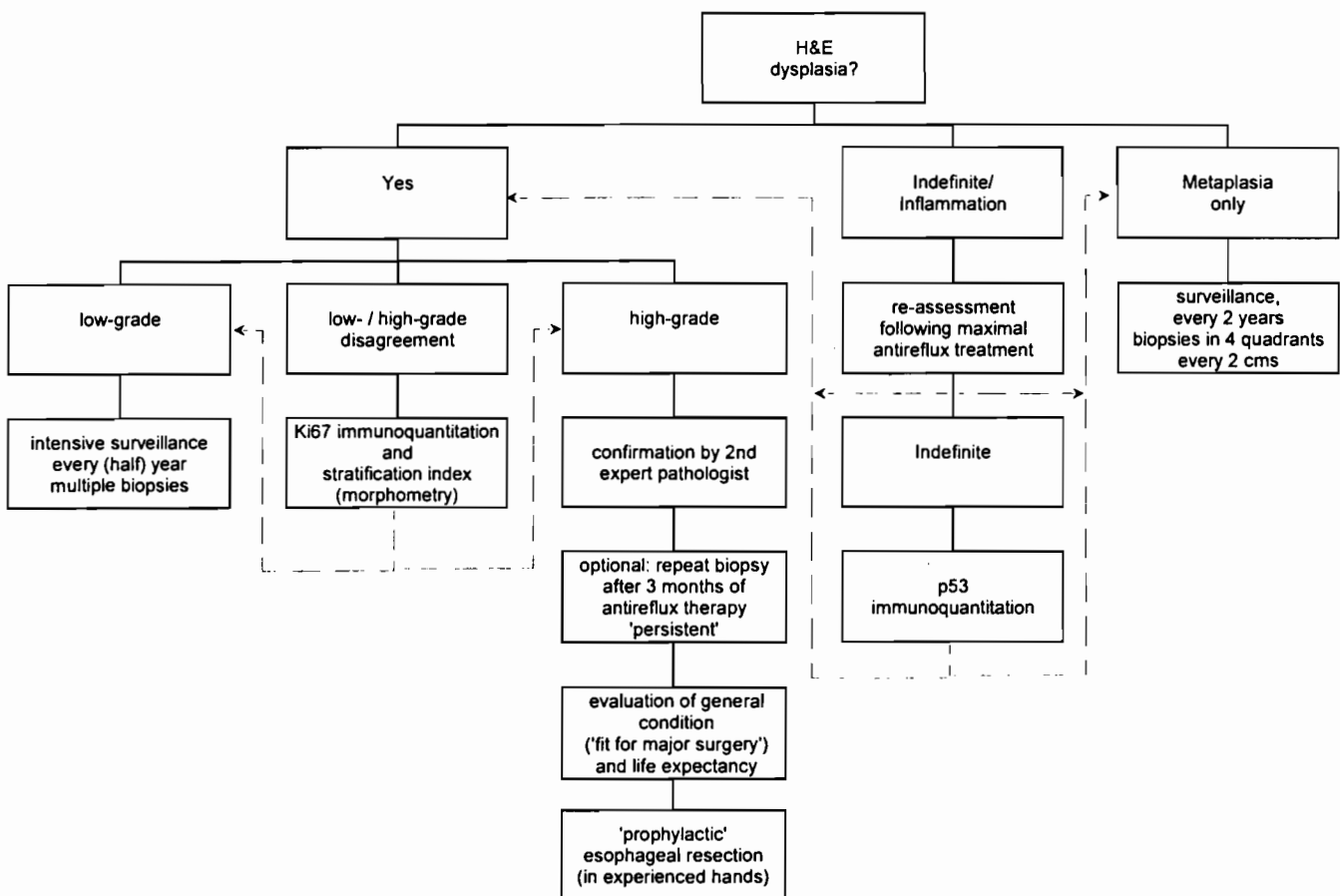


Fig. 4. Potential application of additional diagnostic tools for grading of dysplasia in patients with Barrett esophagus.

assessment of proliferative activity has also been well documented in the dysplasia-carcinoma sequence of BE (Iftikhar et al., 1992; Jankowski et al., 1992a,b; Reid et al., 1993; Gillen et al., 1994; Hong et al., 1995; Yacoub et al., 1997). The most widely accepted proliferative parameter is the labelling index, defined as the proportion of positively labelled cells to the total number of cells (within the proliferative compartment). However, the assessment of the labelling index is based on counting a large number of cells under the microscope. This procedure needs standardized training in scoring and its reproducibility is limited (Roe et al., 1996). This might explain discrepancies in the average values of the labelling index reported in the literature. Therefore, a (time-) effective and reproducible method for the assessment of the proliferative activity is needed. Using computerized immunoquantitation of Ki67 by stereology with systematic random sampling, it has been shown that area percentage of positive nuclei is an attractive alternative to labelling index (Polkowski et al., 1997).

Proliferation is partly controlled by tumor suppressor genes (e.g. p53). Alterations of the p53 gene are frequently found in esophageal adenocarcinoma arising in BE. Therefore, in these tumors a positive correlation between p53 protein dysfunction and increased proliferative activity (as assessed with Ki67) can be expected. In addition, the use of a proliferative marker like Ki67 in combination with the assessment of the p53 protein status might be of help to discriminate between different grades of dysplasia in BE. This combination may be of special interest, since Ki67 assessment may to some extent have an additional value to p53 IHC. There is now increasing evidence that p53 IHC can give false positive results, and therefore it is not the optimal way to assess the p53 gene status (Baas et al., 1996; Soong et al., 1996). Moreover, although the p53-dependent pathway is common, it is certainly not the only pathway giving rise to esophageal adenocarcinoma. Consequently, high indices of proliferation in combination with p53-IHC-negativity may underline the need for additional investigation of the p53 gene (LOH of 17p, DNA sequencing), but also of other genetic pathways (activation of oncogenes).

Given the potential inaccuracy of p53 IHC, should we abandon this technique from the routine pathological practice? Several aspects of this dilemma have recently been addressed in a series of *Editorials*, and it has been suggested that "the number of positive cells may be more meaningful than positivity *per se*" (Wynford-Thomas, 1992; Hall and Lane, 1994). This brings up the important issue as to whether objective quantitative analysis of p53 IHC (measurement of molecular cell features = cytometry) could possibly be an adjunct to the conventional grading of dysplasia in BE. When the pathologist is not sure about the presence of dysplasia (often due to inflammatory and/or reactive changes), the diagnosis of 'indefinite for dysplasia' is made. There is evidence that p53 immunoquantitation might be of help

to distinguish between this category and 'genuine' dysplastic areas (Polkowski et al., 1995).

Morphometry allows for measuring geometric characteristics of tissue components that constitute the morphological picture of dysplasia (Baak et al., 1991). Computerized quantitation of features associated with differentiation (stratification, nuclear size-related features) and proliferation (mitotic activity, Ki67), as well as p53 immunoquantitation (cytometry of a 'key gene' product in BE) can be assessed with various combinations to obtain objective diagnostic information. The potential of such features to discriminate between different grades of dysplasia could be used for the future refinement of histological criteria in grading dysplasia. Since grading of dysplasia in BE carries important clinical consequences for the individual patient (intensification of endoscopic surveillance, 'prophylactic esophagectomy'), this would obviously be of value. It has been shown that assessment of Ki67 area % and stratification index are the most powerful parameters for discrimination between different grades of dysplasia in BE (Polkowski et al., 1998). An algorithm for the potential application of quantitative pathology in grading of dysplasia in patients with BE is proposed in Fig. 4. Before this algorithm can be applied, the reproducibility and accuracy of the computerized quantitative pathological methods should be assessed on endoscopic biopsy material. Finally, the clinical value of this algorithm should be tested in a prospective clinical study with long term follow-up.

References

- Abdelatif O.M.A., Chandler F.W., Mills L.R., McGuire B.S., Pantazis C.G. and Barrett J.M. (1991). Differential expression of c-myc and H-ras oncogenes in Barrett's epithelium. *Arch. Pathol. Lab. Med.* 115, 880-885.
- al-Kasspooles M., Moore J.H., Orringer M.B. and Beer D.G. (1993). Amplification and over-expression of the EGFR and erbB-2 genes in human esophageal adenocarcinomas. *Int. J. Cancer* 54, 213-219.
- Alberts B., Bray D., Lewis J., Raff M., Roberts K. and Watson J.D. (1995). *Molecular biology of the cell*. 3rd edn. Garland Publishing, New York & London.
- Allison P.R. (1948). Peptic ulcer of esophagus. *Thorax* 3, 20-42.
- Allison P.R. and Johnstone A.S. (1953). The esophagus lined with gastric mucous membrane. *Thorax* 8, 87-101.
- Altorki N.K., Sunagawa M., Little A.G. and Skinner D.B. (1991). High-grade dysplasia in the columnar-lined esophagus. *Am. J. Surg.* 161, 97-99.
- Ames B.N. and Gold L.S. (1990). Too many rodent carcinogens: mitogenesis increases mutagenesis. *Science* 249, 970-971.
- Arber N., Lightdale C., Rotterdam H., Han K.H., Sgambato K., Yap E., Ahsan H., Finegold J., Stevens P.D., Green P.H., Hibshoosh H., Neugut A.I., Holt P.R. and Weinstein I.B. (1996). Increased expression of the cyclin D1 gene in Barrett's esophagus. *Cancer Epidemiol. Biomarkers Prev.* 5, 457-459.
- Attwood S.E., Ball C.S., Barlow A.P., Jenkinson L., Norris T.L. and Watson A. (1993). Role of intragastric and intraoesophageal alkalinisation in the genesis of complications in Barrett's columnar

Barrett esophagus and cancer

- lined lower oesophagus. *Gut* 34, 11-15.
- Baak J.P.A., Oort J., Fleege J.C., van Diest P.J. and Ploem J.S. (1991). Techniques in quantitative pathology. In: Manual of quantitative pathology in cancer diagnosis and prognosis. Baak J.P.A. (ed). Springer-Verlag, Berlin. pp 45-56.
- Baas I.O., van den Berg F.M., Mulder J.W., Clement M.J., Slebos R.J., Hamilton S.R. and Offerhaus G.J. (1996). Potential false-positive results with antigen enhancement for immunohistochemistry of the p53 gene product in colorectal neoplasms. *J. Pathol.* 178, 264-267.
- Banker N., Evers B.M., Hellmich M.R. and Townsend C.M. Jr. (1996). The role of Src family kinases in the normal and neoplastic gastrointestinal tract. *Surg. Oncol.* 5, 201-210.
- Barrett M.T., Galipeau P.C., Sanchez C.A., Emond M.J. and Reid B.J. (1996a). Determination of the frequency of loss of heterozygosity in esophageal adenocarcinoma by cell sorting, whole genome amplification and microsatellite polymorphisms. *Oncogene* 12, 1873-1878.
- Barrett M.T., Sanchez C.A., Galipeau P.C., Neshat K., Emond M. and Reid B.J. (1996b). Allelic loss of 9p21 and mutation of the CDKN2/p16 gene develop as early lesions during neoplastic progression in Barrett's esophagus. *Oncogene* 13, 1867-1873.
- Barrett M.T., Schutte M., Kern S.E. and Reid B.J. (1996c). Allelic loss and mutational analysis of the DPC4 gene in esophageal adenocarcinoma. *Cancer Res.* 56, 4351-4353.
- Barrett N.R. (1950). Chronic peptic ulcer of the oesophagus and "oesophagitis". *Br. J. Surg.* 38, 175-182.
- Bartkova J., Lukas J., Strauss M. and Bartek J. (1995). Cyclin D1 oncoprotein aberrantly accumulates in malignancies of diverse histogenesis. *Oncogene* 10, 775-778.
- Birgisson S., Rice T.W., Easley K.A. and Richter J.E. (1997). The lack of association between adenocarcinoma of the esophagus and gastric surgery: a retrospective study. *Am. J. Gastroenterol.* 92, 216-221.
- Blot W.J., Devesa S.S., Kneller R.W. and Fraumeni J.F. Jr. (1991). Rising incidence of adenocarcinoma of the esophagus and gastric cardia. *JAMA* 265, 1287-1289.
- Blot W.J., Devesa S.S. and Fraumeni J.F. Jr. (1993). Continuing climb in rates of esophageal adenocarcinoma: an update. *JAMA* 270, 1320
- Blount P.L., Ramel S., Raskind W.H., Haggitt R.C., Sanchez C.A., Dean P.J., Rabinovitch P.S. and Reid B.J. (1991). 17p allelic deletions and p53 protein overexpression in Barrett's adeno-carcinoma. *Cancer Res.* 51, 5482-5486.
- Blount P.L., Meltzer S.J., Yin J., Huang Y., Krasna M.J. and Reid B.J. (1993). Clonal ordering of 17p and 5q allelic losses in Barrett dysplasia and adenocarcinoma. *Proc. Natl. Acad. Sci. USA* 90, 3221-3225.
- Blount P.L., Galipeau P.C., Sanchez C.A., Neshat K., Levine D.S., Yin J., Suzuki H., Abraham J.M., Meltzer S.J. and Reid B.J. (1994). 17p allelic losses in diploid cells of patients with Barrett's esophagus who develop aneuploidy. *Cancer Res.* 54, 2292-2295.
- Boch J.A., Shields H.M., Antonioli D.A., Zwas F., Sawhney R.A. and Trier J.S. (1997). Distribution of cytokeratin markers in Barrett's specialized columnar epithelium. *Gastroenterology* 112, 760-765.
- Bongiorno P.F., al-Kasspooles M., Lee S.W., Rachwal W.J., Moore J.H., Whyte R.I., Orringer M.B. and Beer D.G. (1995). E-cadherin expression in primary and metastatic thoracic neoplasms and in Barrett's oesophagus. *Br. J. Cancer* 71, 166-172.
- Borhan-Manesh F. and Farnum J.B. (1991). Incidence of heterotopic gastric mucosa in the upper oesophagus. *Gut* 32, 968-972.
- Brattain M.G., Markowitz S.D. and Willson J.K.V. (1996). The type II transforming growth factor- β receptor as a tumor-suppressor gene. *Curr. Opin. Oncol.* 8, 49-53.
- Cahill D.P., Lengauer C., Yu J., Riggins G.J., Willson J.K.V., Markowitz S.D., Kinzler K.W. and Vogelstein B. (1998). Mutations of mitotic checkpoint genes in human cancers. *Nature* 392, 300-303.
- Cameron A.J. (1993). Epidemiologic studies and the development of Barrett's esophagus. *Endoscopy* 25, 635-636.
- Cameron A.J. and Lomboy C.T. (1992). Barrett's esophagus: age, prevalence, and extent of columnar epithelium. *Gastroenterology* 103, 1241-1245.
- Cameron A.J., Zinsmeister A.R., Ballard D.J. and Carney J.A. (1990). Prevalence of columnar-lined (Barrett's) esophagus. Comparison of population-based clinical and autopsy findings. *Gastroenterology* 99, 918-922.
- Carriere F., Barrowman J.A., Verger R. and Laugier R. (1993). Secretion and contribution to lipolysis of gastric and pancreatic lipases during a test meal in humans. *Gastroenterology* 105, 876-888.
- Casson A.G., Manolopoulos B., Troster M., Kerkvliet N., O'Malley F., Inculiet R., Finley R. and Roth J.A. (1994). Clinical implications of p53 gene mutation in the progression of Barrett's epithelium to invasive esophageal cancer. *Am. J. Surg.* 167, 52-57.
- Castella E., Ariza A., Fernandez-Vasalo A., Roca X. and Ojanguren I. (1996). Expression of CD44H and CD44v3 in normal oesophagus, Barrett mucosa and oesophageal carcinoma. *J. Clin. Pathol.* 49, 489-492.
- Chalasanani N., Wo J.M., Hunter J.G. and Waring J.P. (1997). Significance of intestinal metaplasia in different areas of esophagus including esophagogastric junction. *Dig. Dis. Sci.* 42, 603-607.
- Chung D.C. and Rustgi A.K. (1995). DNA mismatch repair and cancer. *Gastroenterology* 109, 1685-1699.
- Chung Y., Song J., Lee J., Jung Y., Seo E., Choi S. and Rhyu M. (1996). Microsatellite instability-associated mutations associate preferentially with the intestinal type of primary gastric carcinomas in a high-risk population. *Cancer Res.* 56, 4662-4665.
- Clark G.W., Ireland A.P., Chandrasoma P., DeMeester T.R., Peters J.H. and Bremner C.G. (1994). Inflammation and metaplasia in the transitional mucosa of the epithelium of the gastroesophageal reflux junction: a new marker for gastroesophageal reflux disease. *Gastroenterology* 106, A63 (Abstract).
- Csendes A., Smok G., Cerda G., Burdiles P., Mazza D. and Csendes P. (1997). Prevalence of *Helicobacter pylori* infection in 190 control subjects and in 236 patients with gastroesophageal reflux, erosive esophagitis or Barrett's esophagus. *Dis. Esophagus* 10, 38-42.
- Dahms B.B. and Rothstein F.C. (1984). Barretts esophagus in children: a consequence of chronic gastroesophageal reflux. *Gastroenterology* 86, 318-323.
- Dijkhorst-Oei L.T., Rabelink T.J., Boer P. and Koomans H.A. (1997). Nifedipine attenuates systemic and renal vasoconstriction during nitric oxide inhibition in humans. *Hypertension* 29, 1192-1198.
- Doglioni C., Laurino L., Dei Tos A.P., De Boni M., Franzin G., Braidotti P. and Viale G. (1993). Pancreatic (acinar) metaplasia of the gastric mucosa. Histology, ultrastructure, immunocytochemistry, and clinicopathologic correlations of 101 cases. *Am. J. Surg. Pathol.* 17, 1134-1143.
- Duhaylongsod F.G., Gottfried M.R., Iglehart J.D., Vaughn A.L. and Wolfe W.G. (1995). The significance of c-erbB-2 and p53 immunoreactivity in patients with adenocarcinoma of the esophagus.

Barrett esophagus and cancer

- Ann. Surg. 221, 677-683.
- Eastwood G.L. (1995). A review of gastrointestinal epithelial renewal and its relevance to the development of adenocarcinomas of the gastrointestinal tract. *J. Clin. Gastroenterol.* 21 Suppl 1, S1-11.
- Edelmann W., Yang K., Umar A., Heyer J., Lau K., Fan K., Liedtke W., Cohen P.E., Kane M.F., Lipford J.R., Yu N., Crouse G.F., Pollard J.W., Kunkel T., Lipkin M., Kolodner R. and Kucherlapati R. (1997). Mutation in the mismatch repair gene MSH6 causes cancer susceptibility. *Cell* 91, 467-477.
- Edwards M.J., Gable D.R., Lentsch A.B. and Richardson J.D. (1996). The rationale for esophagectomy as the optimal therapy for Barrett's esophagus with high-grade dysplasia. *Ann. Surg.* 223, 585-589.
- Esteve A., Lehman T., Jiang W., Weinstein I.B., Harris C.C., Ruol A., Peracchia A., Montesano R. and Hollstein M. (1993). Correlation with p53 mutations with epidermal growth factor receptor overexpression and absence of mdm2 amplification in human esophageal carcinomas. *Mol. Carcinog.* 8, 306-311.
- Esteve A., Martel-Planche G., Sylla B.S., Hollstein M., Hainaut P. and Montesano R. (1996). Low frequency of p16/CDKN2 gene mutations in esophageal carcinomas. *Int. J. Cancer* 66, 301-304.
- Fennerty M.B., Sampliner R.E., Way D., Riddell R., Steinbronn K.X. and Garewal H.S. (1989). Discordance between flow cytometric abnormalities and dysplasia in Barrett's esophagus. *Gastroenterology* 97, 815-820.
- Filipe M.I. (1989). Histochemistry of intestinal mucins. Changes in disease. In: *Gastrointestinal and oesophageal pathology*. Whitehead R. (ed). Churchill Livingstone. Edinburgh, pp 65-89
- Flejou J.F., Potet F., Muzeau F., Le Pelletier F., Fekete F. and Henin D. (1993). Overexpression of p53 protein in Barrett's syndrome with malignant transformation. *J. Clin. Pathol.* 46, 330-333.
- Flejou J.F., Paraf F., Muzeau F., Fekete F., Henin D., Jothy S. and Potet F. (1994). Expression of c-erbB-2 oncogene product in Barrett's adenocarcinoma: pathological and prognostic correlations. *J. Clin. Pathol.* 47, 23-26.
- Galiana C., Lozano J.C., Bancel B., Nakazawa H. and Yamasaki H. (1995). High frequency of Ki-ras amplification and p53 gene mutations in adenocarcinomas of the human esophagus. *Mol. Carcinog.* 14, 286-293.
- Galipeau P.C., Cowan D.S., Sanchez C.A., Barrett M.T., Emond M.J., Levine D.S., Rabinovitch P.S. and Reid B.J. (1996). 17p (p53) allelic losses, 4N (G2/tetraploid) populations, and progression to aneuploidy in Barrett's esophagus. *Proc. Natl. Acad. Sci. USA* 93, 7081-7084.
- Garrigue-Antar L., Souza R.F., Vellucci V.F., Meltzer S.J. and Reiss M. (1996). Loss of transforming growth factor- β type II receptor gene expression in primary human esophageal cancer. *Lab. Invest.* 75, 263-272.
- Gillen P., McDermott M., Grehan D., Hourihane D.O. and Hennessy T.P. (1994). Proliferating cell nuclear antigen in the assessment of Barrett's mucosa. *Br. J. Surg.* 81, 1766-1768.
- Gillen P., Keeling P., Byrne P.J., West A.B. and Hennessy T.P. (1988). Experimental columnar metaplasia in the canine oesophagus. *Br. J. Surg.* 75, 113-115.
- Gleeson C.M., Sloan J.M., McGuigan J.A., Ritchie A.J., Weber J.L. and Russell S.E. (1996). Ubiquitous somatic alterations at microsatellite alleles occur infrequently in Barrett's-associated esophageal adenocarcinoma. *Cancer Res.* 56, 259-263.
- Goldblum J.R. and Rice T.W. (1995). bcl-2 protein expression in the Barrett's metaplasia-dysplasia-carcinoma sequence. *Mod. Pathol.* 8, 866-869.
- González M.V., Artinez M.L., Rodrigo L., López-Larrea C., Menéndez M.J., Alvarez V., Pérez R., Fresno M.F., Pérez M.J., Sampedro A. and Coto E. (1997). Mutation analysis of the p53, APC, and p16 genes in the Barrett's oesophagus, dysplasia, and adenocarcinoma. *J. Clin. Pathol.* 50, 212-217.
- Gotley D.C., Appleton G.V. and Cooper M.J. (1992). Bile acids and trypsin are unimportant in alkaline esophageal reflux. *J. Clin. Gastroenterol.* 14, 2-7.
- Haggitt R.C. (1994). Barrett's esophagus, dysplasia, and adenocarcinoma. *Hum. Pathol.* 25, 982-993.
- Hahn S.A., Schutte M., Hoque A.T., Moskaluk C.A., da Costa L.T., Rozenblum E., Weinstein C.L., Fischer A., Yeo C.J., Hruban R.H. and Kern S.E. (1996). DPC4, a candidate tumor suppressor gene at human chromosome 18q21.1. *Science* 271, 350-353.
- Hall P.A. and Lane D.P. (1994). p53 in tumour pathology: can we trust immunohistochemistry?—Revisited! *J. Pathol.* 172, 1-4.
- Hamelin R., Flejou J.F., Muzeau F., Potet F., Laurent-Puig P., Fekete F. and Thomas G. (1994). TP53 gene mutations and p53 protein immunoreactivity in malignant and premalignant Barrett's esophagus. *Gastroenterology* 107, 1012-1018.
- Hamilton S.R. (1990). Reflux esophagitis and Barrett esophagus. In: *Gastrointestinal pathology*. Goldman H., Appelman H.D. and Kaufman N. (eds). Williams & Wilkins. Baltimore, pp 11-68.
- Hamilton S.R., Smith R.L.L. and Cameron J.L. (1988). Prevalence and characteristics of Barrett's esophagus in patients with adenocarcinoma of the esophagus or esophagogastric junction. *Hum. Pathol.* 19, 942-948.
- Hardwick R.H., Shepherd N.A., Moorghen M., Newcomb P.V. and Alderson D. (1994). Adenocarcinoma arising in Barrett's esophagus: evidence for the participation of p53 dysfunction in the dysplasia/carcinoma sequence. *Gut* 35, 764-768.
- Hardwick R.H., Shepherd N.A., Moorghen M., Newcomb P.V. and Alderson D. (1995). c-erbB-2 overexpression in the dysplasia/carcinoma sequence of Barrett's oesophagus. *J. Clin. Pathol.* 48, 129-132.
- Hardwick R.H., Barham C.P., Ozua P., Newcomb P.V., Savage P., Powell R., Rahamin J. and Alderson D. (1997). Immunohistochemical detection of p53 and c-erbB-2 in oesophageal carcinoma; no correlation with prognosis. *Eur. J. Surg. Oncol.* 23, 30-35.
- Hassall E. (1993). Barrett's esophagus: new definitions and approaches in children. *J. Pediatr. Gastroenterol. Nutr.* 16, 345-364.
- Heitmiller R.F., Redmond M. and Hamilton S.R. (1996). Barrett's esophagus with high-grade dysplasia. An indication for prophylactic esophagectomy. *Ann. Surg.* 224, 66-71.
- Hermanek P. (1987). Dysplasia in the gastrointestinal tract: definition and clinical significance. *Surg. Endosc.* 1, 5-10.
- Hesketh P.J., Clapp R.W., Doos W.G. and Spechler S.J. (1989). The increasing frequency of adenocarcinoma of the esophagus. *Cancer* 64, 526-530.
- Hong M.K., Laskin W.B., Herman B.E., Johnston M.H., Vargo J.J., Steinberg S.M., Allegra C.J. and Johnston P.G. (1995). Expansion of the Ki-67 proliferative compartment correlates with degree of dysplasia in Barrett's esophagus. *Cancer* 75, 423-429.
- Huang Y., Boynton R.F., Blount P.L., Silverstein R.J., Yin J., Tong Y., McDaniel T.K., Newkirk C., Resau J.H. and Sridhara R. (1992). Loss of heterozygosity involves multiple tumor suppressor genes in human esophageal cancers. *Cancer Res.* 52, 6525-6530.
- Huang Y., Meltzer S.J., Yin J., Tong Y., Chang E.H., Srivastava S.,

Barrett esophagus and cancer

- McDaniel T., Boynton R.F. and Zou Z.Q. (1993). Altered messenger RNA and unique mutational profiles of p53 and Rb in human esophageal carcinomas. *Cancer Res.* 53, 1889-1894.
- Iftikhar S.Y., Steele R.J., Watson S., James P.D., Dilks K. and Hardcastle J.D. (1992). Assessment of proliferation of squamous, Barrett's and gastric mucosa in patients with columnar lined Barrett's oesophagus. *Gut* 33, 733-737.
- Igaki H., Sasaki H., Tachimori Y., Kato H., Watanabe H., Kimura T., Harada Y., Sugimura T. and Terada M. (1995). Mutation frequency of the p16/CDKN2 gene in primary cancers in the upper digestive tract. *Cancer Res* 55, 3421-3423.
- Ireland A.P., Peters J.H., Smyrk T.C., DeMeester T.R., Clark G.W., Mirvish S.S. and Adrian T.E. (1996). Gastric juice protects against the development of esophageal adenocarcinoma in rat. *Ann. Surg.* 224, 358-371.
- Ireland A.P., Clark G.W. and DeMeester T.R. (1997). Barrett's esophagus. The significance of p53 in clinical practice. *Ann. Surg.* 225, 17-30.
- Jankowski J. (1993). Gene expression in Barrett's mucosa: acute and chronic adaptive responses in the oesophagus. *Gut* 34, 1649-1650.
- Jankowski J., McMenemin R., Hopwood D., Penston J. and Wormsley K.G. (1991). Abnormal expression of growth regulatory factors in Barrett's oesophagus. *Clin. Sci. (Colch)*. 81, 663-668.
- Jankowski J., Coghil G., Hopwood D. and Wormsley K.G. (1992a). Oncogenes and onco-suppressor gene in adenocarcinoma of the oesophagus. *Gut* 33, 1033-1038.
- Jankowski J., McMenemin R., Yu C., Hopwood D. and Wormsley K.G. (1992b). Proliferating cell nuclear antigen in oesophageal diseases; correlation with transforming growth factor alpha expression. *Gut* 33, 587-591.
- Jiang W., Zhang Y.J., Kahn S.M., Hollstein M.C., Santella R.M., Lu S.H., Harris C.C., Montesano R. and Weinstein I.B. (1993). Altered expression of the cyclin D1 and retinoblastoma genes in human esophageal cancer. *Proc. Natl. Acad. Sci. USA* 90, 9026-9030.
- Johns B.A.E. (1952). Developmental changes in the esophageal epithelium in man. *J. Anat.* 86, 431-439.
- Johnston M.H., Hammond A.S., Laskin W. and Jones D.M. (1996). The prevalence and clinical characteristics of short segments of specialized intestinal metaplasia in the distal esophagus on routine endoscopy. *Am. J. Gastroenterol.* 91, 1507-1511.
- Jones D.R., Davidson A.G., Summers C.L., Murray G.F. and Quinlan D.C. (1994). Potential application of p53 as an intermediate biomarker in Barrett's esophagus. *Ann. Thorac. Surg.* 57, 598-603.
- Katada N., Hinder R.A., Smyrk T.C., Hirabayashi N., Perdakis G., Lund R.J., Woodward T. and Klingler P.J. (1997). Apoptosis is inhibited early in the dysplasia-carcinoma sequence of Barrett esophagus. *Arch. Surg.* 132, 728-733.
- Kauer W.K., Peters J.H., DeMeester T.R., Ireland A.P., Bremner C.G. and Hagen J.A. (1995). Mixed reflux of gastric and duodenal juices is more harmful to the esophagus than gastric juice alone. The need for surgical therapy re-emphasized. *Ann. Surg.* 222, 525-531.
- Keller G., Rotter M., Vogelsang H., Bischoff P., Becker K.F., Mueller J., Brauch H., Siewert J.R. and Hofler H. (1995). Microsatellite instability in adenocarcinomas of the upper gastrointestinal tract. Relation to clinicopathological data and family history. *Am. J. Pathol.* 147, 593-600.
- Komorowski R.A., Hogan W.J. and Chausow D.D. (1996). Barrett's ulcer: the clinical significance today. *Am. J. Gastroenterol.* 91, 2310-2313.
- Krishnadath K.K., Tilanus H.W., van Blankenstein M., Bosman F.T. and Mulder A.H. (1995). Accumulation of p53 protein in normal, dysplastic, and neoplastic Barrett's oesophagus. *J. Pathol.* 175, 175-180.
- Krishnadath K.K., Tilanus H.W., van Blankenstein M., Hop W.C.J., Kremers E.D., Dinjens W.N.M. and Bosman F.T. (1997). Reduced expression of the cadherin-catenin complex in oesophageal adenocarcinoma correlates with poor prognosis. *J. Pathol.* 182, 331-338.
- Krishnamurthy S. and Dayal Y. (1995). Pancreatic metaplasia in Barrett's esophagus. An immunohistochemical study. *Am. J. Surg. Pathol.* 19, 1172-1180.
- Kumble S., Omary M.B., Cartwright C.A. and Triadafilopoulos G. (1997). Src activation in malignant and premalignant epithelia of Barrett's esophagus. *Gastroenterology* 112, 348-356.
- Lagorce C., Flejou J.F., Muzeau F., Henin D. and Potet F. (1995). Absence of c-Ki-ras gene mutation in malignant and premalignant Barrett's oesophagus. *J. Clin. Pathol. Mol. Pathol.* 48, M198-M199.
- Lapertosa G., Baracchini P. and Fulcheri E. (1992). Mucin histochemical analysis in the interpretation of Barrett's esophagus. Results of a multicenter study. The operative group for the study of esophageal precancer. *Am. J. Clin. Pathol.* 98, 61-66.
- Lesley J., Hyman R. and Kincade P.W. (1993). CD44 and its interaction with extracellular matrix. *Adv. Immunol.* 54, 271-335.
- Li H., Walsh T.N., O'Dowd G., Gillen P., Byrne P.J. and Hennessy T.P. (1994). Mechanisms of columnar metaplasia and squamous regeneration in experimental Barrett's esophagus. *Surgery* 115, 176-181.
- Liron R., Parrilla P., Martinez de Haro L.F., Ortiz A., Robles R., Lujan J.A., Fuente T. and Andres B. (1997). Quantification of duodeno-gastric reflux in Barrett's esophagus. *Am. J. Gastroenterol.* 92, 32-36.
- Loeb L.A. (1994). Microsatellite instability: marker of a mutator phenotype in cancer. *Cancer Res.* 54, 5059-5063.
- Loewenstein W.R. (1981). Junctional intercellular communication: the cell-to-cell membrane channel. *Physiol. Rev.* 61, 829-913.
- Loffeld R.J., Ten Tije B.J. and Arends J.W. (1992). Prevalence and significance of *Helicobacter pylori* in patients with Barrett's esophagus. *Am. J. Gastroenterol.* 87, 1598-1600.
- Lyall A. (1937). Chronic peptic ulcer of the esophagus: a report of eight cases. *Br. J. Surg.* 24, 534-547.
- Macdonald C.E., Wicks A.C. and Playford R.J. (1997). Barrett's oesophagus in a university teaching hospital. *Gut* 41, 303-307.
- Markowitz S., Wang J., Myeroff M., Parsons R., Sun L., Lutterbaugh J., Fan R.S., Zborowski E., Kinzler K.W., Vogelstein B., Brattain M. and Willson J.K.V. (1995). Inactivation of the type II TGF- β receptor in colon cancer cells with microsatellite instability. *Science* 268, 1336-1338.
- Marshall R.E., Anggiansah A. and Owen W.J. (1997). Bile in the oesophagus: clinical relevance and ambulatory detection. *Br. J. Surg.* 84, 21-28.
- Meltzer S.J., Mane S.M., Wood P.K., Resau J.H., Newkirk C., Terzakis J.A., Korelitz B.I., Weinstein W.M. and Needleman S.W. (1990). Activation of c-Ki-ras in human gastrointestinal dysplasias determined by direct sequencing of polymerase chain reaction products. *Cancer Res.* 50, 3627-3630.
- Meltzer S.J., Yin J., Manin B., Rhyu M.G., Cottrell J., Hudson E., Redd J.L., Krasna M.J., Abraham J.M. and Reid B.J. (1994). Microsatellite instability occurs frequently and in both diploid and aneuploid cell

Barrett esophagus and cancer

- populations of Barrett's-associated esophageal adenocarcinomas. *Cancer Res.* 54, 3379-3382.
- Menke-Pluymers M.B., Hop W.C., Dees J., van Blankenstein M. and Tilanus H.W. (1993). Risk factors for the development of an adenocarcinoma in columnar-lined (Barrett) esophagus. *Cancer* 72, 1155-1158.
- Miros M., Kerlin P. and Walker N. (1991). Only patients with dysplasia progress to adenocarcinoma in Barrett's oesophagus. *Gut* 32, 1441-1446.
- Miyake S., Nagai K., Yoshino K., Oto M., Endo M. and Yuasa Y. (1994). Point mutations and allelic deletion of tumor suppressor gene DCC in human esophageal squamous cell carcinomas and their relation to metastasis. *Cancer Res.* 54, 3007-3010.
- Moore J.H., Lesser E.J., Erdody D.H., Natale R.B., Orringer M.B. and Beer D.G. (1994). Intestinal differentiation and p53 gene alterations in Barrett's esophagus and esophageal adenocarcinoma. *Int. J. Cancer* 56, 487-493.
- Morales T.G., Sampliner R.E. and Bhattacharyya A. (1997). Intestinal metaplasia of the gastric cardia. *Am. J. Gastroenterol.* 92, 414-418.
- Moreau H., Laugier R., Gargouri Y., Ferrato F. and Verger R. (1988). Human preduodenal lipase is entirely of gastric fundic origin. *Gastroenterology* 95, 1221-1226.
- Moreau H., Bernadac A., Gargouri Y., Benkouka F., Laugier R. and Verger R. (1989). Immunocytolocalization of human gastric lipase in chief cells of the fundic mucosa. *Histochemistry* 91, 419-423.
- Morson B.C. and Belcher J.R. (1952). Adenocarcinoma of the esophagus and ectopic gastric mucosa. *Br. J. Cancer* 6, 127-130.
- Muzeau F., Flejou J.F., Belghiti J., Thomas G. and Hamelin R. (1997). Infrequent microsatellite instability in oesophageal cancers. *Br. J. Cancer* 75, 1336-1339.
- Naef A.P., Savary M. and Ozello T. (1975). Columnar lined lower esophagus - an acquired lesion with malignant predisposition: Report of 140 cases of Barrett's esophagus with 12 carcinomas. *J. Thorac. Cardiovasc. Surg.* 70, 826-835.
- Nakamura T., Nekarda H., Hoelscher A.H., Bollschweiler E., Harbeck N., Becker K. and Siewert J.R. (1994). Prognostic value of DNA ploidy and c-erbB-2 oncoprotein overexpression in adenocarcinoma of Barrett's esophagus. *Cancer* 73, 1785-1794.
- Nandurkar S., Talley N.J., Martin C.J., Ng T.H. and Adams S. (1997). Short segment Barrett's oesophagus: prevalence, diagnosis and associations. *Gut* 40, 710-715.
- Neshat K., Sanchez C.A., Galipeau P.C., Blount P.L., Levine D.S., Joslyn G. and Reid B.J. (1994). p53 mutations in Barrett's adenocarcinoma and high-grade dysplasia. *Gastroenterology* 106, 1589-1595.
- Neumann C.S. and Cooper B.T. (1994). 24 hour ambulatory oesophageal pH monitoring in uncomplicated Barrett's oesophagus. *Gut* 35, 1352-1355.
- Offner F.A., Lewin K.J. and Weinstein W.M. (1996). Metaplastic columnar cells in Barrett's esophagus: a common and neglected cell type. *Hum. Pathol.* 27, 885-889.
- Ogasawara S., Tamura G., Maesawa C., Suzuki Y., Ishida K., Satoh N., Uesugi N., Saito K. and Satodate R. (1996). Common deleted region on the long arm of chromosome 5 in esophageal carcinoma. *Gastroenterology* 110, 52-57.
- Ohkusa T., Yamamoto M., Kataoka K., Kyoji T., Ueda F., Fujimoto H., Sasabe M., Tamura Y., Hosoi H. and Tokoi S. (1993). Electron microscopic study of intercellular junctions in human gastric mucosa with special reference to their relationship to gastric ulcer. *Gut* 34, 86-89.
- Parrilla P., Liron R., Martinez de Haro L.F., Ortiz A., Molina J. and De Andres B. (1997). Gastric surgery does not increase the risk of developing Barrett's esophagus. *Am. J. Gastroenterol.* 92, 960-963.
- Paull A., Trier J.S., Dalton M.D., Camp R.C., Loeb P. and Goyal R.K. (1976). The histologic spectrum of Barrett's esophagus. *N. Engl. J. Med.* 295, 476-480.
- Pera M., Trastek V.F., Carpenter H.A., Allen M.S., Deschamps C. and Pairolero P.C. (1992). Barrett's esophagus with high-grade dysplasia: an indication for esophagectomy? *Ann. Thorac. Surg.* 54, 199-204.
- Pera M., Cameron A.J., Trastek V.F., Carpenter H.A. and Zinsmeister A.R. (1993). Increasing incidence of adenocarcinoma of the esophagus and esophagogastric junction. *Gastroenterology* 104, 510-513.
- Polkowski W., van Lanschot J.J.B., ten Kate F.J.W., Baak J.P.A., Tytgat G.N.J., Obertop H., Voorn W.J. and Offerhaus G.J.A. (1995). The value of p53 and Ki67 as markers for tumour progression in the Barrett's dysplasia-carcinoma sequence. *Surg. Oncol.* 4, 163-171.
- Polkowski W., Meijer G.A., Baak J.P.A., ten Kate F.J.W., Obertop H., Offerhaus G.J.A. and van Lanschot J.J.B. (1997). Reproducibility of p53 and Ki-67 immunohistochemistry in Barrett's esophagus. *Anal. Quant. Cytol. Histol.* 19, 246-254.
- Polkowski W., Baak J.P.A., van Lanschot J.J.B., Meijer G.A., Schuurmans L., ten Kate F.J.W., Obertop H. and Offerhaus G.J.A. (1998). Clinical decision making in Barrett's oesophagus can be supported by computerized immunohistochemistry and morphometry of features associated with proliferation and differentiation. *J. Pathol.* 184, 161-168.
- Poller D.N., Steele R.J. and Morrell K. (1992). Epidermal growth factor receptor expression in Barrett's esophagus. *Arch. Pathol. Lab. Med.* 116, 1226-1227.
- Powell D.W. (1981). Barrier function of epithelia. *Am. J. Physiol.* 241, G275-288.
- Powell J. and McConkey C.C. (1992). The rising trend in oesophageal adenocarcinoma and gastric cardia. *Eur. J. Cancer Prev.* 1, 265-269.
- Powell S.M., Papadopoulos N., Kinzler K.W., Smolinski K.N. and Meltzer S.J. (1994). APC gene mutations in the mutation cluster region are rare in esophageal cancers. *Gastroenterology* 107, 1759-1763.
- Provenzale D., Kemp J.A., Arora S. and Wong J.B. (1994). A guide for surveillance of patients with Barrett's esophagus. *Am. J. Gastroenterol.* 89, 670-680.
- Quddus M.R., Henley J.D., Sulaiman R.A., Palumbo T.C. and Gnepp D.R. (1997). *Helicobacter pylori* infection and adenocarcinoma arising in Barrett's esophagus. *Hum. Pathol.* 28, 1007-1009.
- Ramel S., Reid B.J., Sanchez C.A., Blount P.L., Levine D.S., Neshat K., Haggitt R.C., Dean P.J., Thor K. and Rabinovitch P.S. (1992). Evaluation of p53 protein expression in Barrett's esophagus by two-parameter flow cytometry. *Gastroenterology* 102, 1220-1228.
- Rector L.E. and Connerley M.L. (1941). Aberrant mucosa in the esophagus in infants and in children. *Arch. Pathol.* 31, 285-294.
- Reid B.J., Haggitt R.C., Rubin C.E., Roth G., Surawicz C.M., van Belle G., Lewin K., Weinstein W.M., Antonioli D.A., Goldman H., MacDonald W. and Owen D. (1988). Observer variation in the diagnosis of dysplasia in Barrett's esophagus. *Hum. Pathol.* 19, 166-178.
- Reid B.J., Sanchez C.A., Blount P.L. and Levine D.S. (1993). Barrett's

Barrett esophagus and cancer

- esophagus: cell cycle abnormalities in advancing stages of neoplastic progression. *Gastroenterology* 105, 119-129.
- Rice T.W., Falk G.W., Achkar E. and Petras R.E. (1993). Surgical management of high-grade dysplasia in Barrett's esophagus. *Am. J. Gastroenterol.* 88, 1832-1836.
- Rice T.W., Goldblum J.R., Falk G.W., Tubbs R.R., Kirby T.J. and Casey G. (1994). p53 immunoreactivity in Barrett's metaplasia, dysplasia, and carcinoma. *J. Thorac. Cardiovasc. Surg.* 108, 1132-1137.
- Riddell R.H., Goldman H., Ransohoff D.F., Appelman H.D., Fenoglio C.M., Haggitt R.C., Ahren C., Correa P., Hamilton S.R., Morson B.C., Sommers S.C. and Yardley J.H. (1983). Dysplasia in inflammatory bowel disease: standardized classification with provisional clinical applications. *Hum. Pathol.* 14, 931-968.
- Rodrigues N.R., Rowan A. and Smith M.E.F. (1990). p53 mutations in colorectal cancer. *Proc. Natl. Acad. Sci. USA* 87, 7555-7559.
- Roe D.J., Alberts D.S., Wargovich M.J., Bostick R.M., Garewal H.S., Einspahr J., Fosdick L., Ramsey L., Woods C. and McGee D.L. (1996). Reproducibility of the measurement of colonic proliferation using bromodeoxyuridine across laboratories. *Cancer Epidemiol. Biomarkers Prev.* 5, 349-353.
- Rusch V.W., Levine D.S., Haggitt R. and Reid B.J. (1994). The management of high grade dysplasia and early cancer in Barrett's esophagus. A multidisciplinary problem. *Cancer* 74, 1225-1229.
- Sagan C., Flejou J.F., Diebold M.D., Potet F. and Le Bodic M.F. (1994). Reproductibilité des critères histologiques de dysplasie sur muqueuse de Barrett. *Gastroenterol. Clin. Biol.* 18, D31-D34.
- Sawhney R.A., Shields H.M., Allan C.H., Boch J.A., Trier J.S. and Antonioli D.A. (1996). Morphological characterization of the squamocolumnar junction of the esophagus in patients with and without Barrett's epithelium. *Dig. Dis. Sci.* 41, 1088-1098.
- Schechter A.L., Stern D.F., Vaidyanathan L., Decker S.J.X., Drebin J.A., Greene M.I. and Weinberg R.A. (1984). The neu oncogene: an erb-B-related gene encoding a 185,000-Mr tumour antigen. *Nature* 312, 513-516.
- Schneider P.M., Casson A.G., Levin B., Garewal H.S., Hoelscher A.H., Becker K., Dittler H.J., Cleary K.R., Troster M., Siewert J.R. and Roth J.A. (1996). Mutations of p53 in Barrett's esophagus and Barrett's cancer: a prospective study of ninety-eight cases. *J. Thorac. Cardiovasc. Surg.* 111, 323-331.
- Schnell T.G., Sontag S.J. and Chejfec G. (1992). Adenocarcinomas arising in tongues or short segments of Barrett's esophagus. *Dig. Dis. Sci.* 37, 137-143.
- Shiozaki H., Tahara H., Oka H., Miyata M., Kobayashi K., Tamura S., Iihara K., Doki Y., Hirano S. and Takeichi M. (1991). Expression of immunoreactive E-cadherin adhesion molecules in human cancers. *Am. J. Pathol.* 139, 17-23.
- Shiozaki H., Oka H., Inoue M., Tamura S. and Monden M. (1996). E-cadherin mediated adhesion system in cancer cells. *Cancer* 77, 1605-1613.
- Skinner D.B., Walther B.C., Riddell R.H., Schmidt H., Iacone C. and DeMeester T.R. (1983). Barrett's esophagus: comparison of benign and malignant cases. *Ann. Surg.* 198, 554-565.
- Slomiany B.L., Murty V.L., Piotrowski J. and Slomiany A. (1994). Gastroprotective agents in mucosal defense against *Helicobacter pylori*. *Gen. Pharmacol.* 25, 833-841.
- Soong R., Robbins P.D., Dix B.R., Griew F., Lim B., Knowles S., Williams K.E., Turbett G.R., House A.K. and Iacopetta B.J. (1996). Concordance between p53 protein overexpression and gene mutation in a large series of common human carcinomas. *Hum. Pathol.* 27, 1050-1055.
- Spechler S.J. (1997a). Esophageal columnar metaplasia (Barrett's esophagus). *Gastrointest. Endosc. Clin. N. Am.* 7, 1-18.
- Spechler S.J. (1997b). The columnar lined oesophagus: a riddle wrapped in a mystery inside an enigma. *Gut* 41, 710-711.
- Spechler S.J., Zeroogian J.M., Antonioli D.A., Wang H.H. and Goyal R.K. (1994). Prevalence of metaplasia at the gastro-oesophageal junction. *Lancet* 344, 1533-1536.
- Stachura J., Konturek J., Urbanczyk K., Bogdal J. and Domschke W. (1995). Pancreatic metaplasia of the human gastric mucosa is associated with high expression of transforming growth factor alpha but not of epidermal growth factor. *Histopathology* 27, 509-515.
- Stark M.E. and Szurszewski J.H. (1992). Role of nitric oxide in gastrointestinal and hepatic function and disease. *Gastroenterology* 103, 1928-1949.
- Stein H.J., Barlow A.P., DeMeester T.R. and Hinder R.A. (1992). Complications of gastroesophageal reflux disease. Role of the lower esophageal sphincter, esophageal acid and acid/alkaline exposure, and duodenogastric reflux. *Ann. Surg.* 216, 35-43.
- Stipa F., Stein H.J., Feussner H., Kraemer S. and Siewert J.R. (1997). Assessment of non-acid esophageal reflux: comparison between long-term reflux aspiration test and fiberoptic bilirubin monitoring. *Dis. Esophagus* 10, 24-28.
- Strader D.B., Benjamin S.B., Orbuch M., Lubensky T.A., Gibril F., Weber C., Fishbeyn V.A., Jensen R.T. and Metz D.C. (1995). Esophageal function and occurrence of Barrett's esophagus in Zollinger-Ellison syndrome. *Digestion* 56, 347-356.
- Swami S., Kumble S. and Triadafilopoulos G. (1995). E-cadherin expression in gastroesophageal reflux disease, Barrett's esophagus, and esophageal adenocarcinoma: an immunohistochemical and immunoblot study. *Am. J. Gastroenterol.* 90, 1808-1813.
- Sy M.S., Mori H. and Liu D. (1997). CD44 as a marker in human cancers. *Curr. Opin. Oncol.* 9, 108-112.
- Symmans P.J., Linehan J.M., Brito M.J. and Filipe M.I. (1994). p53 expression in Barrett's oesophagus, dysplasia, and adenocarcinoma using antibody DO-7. *J. Pathol.* 173, 221-226.
- Takayama T., Shiozaki H., Shibamoto S., Oka H., Kimura Y., Tamura S., Inoue M., Monden T., Ito F. and Monden M. (1996). Beta-catenin expression in human cancers. *Am. J. Pathol.* 148, 39-46.
- Tanaka N., Ishihara M., Lamphier M.S., Nozawa H., Matsuyama T., Mak T.W., Aizawa S., Tokino T., Oren M. and Taniguchi T. (1996). Cooperation of the tumour suppressors IRF-1 and p53 in response to DNA damage. *Nature* 382, 816-818.
- Tileston W. (1906). Peptic ulcer of the esophagus. *Am. J. Med. Sci.* 132, 240-265.
- Tosi P., Filipe M.I., Luzi P., Miracco C., Santopietro R., Lio R., Sforza V. and Barbini P. (1993). Gastric intestinal metaplasia type III cases are classified as low-grade dysplasia on the basis of morphometry. *J. Pathol.* 169, 73-78.
- Trautmann B., Wittekind C., Strobel D., Meixner H., Keymling J., Gossner L., Ell C. and Hahn E.G. (1996). K-ras point mutations are rare events in premalignant forms of Barrett's oesophagus. *Eur. J. Gastroenterol. Hepatol.* 8, 799-804.
- Trudgill N.J., Suvarna S.K., Kapur K.C. and Riley S.A. (1997). Intestinal metaplasia at the squamocolumnar junction in patients attending for diagnostic gastroscopy. *Gut* 41, 585-589.
- Tytgat G.N. (1995). Does endoscopic surveillance in esophageal columnar metaplasia (Barrett's esophagus) have any real value? *Endoscopy* 27, 19-26.

Barrett esophagus and cancer

- Tytgat G.N. and Hameeteman W. (1992). The neoplastic potential of columnar-lined (Barrett's) esophagus. *World J. Surg.* 16, 308-312.
- Uchida Y., Matsuda K., Sasahara K., Kawabata H. and Nishioka M. (1995). Immunohistochemistry of gap junctions in normal and diseased gastric mucosa of humans. *Gastroenterology* 109, 1492-1496.
- Vaezi M.F. and Richter J.E. (1995). Synergism of acid and duodenogastroesophageal reflux in complicated Barrett's esophagus. *Surgery* 117, 699-704.
- Waldmann V. and Rabes H.M. (1996). What's new in ras genes? Physiological role of ras genes in signal transduction and significance of ras gene activation in tumorigenesis. *Pathol. Res. Pract.* 192, 883-891.
- Wang H.H., Hsieh C.C. and Antonioli D.A. (1994). Rising incidence rate of esophageal adenocarcinoma and use of pharmaceutical agents that relax the lower esophageal sphincter (United States). *Cancer Causes Control* 5, 573-578.
- Wang H.H., Zeroogian J.M., Spechler S.J., Goyal R.K. and Antonioli D.A. (1996). Prevalence and significance of pancreatic acinar metaplasia at the gastroesophageal junction. *Am. J. Surg. Pathol.* 20, 1507-1510.
- Wesdorp I.C.E., Bartlesman J.F., Schipper M.E.I., Offerhaus G.J. and Tytgat G.N.J. (1981). Malignancy and premalignancy in Barrett's esophagus: a clinical, endoscopic, and histological study. *Acta Endoscopica* 11, 317-326.
- Weston A.P., Krmpotich P.T., Cherian R., Dixon A. and Topalovski M. (1997a). Prospective long-term endoscopic and histological follow-up of short segment Barrett's esophagus: comparison with traditional long segment Barrett's esophagus. *Am. J. Gastroenterol.* 92, 407-413.
- Weston A.P., Krmpotich P.T., Cherian R., Dixon A. and Topalovski M. (1997b). Prospective evaluation of intestinal metaplasia and dysplasia within the cardia of patients with Barrett's esophagus. *Dig. Dis. Sci.* 42, 597-602.
- Wojdemann M., Norregaard P., Sternby B., Worning H. and Olsen O. (1995). Low doses of pentagastrin stimulate gastric lipase secretion in man. *Scand. J. Gastroenterol.* 30, 631-634.
- Wong D.J., Barrett M.T., Stoger R., Emond M.J. and Reid B.J. (1997). p16INK4a promoter is hypermethylated at a high frequency in esophageal adenocarcinomas. *Cancer Res.* 57, 2619-2622.
- Wynford-Thomas D. (1992). P53 in tumour pathology: can we trust immunocytochemistry? *J. Pathol.* 166, 329-330.
- Yacoub L., Goldman H. and Odze R.D. (1997). Transforming growth factor-alpha, epidermal growth factor receptor, and MiB-1 expression in Barrett's-associated neoplasia: correlation with prognosis. *Mod. Pathol.* 10, 105-112.
- Yamamoto H., Sawai H. and Peruhio M. (1997). Frameshift somatic mutations in gastrointestinal cancer of the microsatellite mutator phenotype. *Cancer Res.* 57, 4420-4426.
- Younes M., Lebovitz R.M., Lechago L.V. and Lechago J. (1993). p53 protein accumulation in Barrett's metaplasia, dysplasia, and carcinoma: a follow-up study. *Gastroenterology* 105, 1637-1642.
- Younes M., Ertan A., Lechago L.V., Somoano J.R. and Lechago J. (1997). p53 protein accumulation is a specific marker of malignant potential in Barrett's metaplasia. *Dig. Dis. Sci.* 42, 697-701.

Accepted January 22, 1999