

Intraepidermal free nerve fiber endings in the hairless skin of the rat as revealed by the zinc iodide-osmium tetroxide technique

T. Müller

Institute for Anatomy, University of Mainz, Germany

Summary. The nerve fiber distribution in the epidermis of the hairless rat skin was studied light microscopically by means of zinc iodide-osmium tetroxide staining. Two different morphological types of free nerve fiber endings could be detected: clusters of relatively thick nerve fibers stretched up through the spinous layer up to the granular layer sending off terminal branches. In addition, many solitary thin varicose nerve fibers were seen within the epidermis. The observed discrepancies in nerve fiber diameters appeared to be larger than those reported for human intraepidermal nerve fibers in recent immunohistochemical studies. Moreover, dendritic cells, most probably representing Langerhans cells, could be selectively stained. These cells appeared to be in a close location to thin varicose nerve fibers. Both types of demonstrated free nerve endings have to be functionally connected with different sensoric functions. Possibly, a subpopulation of the thin nerve fibers might possess primarily a nociceptive task, whereas the thick ones have most probably to be regarded as mechanoreceptive. The nerve fibers innervating dendritic cells appear to be identical to the peptidergic ones which may regulate the antigen-presenting capacity of these cells. Due to its selectivity for intraepidermal nerve fibers, the used method might supplement immunohistochemical procedures in a helpful manner.

Key words: Neuroimmunology, Mechanoreception, Thermoreception, Nociception, methylene blue

Introduction

From the introduction of gold chloride impregnation, supravital methylene blue staining and silver impregnation as neurohistological techniques during the 19th century to the mid of the 20th century, the existence of free nerve endings within the epidermis of the skin

was not called in question (for review see Müller, 1998). After the establishment of the electron microscope in neuroanatomic research, the occurrence of such nerve fibers could not be proved for a long time, but was finally confirmed by Cauna (1980). Nevertheless, Cauna (1980) could only detect a few axons penetrating the epidermis. During the eighties, immunohistochemical techniques for the detection of the neuropeptides substance P (SP) and calcitonin-gene-related peptide (CGRP) were developed which could also demonstrate subpopulations of intraepidermal nerve fibers (Kruger et al., 1985, 1989). Finally, larger amounts of intraepidermal nerve fibers were visualised by immunohistochemistry on protein gene product 9.5 (PGP 9.5) (Wang et al., 1990).

In early studies performed by methylene blue supravital staining, different morphological types of intraepidermal nerve fibers could be shown (Botezat, 1912). Unfortunately, these observations were only documented by drawings. A similar discrimination is also possible in the hairy and hairless skin on the snout of rodents by PGP 9.5-immunohistochemistry (Rice et al., 1993; Crivellato et al., 1994). Up to now, a differentiation of morphological nerve fiber types was still not possible in the hairless skin of the rat paws by immunohistochemistry. Recently, Müller (1998) confirmed by means of methylene blue supravital staining the former results of Botezat (1912) and published the first photographs of different morphological nerve fiber endings in the epidermis of the rat paws obtained by supravital methylene blue staining.

The zinc iodide-osmium tetroxide (ZIO) technique was introduced in neuroanatomy by Maillet (1959). Later, only one paper has been published which reported that the method is also suited for staining intraepidermal nerve fibers, but without showing any details (Jabonero and Perez Casas, 1962). Recently, this procedure was light microscopically used for the demonstration of nerve fibers in the epidermis of the hairy skin on the rat snout (Müller, 1999).

Up to now, this method has not been applied to a systematic investigation of intraepidermal nerve fibers in

Offprint requests to: Priv.-Doz. Dr. Thomas Müller, Institute for Anatomy, University of Mainz, Saarstr. 19-21, D-55099 Mainz, Federal Republic of Germany. Fax: (49) (61 31) 3925401. e-mail: tmueller@mail.uni-mainz.de

the hairless skin. Therefore, the aim of the present study was to use the ZIO-technique for the investigation of the hairless palmar and plantar skin of the rat paws. The results are compared with recent findings obtained by immunohistochemistry as well as methylene blue supravital staining.

Materials and methods

Treatment of animals

General principles of animal care were applied throughout these experiments and all procedures complied with the German law on the protection of animals. Adult Sprague-Dawley rats were used for the experiments. The animals were anaesthetised with tribromethanol (0.3 mg/kg) followed by cervical dislocation. Small pieces (approximately 2 mm² epithelial surface) of the hairless skin obtained from the palmar and plantar sites of the paws were investigated.

Staining with the ZIO technique

Impregnation by the ZIO technique was performed according to Maillet (1959) as modified by Müller (1999). For this purpose, 2 stock solutions were necessary. The first was 2% aqueous osmium tetroxide. The second was prepared by adding 12-15 gramm zinc powder and 5 gramm iodine to 200 ml distilled water and subsequent shaking in a heat-stable glass bottle (exothermic reaction). One part of the first stock solution was mixed with 4 parts of the second reagent. The tissues were then immersed in this mixture for 15-30 hours at room temperature. Subsequently, the specimens were washed overnight in distilled water.

The tissues were dehydrated in 100% tertiary butanol (melting point: 25 °C) for 48 hours. The alcohol was changed several times. After dehydration, the specimens were stored for 1 hour in a mixture of 8 parts decahydronaphthalene (Dekalin®; Chroma, Köngen, Germany) and 2 parts methyl benzoate. Before embedding in paraffin, they were immersed for another hour in pure decahydronaphthalene. 30 µm-thick sections were mounted on untreated glass slides. After drying, they were deparaffinised in xylene and coverslipped with DePeX® (Serva, Heidelberg, Germany). Then, the sections were viewed under the light microscope.

Due to the thickness of the paraffin sections combined with the 3-dimensional structure of the stained sinuous nerve fibres, the tissue was focused and photographed in different planes. Photomontages were required to visualise the intraepidermal routes of the nerve fibres.

After transfer through xylene, the paraffin sections were removed from the glass slides. Then, they were stored in pure ethanol for 1 hour, which was changed several times. The tissues were embedded in Epon® (Serva, Heidelberg, Germany) using propylene oxide as

an intermedium. Some semithin sections of 1 µm were transferred through xylene, coverslipped with DePeX®, and also used for light microscopy. They served as controls for the exact localization of the stained structures.

Results

The light microscopic investigation of the 30 µm-thick paraffin sections revealed an intense staining of the stratum corneum and a selective staining of nerve fibers and dendritic cells in the dermis as well as epidermis (Figs. 1-8). Two different types of free nerve fiber endings could be identified. The first type was characterized by a cluster of relatively thick nerve fiber branches of 1-2 µm in diameter stretching up to the superficial layers of the epidermis; primarily in the upper layers, these branches sent off terminal collaterals forming a more or less complicated intraepithelial plexus (Figs. 1, 3, 5, 6). The second type was represented by ascending thin varicose nerve fibers with diameters of less than 0.5 µm (Figs. 1, 2, 7, 8). The stained nerve fiber profiles could also easily be identified in the 1 µm-semithin sections and their locations in the dermis as well as epidermis could doubtlessly be proved (Figs. 9-11). In addition, a labeling of intraepidermal dendritic cells was observed in the paraffin and semithin sections (Figs. 1, 2, 4, 7, 8, 10). The staining intensity of these cells was not the same in all cases. In some sections, only a staining of the region of the nuclear envelope besides a slight staining of the cytoplasm could be detected (Figs. 8, 10). Nevertheless, strongly stained thin nerve fibers were observed in the vicinity of these cells or apparently in contact with them (Figs. 8, 10).

Discussion

The presented findings confirm the recent light microscopic observations achieved by supravital methylene blue staining (Müller, 1998). In this context, the most interesting result of the present study was that a discrimination between two different morphological types of free nerve fiber endings was possible in the epidermis of the hairless skin of the rat paws. The observations are partially in accordance with results obtained by means of immunohistochemistry. In detail, this means that the intraepidermal nerve fibers stretch up to the superficial cell layers, where they form terminal branches.

Nevertheless, the ZIO-stained sections are in apparent contrast to comparable immunohistochemical studies performed on the rat skin regarding certain aspects (Navarro et al., 1995; Stankovic et al., 1996; Verdu and Navarro, 1997); i.e. such a clear differentiation of two different morphological types of free nerve fiber endings as could be performed in the present study had not been achieved by immunohistochemical detection of PGP 9.5 in the hairless skin of the rat paws. This result would suggest that PGP 9.5

Intraepidermal free nerve fiber endings

is not a real panneuronal marker which stains all nerve fibers. Meanwhile, this conclusion is also supported by findings of immunohistochemical studies; i.e. it was shown electron microscopically that a significant number of intraepithelial nerve fibers does not react with antibodies against PGP 9.5 (Kanazawa and Yoshie, 1996). Therefore, it would be valuable to directly compare the ZIO technique with PGP 9.5 staining, and ascertain whether the same fiber diameter differences are seen with immunostaining.

Regarding the function of the different intraepidermal free nerve fiber endings, the investigation of Woollard et al. (1940) is important. Woollard et al. extended the "theory of punctate sensibility", which had been developed by von Frey (1886), and the "3-dimensional theory of the punctate sensibility" was introduced. This concept is based on the observation that the different types of sensory nerve endings are not only

situated at different distances from each other, but are also located in varying depths in the dermis. The demonstration of different types of intraepidermal free nerve endings as performed in the present study would also extend the validity of this theory into the epidermis. Furthermore, this existence of different morphological types of nerve endings suggests different functions for these neuronal processes. Kennedy and Wendelschafer-Crabb (1993) assumed low threshold mechanoreception for a multitude of intraepidermal nerve endings. This putative function would be most likely for the demonstrated clusters of thick nerve fiber branches. The second type, i.e. the thin nerve fibers, are known to contain the neuropeptides CGRP and SP and therefore have to be regarded as candidates for certain types of nociceptors and thermoreceptors (Navarro et al., 1995). Nevertheless, the function of intraepidermal nerve endings is not absolutely clear. The possibility of

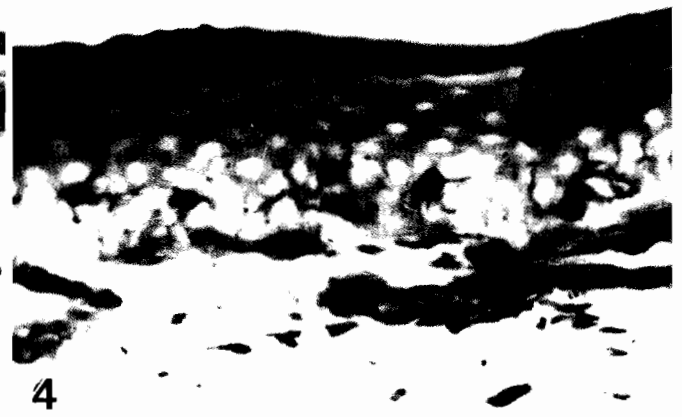

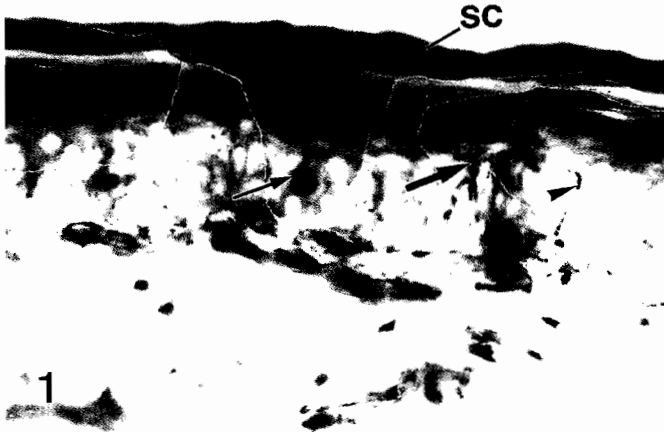

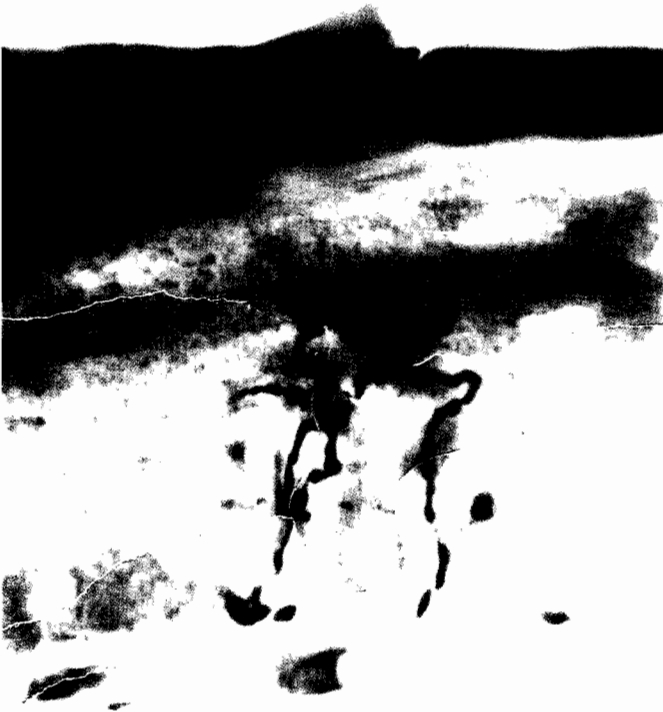
Fig. 1. A dendritic cell (thin arrow), a cluster of thick nerve fiber endings (thick arrow) and an adjacent thin nerve fiber (arrowhead) are labeled within the epidermis; note the homogeneously stained stratum corneum (sc). Paraffin section. x 400

Fig. 2. In addition to thin nerve fibers (arrowheads), a dendritic cell (arrow) is selectively visualised within the epidermis. Paraffin section. x 500

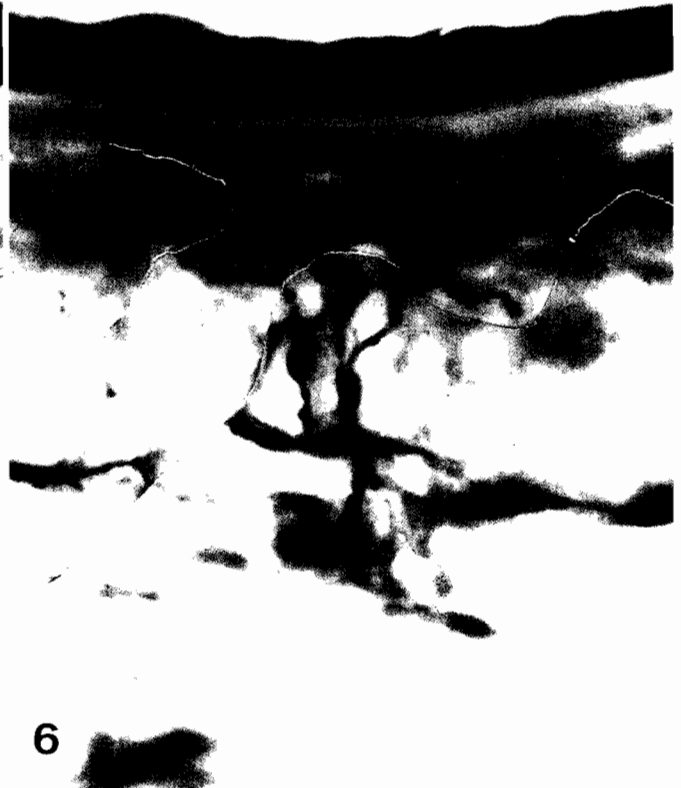
Fig. 3. Two intraepidermal clusters of thick nerve fiber endings are visible (arrows). Paraffin section. x 400

Fig. 4. In some epidermal regions, accumulations of dendritic cells are found. Paraffin section. x 400

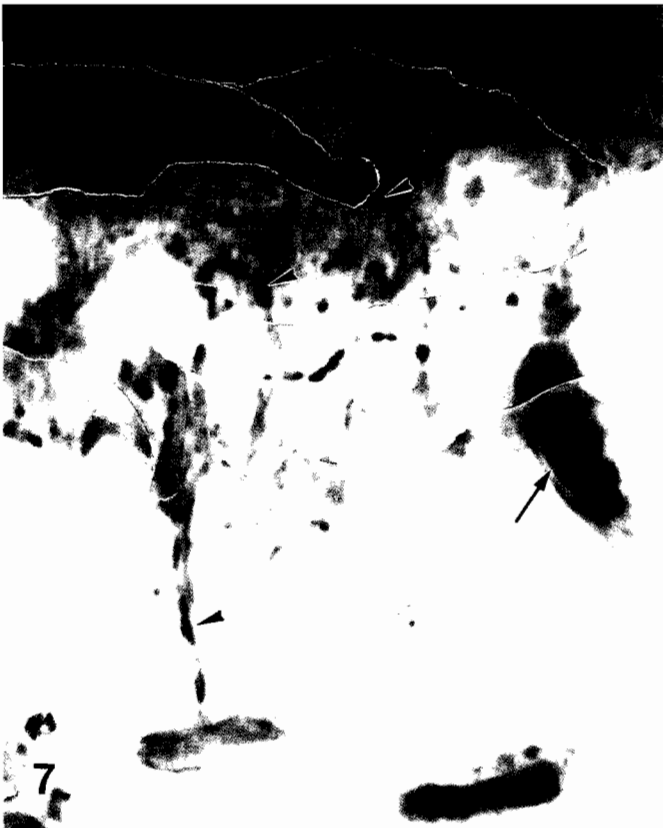Intraepidermal free nerve fiber endings



5



6



Intraepidermal free nerve fiber endings

Fig. 5. Sometimes, only two thick nerve fibers form a cluster ending in the epidermis. Paraffin section. x 800

Fig. 6. Very often, the cluster endings exhibit a complicated intraepidermal arborization pattern. Paraffin section. x 700

Fig. 7. In most cases, the thin nerve fibers are varicose and take a tortuous course within the epidermis (arrowheads). Note a weakly stained perikaryon of a dendritic cell in the vicinity (arrow). Paraffin section. x 2,000

Fig. 8. Varicosities (arrowheads) of thin nerve fibers are apparently situated in a close apposition to a dendritic cell; the nuclear envelope (arrow) of the cell is intensely stained, whereas the cytoplasm is only slightly labeled. Paraffin section. x 2,000

polymodality also exists, i.e. responses of a single nerve fiber for thermal, nociceptive and mechanical stimuli (Kennedy and Wendelschafer-Crabb, 1993). Moreover, due to their intimate associations with keratinocytes, additional trophic effects of the nerve fibers are likely (Chen et al., 1999).

The demonstrated innervation of suprabasally-located dendritic cells has to be discussed separately.

Niebauer et al. (1969) proved that these cells represent Langerhans cells, i.e. antigen-presenting cells. In this context, it has to be mentioned that Langerhans (1868) had observed a close association of these cells with intraepithelial nerve fibers by means of gold chloride impregnation. At the light microscopic level, similar results were also achieved using methylene blue supravital staining and impregnation by the ZIO method

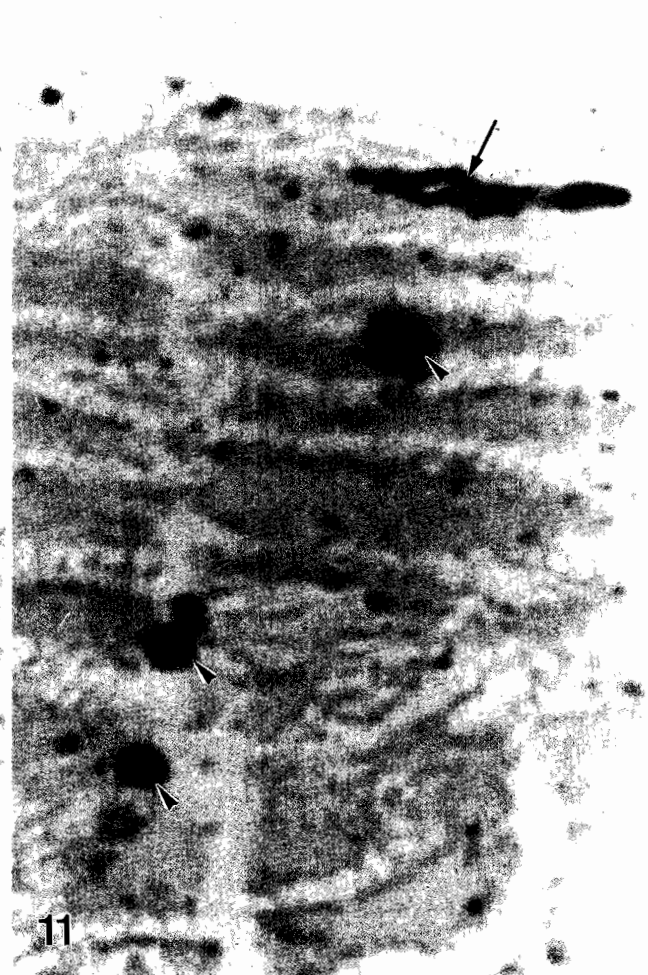
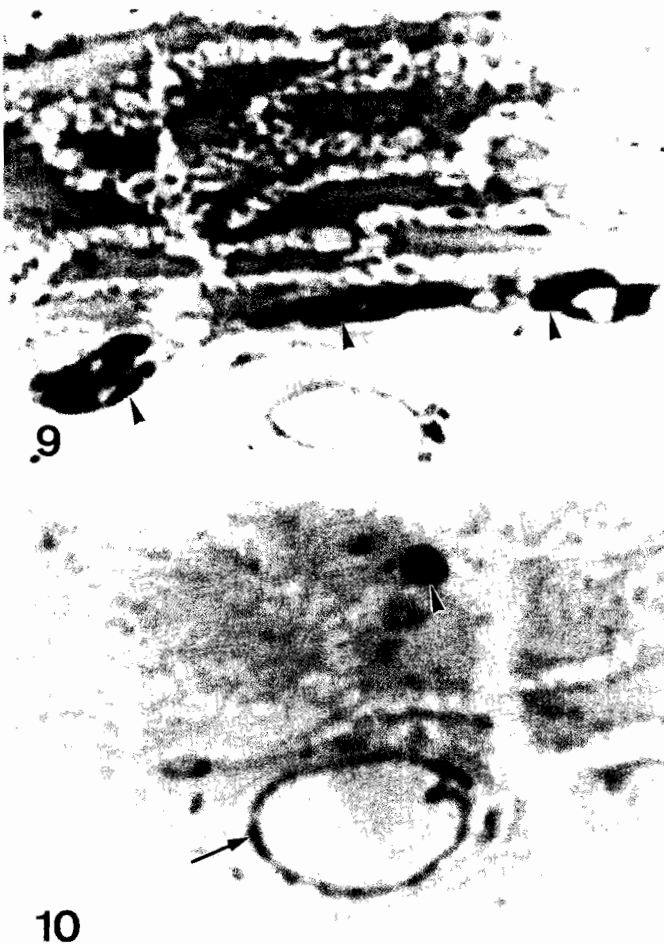

Fig. 9. Stained dermal nerve fibers (arrowheads) are located close to the base of the epidermis. Epon® semi-thin section. x 3,000

Fig. 10. A nerve fiber profile (arrowhead) is located in the vicinity of a slightly stained dendritic cell; note the labeling of the nuclear envelope (arrow) of the cell. Epon® semi-thin section. x 3,000

Fig. 11. Rows of intensely stained axon profiles (arrowheads) mark the intraepidermal route of a nerve fiber; in the upper layers, the nerve fiber is longitudinally sectioned (arrow). Epon® semi-thin section. x 3,000

(Niebauer and Sekido, 1965; Müller, 1996). The same conclusions were also drawn from immunohistochemistry on PGP 9.5 (Gaudillere et al., 1996). Hosoi et al. (1993) showed that CGRP-containing nerve fibers are light microscopically in intimate contact with Langerhans cells and inhibit the antigen-presenting capacity of these cells. Due to the fact that Langerhans cells are characterized by high mobility and the capacity to leave the epidermis and to enter the lymphatic tissue, the associated nerve fibers must show a strong plasticity and spatial adaptation. This points to a parallelism in sprouting of nerve fibers and migration of intraepidermal Langerhans cells (Müller, 1996). This is of neuropathological interest, because a local increase of intraepidermal nerve fibers combined with an accumulation of Langerhans cells induces symptoms like pruritus and hyperalgesia (Springall et al., 1991).

The neuron-like staining behavior of Langerhans cells observed using the ZIO-technique is in accordance with the proved reactivity of these cells for other neuron-specific staining techniques (Müller, 1996). This suggests additional neuronal or neuroendocrine functions for these antigen-presenting cells.

In conclusion, although the ZIO-technique is not absolutely neuron-specific, it is highly selective for intraepidermal nerve fibers, easy to handle and requires relatively low costs. When immunoreactivity for a neuron-specific marker is lost after denervation, the staining, or loss of staining, revealed by alternative techniques like the ZIO-method may give the decisive answer to the question as to whether nerve fibers remain intact, the only deficit being loss of immunoreactivity, or whether they have degenerated (Müller, 1999). Therefore, the ZIO-technique represents a helpful supplement to immunohistochemistry in neuroanatomy.

Acknowledgments. The author is grateful to Mrs. A. de Cuvry, Institute for Anatomy, University of Mainz, for skilful technical assistance.

References

- Botezat E. (1912). Die Apparate des Gefühlsinnes der nackten und behaarten Säugetierhaut, mit Berücksichtigung des Menschen. *Anat. Anz.* 42, 273-318.
- Cauna N. (1980). Fine morphological characteristics and microtopography of the free nerve endings of the human digital skin. *Anat. Rec.* 198, 643-656.
- Chen W.P., Chang Y.C. and Hsieh S.T. (1999). Trophic interactions between sensory nerves and their targets. *J. Biomed. Sci.* 6, 79-85.
- Crivellato E., Travan L., Damiani D., Fusaroli P. and Mallardi F. (1994). Visualization of PGP 9.5 immunoreactive nerve terminals in the mouse snout epidermis. *Acta Histochem.* 96, 197-203.
- Frey M. von (1895). Beiträge zur Sinnesphysiologie der Haut. *Sitzungsber. Saechs. Akad. Wiss., Math.-Naturwiss. Kl.* 47, 166-184.
- Gaudillere A., Misery L., Souchier C., Claudy A. and Schmitt D. (1996). Intimate associations between PGP 9.5-positive nerve fibres and Langerhans cells. *Brit. J. Dermatol.* 135, 343-344.
- Hosoi J., Murphy G.F., Egan C.L., Lerner E.A., Grabbe S., Asahina A. and Granstein R.D. (1993). Regulation of Langerhans cell function by nerves containing calcitonin gene-related peptide. *Nature* 363, 159-163.
- Jabonero V. and Perez Casas A. (1962). Über die feinere Innervation der Haut. I. Die Innervation der Epidermis, der Cutis und der Hautblutgefäße. *Acta Neuroveg.* 22, 353-384.
- Kanazawa H. and Yoshie S. (1996). The taste bud and its innervation in the rat as studied by immunohistochemistry for PGP 9.5. *Arch. Histol. Cytol.* 59, 357-367.
- Kennedy W.R. and Wendelschafer-Crabb G. (1993). The innervation of human epidermis. *J. Neurol. Sci.* 115, 184-190.
- Kruger L., Sampogna S.L., Rodin B.E., Clague J., Brecha N. and Yeh Y. (1985). Thin-fiber cutaneous innervation and its intraepidermal contribution studied by labeling methods and neurotoxin treatment in rats. *Somatosens. Res.* 2, 335-356.
- Kruger L., Silverman J.D., Mantyh P.W., Sternini C. and Brecha N.C. (1989). Peripheral patterns of calcitonin-gene-related peptide general somatic sensory innervation, cutaneous and deep terminations. *J. Comp. Neurol.* 280, 291-302.
- Langerhans P. (1868). Über die Nerven der menschlichen Haut. *Virchows Arch. Pathol. Anat. Physiol.* 44, 325-337.
- Maillet M. (1959). Innervation sympathique du rein: son rôle trophique. *Acta Neuroveg.* 20, 155-179.
- Müller T. (1996). The different morphological types of dendritic cells and their innervation in stratified squamous epithelia of the rat as revealed by methylene blue staining. *Biomed. Res.* 7, 149-157.
- Müller T. (1998). Intraepidermal free nerve fiber endings and their importance for cutaneous pain. *Schmerz* 12, 330-335.
- Müller T. (1999). Characteristic intraepidermal nerve fibre endings of the intervibrissal fur in the mystacial pad of the rat: morphological details revealed by intravital methylene blue staining and the zinc iodide-osmium tetroxide technique. *J. Anat.* 195, 147-152.
- Navarro X., Verdú E., Wendelschafer-Crabb G. and Kennedy W.R. (1995). Innervation of cutaneous structures in the mouse hind paw: a confocal microscopy immunohistochemical study. *J. Neurosci. Res.* 41, 111-120.
- Niebauer G. and Sekido N. (1965). Über die Dendritenzellen der Epidermis. *Arch. Klin. Exp. Dermatol.* 222, 23-42.
- Niebauer G., Krawczyk W.S., Kidd R.L. and Wilgram G.F. (1969). Osmium zinc iodide reactive sites in the epidermal Langerhans cell. *J. Cell Biol.* 43, 80-89.
- Rice F.L., Kinnman E., Aldskogius H., Johansson O. and Arvidsson J. (1993). The innervation of the mystacial pad of the rat as revealed by PGP 9.5 immunofluorescence. *J. Comp. Neurol.* 337, 366-385.
- Springall D.R., Karanth S.S., Kirkham N., Darley C.R. and Polak J.M. (1991). Symptoms of notalgia paresthetica may be explained by increased dermal innervation. *J. Invest. Dermatol.* 97, 555-561.
- Stankovic N., Johansson O. and Hildebrand C. (1996). Occurrence of epidermal nerve endings in glabrous and hairy skin of the rat foot after sciatic regeneration. *Cell Tissue Res.* 284, 161-166.
- Verdú E. and Navarro X. (1997). Comparison of immunohistochemical and functional reinnervation of skin and muscle after peripheral nerve injury. *Exp. Neurol.* 146, 187-198.
- Wang W., Hilliges M., Jernberg T., Wiegleb-Edström D. and Johansson O. (1990). Protein gene product 9.5-immunoreactive nerve fibres and cells in human skin. *Cell Tissue Res.* 261, 25-33.
- Woollard H.H., Weddell G. and Harpman J.A. (1940). Observations on the neurohistological basis of cutaneous pain. *J. Anat.* 74, 413-439.