

Immunohistochemical expression of Retinoblastoma gene product (Rb), p53 protein, MDM2, c-erbB-2, HLA-DR and proliferation indices in human urinary bladder carcinoma

E. Ioachim¹, A. Charchanti¹, N.E. Stavropoulos², A. Skopelitou², E.D. Athanassiou¹ and N.J. Agnantis¹

Department of ¹Pathology and ²Urology, Medical school, University of Ioannina, Ioannina, Greece

Summary. Archival biopsy specimens from transitional cell bladder cancers (n=88) were analysed immunohistochemically for the expression of the retinoblastoma (Rb) gene protein, p53, mdm2, c-erbB-2, HLA-DR antigen and proliferation indices. An altered nuclear expression of Rb, p53 and mdm2 was observed in 55.2%, 33.3% and 18.2% of tumors respectively. Cytoplasmic membrane immunoreactivity (>25% tumor cells) for c-erbB-2 was detected in 14.1% of tumors and aberrant HLA-DR antigen cytoplasmic staining (>5% of tumor cells) in 22.2% of the cases.

P53 overexpression was associated with higher tumor grade and stage. Aberrant HLA-DR antigen expression and PCNA were also correlated with the grade of differentiation and tumor stage. MIB1 was statistically correlated with stage. pRb scores and HLA-DR antigen expression were correlated with proliferation activity as determined by PCNA and MIB1 immunostaining. p53 protein was also strongly correlated with the proliferation index PCNA. A strong correlation between PCNA and MIB1 ($p < 0.0001$) was also found. In addition a statistically positive correlation between p53 and HLA-DR antigen expression was observed. Our data show that, although pRb and p53 protein expressions are not associated between them, they may contribute to the growth fraction of the bladder cancer. In addition, p53 and HLA-DR antigen expression could be indicators of aggressive behavior of bladder cancer.

Key words: Rb, p53, MDM2, c-erbB-2, HL-DR, bladder cancer

Introduction

There is increasing evidence that the alteration of tumor suppressor genes may play a role in the initiation and progression of human tumors. Of these, the best characterized are the retinoblastoma (Rb) and p53 tumor suppressor genes. Rb and p53 share some characteristics: both code for nuclear phosphoproteins present in normal cells and are thought to be involved in cell cycle control and in the negative regulation of cell growth. Alterations of the Rb gene have been observed in several epithelial tumors suggesting that structural abnormalities, including mutations and/or deletions of the Rb gene, may result in the inactivation of tumor suppressor protein and may be involved in tumorigenesis (Harbour et al., 1988; Lee et al., 1988; Goodrich et al., 1991; Lin et al., 1991; Weinberg, 1991; Cordon-Cardo, 1995; Haas-Kogan et al., 1995; Jares et al., 1997). It has been shown that altered pRb patterns, may become an important prognostic variable in bladder cancer (Cairns et al., 1991; Cordon-Cardo et al., 1992; Logothetis et al., 1992; Lipponen and Liukkonen 1995; Wright et al., 1995; Cordon-Cardo et al., 1997; Cordon-Cardo and Reuter, 1997). Mutations of the p53 gene are commonly found in bladder cancer and are associated with an aggressive clinical course (Lipponen, 1993; Moch et al., 1993, 1994; Soini et al., 1993; Wright et al., 1995; Wagner et al., 1995; Skopelitou et al., 1997). More recently, a cellular proto-oncogene product, the mdm2 has been shown to bind to p53 and acts as a negative regulator, inhibiting its transcriptional transactivation activity. It has been shown that aberrant mdm2 and p53 phenotypes may be important diagnostic markers in patients affected by bladder cancer (Lianes et al., 1994). C-erbB-2 amplification and over-expression may provide a useful molecular marker in transitional cell carcinoma of the bladder and merits further investigation as a potential prognostic indicator (Berner et al., 1993; Moch et al., 1993, 1994; Gorgoulis et al., 1995; Wagner et al., 1995). In addition, previous studies showed that

Offprint requests to: Dr. Elli Ioachim, Department of Pathology, Medical School, University of Ioannina, 45110 Ioannina, Greece. Fax: + 30 651 46209. e-mail: nagnanti@cc.uoi.gr.

tumor proliferation in bladder cancer was associated with tumor behavior (Cordon-Cardo et al., 1992; Stavropoulos et al., 1993; Moch et al., 1994; Lipponen and Liukkonen, 1995; Wright et al., 1995; Skopelitou et al., 1997). Irregular HLA-DR antigen expression has been demonstrated in a variety of tumors (Rognum et al., 1983; Wilson et al., 1984; Zuk and Walker, 1988; Zuk et al., 1988; Ioachim et al., 1994) but the role of its expression is not fully understood. In an attempt to elucidate the role of these molecules in bladder cancer, we correlated these molecular markers with each other as well as with other conventional clinicopathological parameters such as: recurrence of the tumor, squamous metaplasia, histological grade and stage.

Materials and methods

The tumour specimens were obtained transurethrally from 88 patients aged 29 to 88 years (mean 71.1 years) with a male to female ratio of 7:1. Biopsies near to and distant from the tumor were also taken. Bladder wall biopsies from patients undergoing transurethral prostatectomy were used as controls. The histopathological diagnosis was made on paraffin sections stained with haematoxylin and eosin. We used the three-grade system proposed by the American Bladder tumour Registry and the World Health Organization (WHO) (Mostofi et al., 1973; Collan et al., 1979). The American Joint Commission-TNM system (1983) was adopted for staging. We used the 'p' category in Ta and T1 tumors and we omit it in T2-T3 muscle-infiltrating, clinically staged lesions, as samples were obtained transurethrally.

Immunohistochemistry

Was performed on one or two selected blocks from each case on 4 μ m tissue sections using the avidin-biotin and immunoperoxidase method as previous described (Hsu et al., 1981). After blockage of endogenous peroxidase with H₂O₂ in methanol for 30 min, sections were immersed in citrate buffer (PH 6.0) in a microwave-resistant container. To unmask the epitopes of Rb, p53, mdm2, MIB1, we microwaved the sections, while PCNA unmasking was achieved without using the heat mediated antigen retrieval method. The sources and dilution of the antibodies are shown in table 1. Immunoperoxidase detection was employed using the ABC method (Dako) and diaminobenzidine substrate. Counter staining was performed with haematoxylin. Tumour sections subjected to the whole procedure expected for incubation with the primary Ab, were used as "negative" substitute. No specific immunoreactivity was detected in these sections.

Immunohistochemical evaluation

Immunostaining (nuclear or cytoplasmic or membrane cytoplasmic) was calculated as the percentage of positive tumour cells in relation to the total number in

representative fields. Every stained nucleus was considered positive, irrespective of intensity. Only intense membrane immunostaining was considered to represent the overexpression of c-erbB-2 protein, since it has been shown to yield the best prognostic associations (De Potter et al., 1990). All slides were reviewed and scored blindly by two observers without any knowledge of other data. Each sample was first scanned with a low magnification, and at least 10 fields were assessed with a high-power magnification.

Statistical analysis

The association of continuous variables was confirmed using a nonparametric test for two or several independent samples or Spearman bivariable correlation. p-values under 0.05 were considered statistically significant.

Results

The histological findings are shown in Table 2. Nuclear Rb gene expression was detected in 55.2%, p53 protein in 33.3% and mdm2 in 18.2% of the tumors (Figs. 1-3). Membrane immunoreactivity for c-erbB-2 (>25% of neoplastic cells) was detected in 14.1% of the tumors (Fig. 4). Aberrant HLA-DR antigen cytoplasmic immunostaining (>5% of neoplastic cells) was detected in 22.2% of tumors (Fig. 5). Nuclear MIB1 (Fig. 6) and anti PCNA immunostaining were also detected in a variety of number of the tumor cells. Simple statistics of the various parameters studied are shown in Table 3.

The clinicopathological data were statistically correlated with the following markers: p53 with grade (p=0.0088) and stage (p=0.0038), HLA-DR with grade (p=0.02) and stage (p=0.0072), PCNA with grade

Table 1. Antibodies used.

ANTIBODIES	SUPPLIER	DILUTION	INCUBATION TIME
Rb (AB-5)#	Oncogene	1:80	Overnight*
DO-7 (IgG2b)#	Ylem	1:200	Overnight*
MDM2 (AB-1)#	Oncogene	1:80	Overnight*
C-erbB-2 (OM-11-925)	ICI, Cambridge	1:500	One hour
Anti-HLA	Dako	1:50	One hour
PC-10	Dako	1:50	One hour
MIB1#	Ylem	1:10	Overnight*

*: with microwave oven antigen retrieval; #: citrate buffer incubation.

Table 2. Histological grade and stage.

STAGE	GRADE I	GRADE II	GRADE III
Pta	16	5	
pT1	7	33	5
pT2-T3		1	18

Tumor markers in bladder cancer

($p=0.0006$) and stage ($p=0.0014$), MIB1 with stage ($p=0.012$). Rb protein expression, mdm2 and c-erbB-2 did not correlate with grade and stage of the tumor. None of the above markers was correlated with squamous metaplasia and the tumor recurrence.

The proliferation indices were statistically correlated with: Rb with PCNA ($p=0.019$) and MIB1 ($p=0.031$),

p53 with PCNA ($p<0.0001$) and HLA-DR with PCNA ($p<0.0001$) and MIB1 ($p=0.015$). A strong correlation between PCNA and MIB1 ($p<0.0001$) was also found. A trend of correlation was found between mdm2 and PCNA ($p=0.057$), c-erbB-2 and MIB1 ($p=0.06$) as well as between Rb and MDM2 ($p=0.055$). In addition, a statistically positive correlation was observed between

Table 3. Simple statistics of various parameters studied.

VARIABLES	MEAN	Std. Dev.	MINIMUM	MAXIMUM	NUMBER OF CASES
Rb*	17.83	21.11	0.00	65.00	87
P53*	14.06	25.61	0.00	95.00	84
MDM2*	0.72	1.92	0.00	10.00	88
C-erbB-2*	11.28	23.48	0.00	100.00	78
HLA-DR*	9.01	18.56	0.00	80.00	74
MIB1*	6.86	11.51	0.00	70.00	79
PCNA*	26.85	29.47	0.00	90.00	84

*: percentage of positive tumour cells.

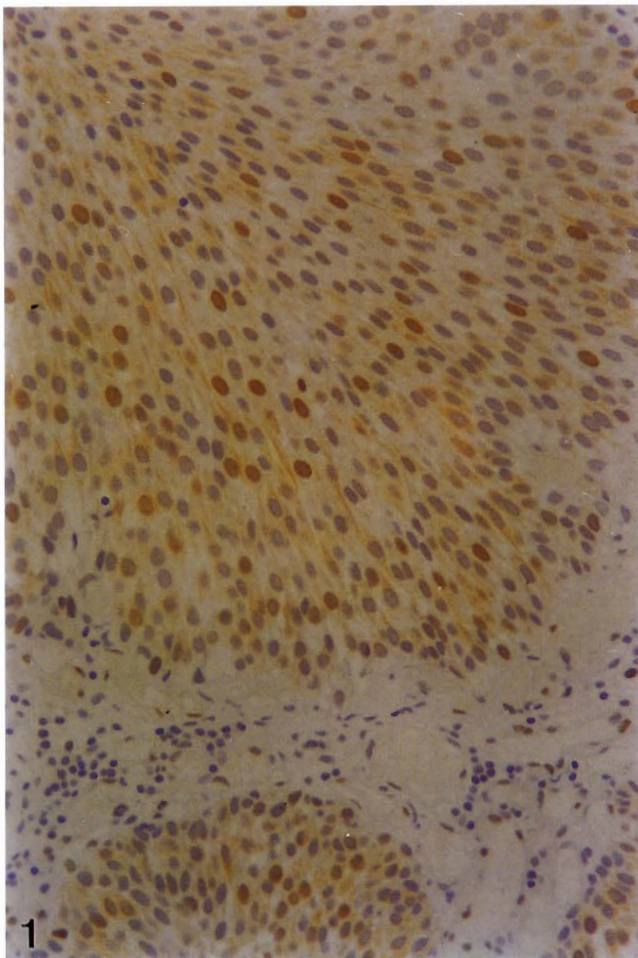


Fig. 1. Nuclear Rb protein staining expression in a case of transitional cell carcinoma of the urinary bladder cancer. ABC, x 200

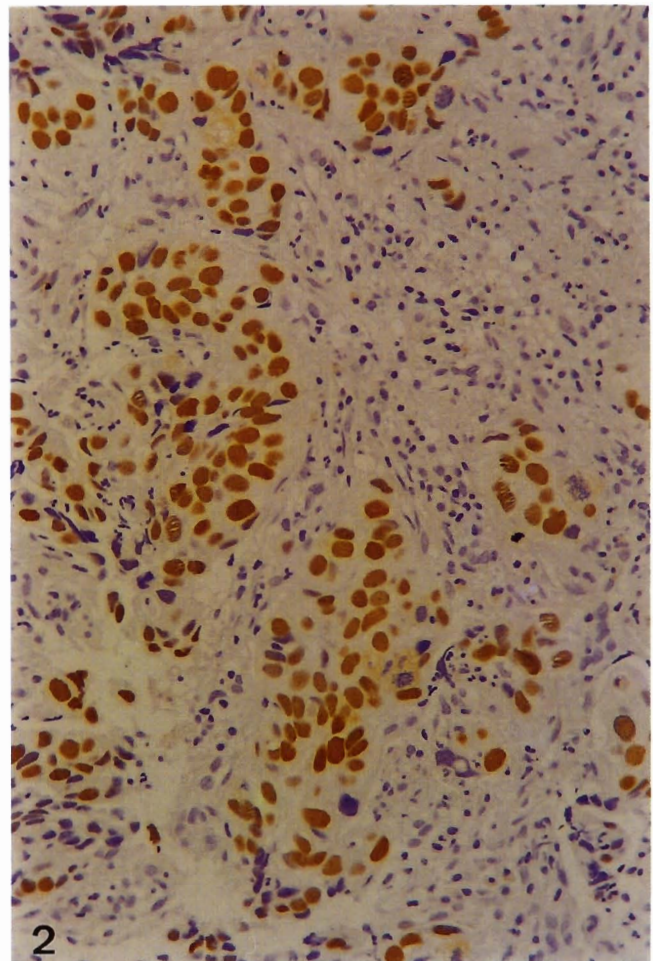


Fig. 2. Extensive nuclear p53 protein expression in a case of infiltrating bladder cancer. ABC, x 200

p53 and HLA-DR antigen expression ($p=0.012$).

Discussion

Little is known about the pathogenesis of transitional cell bladder cancer. Environmental carcinogens, growth factors and oncogene as well as suppressor gene products probably have a critical role in the early development of bladder cancer. Better understanding of the underlying mechanisms might help us in developing new treatment strategies. A number of pathological features have been identified as predictors of the clinical course in urinary bladder cancer. Among them are the grade of differentiation, tumor stage as well as the rate of tumor cell proliferation (Cordon-Cardo et al., 1992; Stavropoulos et al., 1993; Moch et al., 1994; Lipponen and Liukkonen, 1995; Wright et al., 1995; Skopelitou et al., 1997). Deregulation of the cell cycle control is now considered a key event in oncogenesis and alterations of genes involved in this control are a frequent finding in

different cancer models. Mutational inactivation of the retinoblastoma (Rb) gene is considered to be of central importance in the pathogenesis of many human malignant neoplasms. Recently it has become clear that the genomic or epigenetic loss of pRb function leads to uncontrolled cell growth and apoptosis (Cordon-Cardo, 1995; Haas-Kogan et al., 1995). This is not only an initiating event in tumorigenesis, but also a step associated with malignant progression and aggressive outcome (Harbour et al., 1988; Lee et al., 1988; Goodrich et al., 1991; Lin et al., 1991; Weinberg, 1991; Cordon-Cardo, 1995; Haas-Kogan et al., 1995; Jares et al., 1997). It has been shown that altered pRb patterns, may become an important prognostic variable in bladder cancer. Previous studies in bladder cancer have reported that Rb alterations are frequent events and associated with tumor progression and although altered pRb expression occurs in all grades and stages, this is more commonly associated with muscle-invasive tumors (Cairns et al., 1991). Furthermore bladder cancers exhibiting decreased expression of the Rb gene-coded

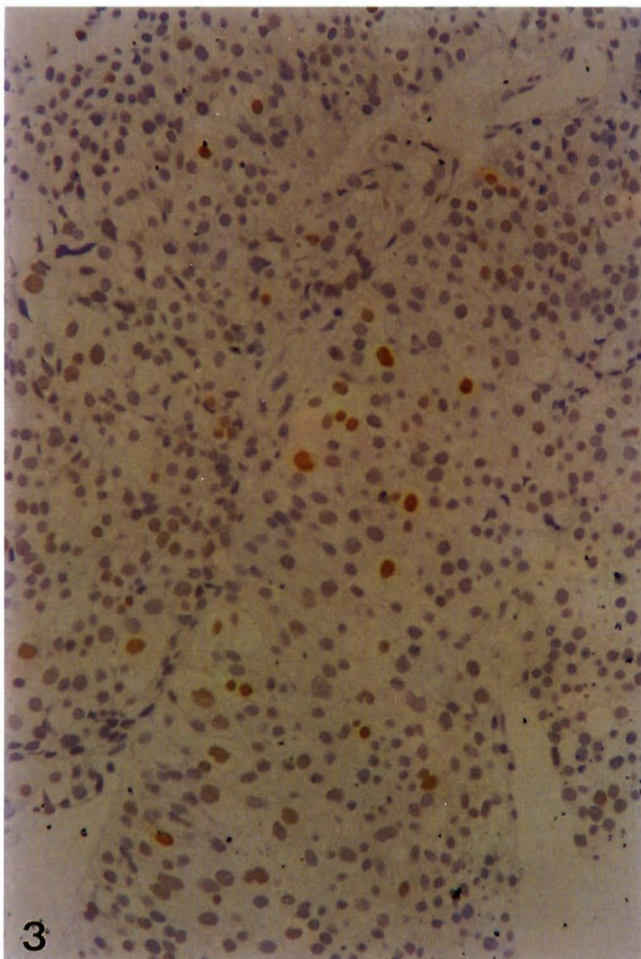


Fig. 3. Nuclear MDM2 immunostaining in a case of transitional cell carcinoma of the urinary bladder cancer. ABC, x 200

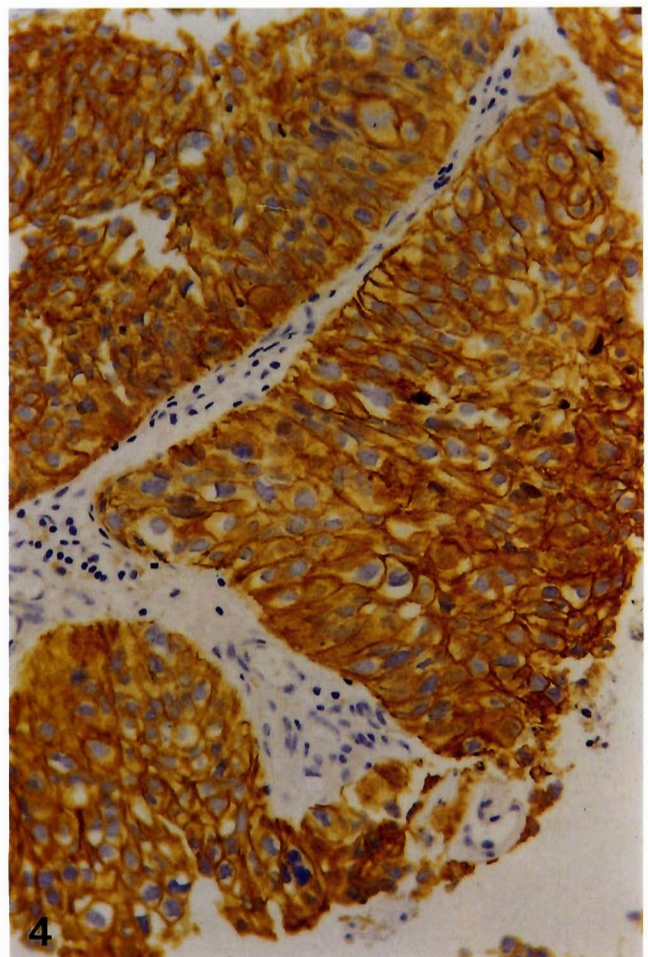


Fig. 4. C-erbB-2 cytoplasmic membrane immunostaining. ABC x 200

Tumor markers in bladder cancer

product (pRb) had a more aggressive biological behavior than those that expressed the Rb protein in the majority of their tumor cells. In addition, reduced expression of the retinoblastoma gene protein is related to cell proliferation (Cairns et al., 1991; Cordon-Cardo et al., 1992, 1997; Logothetis et al., 1992; Lipponen and Liukkonen, 1995; Wright et al., 1995; Cordon-Cardo and Reuter, 1997). In our study pRb expression was detected irrespectively of tumor grade and stage, but a strong relationship with the two proliferation associated indices was found, suggesting that this nuclear protein is a potential growth marker in bladder cancer.

A key role in bladder cancer biology has also been defined for the p53 tumor suppressor gene, which is frequently altered in bladder tumors. P53 mutations can frequently be detected by immunohistochemistry, because many p53 mutations result in a prolonged half-life of the protein. Previous reports indicate that abnormalities in the p53 exist in bladder cancer, are associated with tumor progression and are involved in

the growth regulation of the tumor (Cairns et al., 1991; Logothetis et al., 1992; Lipponen, 1993; Moch et al., 1993, 1994; Soini et al., 1993; Lipponen and Liukkonen, 1995; Wagner et al., 1995, 1997; Wright et al., 1995; Cordon-Cardo and Reuter, 1997; Cordon-Cardo et al., 1997; Skopelitou et al., 1997). In the current study, we found a strong relationship of the p53 protein expression with tumor grade and stage as well as with the proliferative activity, as it was estimated by the proliferation associated index PCNA, confirming the important prognostic value of the p53 in bladder cancer. Although abnormalities of both the Rb and p53 genes has been detected in a number of different human cancers, in our study there was no significant correlation between the expression of these two proteins as reported in other studies (Sawan et al., 1992). Perhaps, these proteins contribute to the regulation of cell growth in different ways.

The relationship between p53 and mdm2 in neoplasia is complex, with examples of both wild type

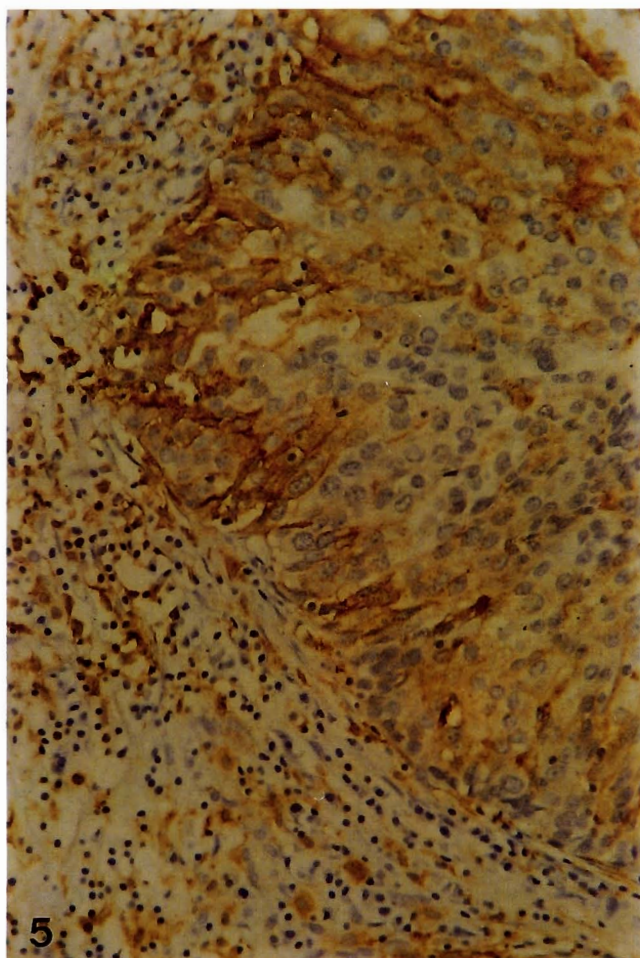


Fig. 5. Aberrant HLA-DR antigen expression in a case of transitional cell bladder cancer. ABC x 200

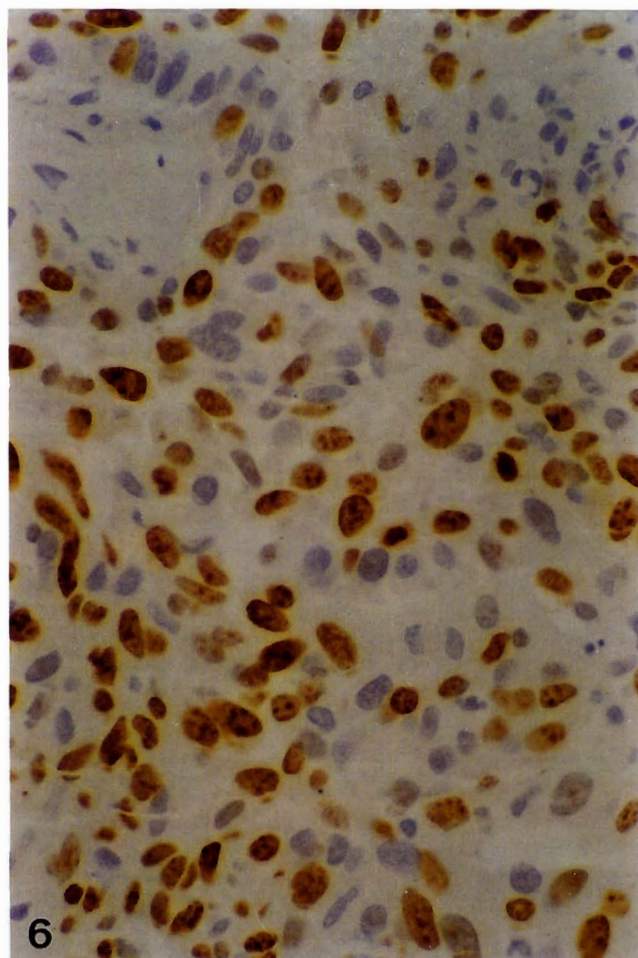


Fig. 6. Nuclear MIB1 expression in a case of infiltrating bladder cancer. ABC x 400

and mutant p53 being associated with both low expression and high expression of mdm2. Mdm2 may have additional roles in the control of transcription and is known to be regulated by mechanisms other than p53-mediated transcriptional control (Thut et al., 1997). Mdm2 can also interact with other critical elements of the cell cycle and apoptotic regulatory controls, such as E2F and Rb (Martin et al., 1995; Xiao et al., 1995). It has been shown that mdm2 was correlated with p53 overexpression and low-stage, low-grade bladder tumor (Lianes et al., 1994). In the present study, we found a limited correlation between mdm2 expression and pRb as well as with the proliferation associated index PCNA. These conflicting results may suggest that different tumor phenotypes might be associated with different etiopathogenic mechanisms or because of the use of multiple methods or antibodies, and therefore there is a variation in epitope availability. C-erbB-2 amplification has also been found in transitional cell carcinomas but its prognostic significance has not been demonstrated. Previous studies have observed an association of c-erbB-2 with metastasis (Moch et al., 1993) as well as with tumor grade or stage (Sato et al., 1992; Moch et al., 1993), while others did not find any correlation (Berner et al., 1993) and their results are in agreement with ours. We also found no correlation with the p53 protein in contrast to the findings of Moch et al. (1993) as well as with the proliferative activity. The latter finding is in line with the report of Moch et al. (1994).

The role of HLA-DR antigen expression by tumor cells is unknown. Although the functional role of this antigen is to mediate communication among immunocompetent cells, in a previous study with frozen sections (Ioachim et al., 1994) we found that HLA-DR antigen expression is independent of lymphocyte subpopulations in bladder cancer. An interesting point of this study is the statistically significant correlation of HLA-DR antigen expression with tumor grade and stage as well as with p53 protein expression indicating an aggressive phenotype. Whether this expression is an independent marker of worse prognosis in bladder tumor or this aberrant expression by tumour cells is mediated by mutant p53 gene is a matter of discussion.

In summary, our data show that, although pRb and p53 proteins are not associated between them, they may contribute in the growth fraction of the bladder cancer, with different pathway. In addition, p53 and HLA-DR antigen expression could be indicators of the aggressiveness of bladder cancer behavior.

Acknowledgments. We thank Antigone Christodoulou for her expert technical assistance.

References

- American Joint Committee on Cancer Bladder (1983). TNM Classification. In: Manual for staging of cancer. 2nd ed. Beahrs O.H. and Meyers M.H. (eds). JB Lippincott. Philadelphia. p 173.
- Berner A., Jacobsen A.B., Fossa S.D. and Nesland J.M. (1993). Expression of c-erbB-2 protein, neuron-specific enolase and DNA flow cytometry in locally advanced transitional cell carcinoma of the urinary bladder. *Histopathology* 22, 327-333.
- Cairns P., Proctor A.J. and Knowles M.A. (1991). Loss of heterozygosity at the Rb locus is frequent and correlates with muscle invasion in bladder carcinoma. *Oncogene* 6, 2305-2310.
- Collan Y., Makinen J. and Heikkinen A. (1979). Histologic grading of transitional cell tumours of the bladder: value of histologic grading (WHO) in prognosis. *Eur. Urol.* 5, 311.
- Cordon-Cardo C. (1995). Mutation of cell cycle regulators. Biological and clinical implications for human neoplasia. *Am. J. Pathol.* 147, 545-60.
- Cordon-Cardo C. and Reuter V. (1997). Alterations of tumour suppressor genes in bladder cancer. *Seminars Diagn. Pathol.* 14, 123-132.
- Cordon-Cardo C., Wartinger D., Petrylak D., Dalbagni G., Fair W.R., Fuks Z. and Reuter V.E. (1992). Altered expression of the retinoblastoma gene product: prognostic indicator in bladder cancer. *J. Natl. Cancer Inst.* 84, 1251-1256.
- De Potter C.R., Beghin C., Makar A.P., Vandekerckhove D. and Roel H.J. (1990). The neu-oncogene protein as a predictive factor for haematogenous metastases in breast cancer patients. *Int. J. Cancer* 45, 55-58.
- Gorgoulis V., Barbatis C., Poulas I. and Karameris A. (1995). Molecular and immunohistochemical evaluation of epidermal growth factor receptor and c-erbB-2. A study in Greek patients. *Modern Pathol.* 8, 758-764.
- Goodrich D.W., Wang N.P., Qian Y-W., Lee EY-HP. and Lee W-H. (1991). The retinoblastoma gene product regulates progression through the G1 phase of the cell cycle. *Cell* 67, 293-302.
- Haas-Kogan D.A., Kogan S.C., Levi D., Dazin P., T'Ang A., Fung Y.K. and Israel M.A. (1995). Inhibition of apoptosis by the retinoblastoma gene product. *EMBO J.* 14, 461-72.
- Harbour J.W., Lai S-L., Whang-Peng J., Gazdar A.F., Minna J.D. and Kaye F.J. (1988). Abnormalities in structure and expression of the human retinoblastoma gene in SCLC. *Science* 241, 353-357.
- Hsu S.M., Raine L. and Fanger H. (1981.) Use of avidin-biotin-peroxidase complex (ABC) in immunoperoxidase techniques: a comparison between ABC and unlabelled antibody (PAP) procedures. *J. Histochem. Cytochem.* 29, 577-580.
- Ioachim E., Stavropoulos N.E., Kitsiou E., Stefanaki S. and Agnantis N.J. (1994). HLA-DR antigen expression and lymphocyte subsets in transitional cell carcinoma of the urinary bladder. An immunohistological study on frozen sections. *J. Pathol.* 174, 183-189.
- Jares P., Rey M., Fernandez P., Campo E., Nadal A., Munoz M., Mallofre C., Muntane J., Nayach I., Estape J. and Cardesa A. (1997). Cyclin D1 and retinoblastoma gene expression in human breast carcinoma: Correlation with tumor proliferation and oestrogen receptor status. *J. Pathol.* 182, 160-166.
- Lee EY-HP., To H., Shew J-Y., Bookstein R., Scully P. and Lee W-H. (1988). Inactivation of the retinoblastoma susceptibility gene in human breast cancer. *Science* 241, 218-221.
- Lianes P., Orlov I., Zhang Z-F., Oliva M., Sarkis A., Reuter V. and Cordon-Cardo C. (1994). Altered patterns of Mdm2 and Tp53 expression in human bladder cancer. *J. Natl. Cancer Inst.* 86, 1325-1330.
- Lin BT-Y., Gruenwald S., Morla A.O., Lee W-H and Wang J.Y.J (1991) Retinoblastoma cancer suppressor gene product is a substrate of

Tumor markers in bladder cancer

- the cell cycle regulator cdc kinase. *EMBO J.* 10, 857-864.
- Lipponen P. (1993). Over-expression of p53 nuclear oncoprotein in transitional cell bladder cancer and its prognostic value. *Int. J. Cancer* 53, 365-370.
- Lipponen P. and Liukkonen T. (1995). Reduced expression of retinoblastoma (Rb) gene protein is related to cell proliferation and prognosis in transitional-cell bladder cancer. *J. Cancer Res Clin. Oncol.* 121, 44-50.
- Logothetis C.J., Xu H.-J., Ro J.Y., Hu S.-X., Sahin A., Ordonez N. and Benedict W. (1992). Altered expression of retinoblastoma protein and known prognostic variables in locally advanced bladder cancer. *J. Natl. Cancer Inst.* 84, 1256-1261.
- Martin K., Trouche D., Hagemeyer C., Sorensen T.S., La Thanque N.B. and Kouzarides T. (1995). Stimulation of E2F1/DP1 transcriptional activity by MDM2 oncoprotein. *Nature* 375, 691-694.
- Moch H., Sauter G., Moore D., Mihatsch M., Gudat F. and Waldman F. (1993). p53 and erb-2 protein overexpression are associated with early invasion and metastasis in bladder cancer. *Virchows Arch. (A)* 423, 329-334.
- Moch H., Sauter G., Mihatsch M., Gudat F., Epper R. and Waldman F. (1994). p53 but not erbB-2 expression is associated with rapid tumor proliferation in urinary bladder cancer. *Hum. Pathol.* 25, 1346-1351.
- Mostofi F.K., Sobin H. and Torlini H. (1973). *Histological Typing of Urinary Bladder Tumors (International Histological Classification of Tumors, No 10)*. World Health Organization, Geneva, Switzerland.
- Rognum T.O., Brandtzaeg P. and Thorud E. (1983). Is heterogeneous expression of HLA-DR antigens and CEA along with DNA profile variations evidence of phenotypic instability and clonal proliferation in human large bowel carcinomas? *Br. J. Cancer* 48, 543-551.
- Sato K., Moriyama M., Mori Sh., Saito M., Watanuki Ts., Terada K., Okuhara E., Akiyama T., Toyoshima K., Yamamoto T. and Kato T. (1992). An immunohistologic evaluation of c-erbB-2 gene product in patients with urinary bladder carcinoma. *Cancer* 70, 2493-2498.
- Sawan A., Randall B., Angus B., Wright C., Henry J.A., Ostrowski J., Hennessy C., Lennard T.W.J., Corbett I. and Horne C.H.W. (1992). Retinoblastoma and p53 gene expression related to relapse and survival in human breast cancer: An immunohistochemical study. *J. Pathol.* 168, 23-28.
- Skopelidou A., Hadjiyannakis M., Dimopoulos D., Kamina S., Krikoni O. and Alexopoulou V., Rigas C. and Agnantis N.J (1997). p53 and c-jun expression in urinary bladder transitional cell carcinoma: Correlation with proliferating cell nuclear antigen (PCNA) histological grade and clinical stage. *Eur. Urol.* 31, 464-471.
- Soini Y., Turpeenniemi-Hujanen T., Kamel D., Autio-Harminen H., Risteli J., Risteli L., Nuorva K., Paakko P. and Vahakangas K. (1993). p53 immunohistochemistry in transitional cell carcinoma and dysplasia of the urinary bladder correlates with disease progression. *Br. J. Cancer* 68, 1029-1035.
- Stavropoulos N.E., Ioachim E., Hastazeris K., Kitsiou E., Stefanaki S. and Agnantis N.J. (1993). Growth fractions in bladder cancer defined by Ki-67: Association with cancer grade, category and recurrence rate of superficial lesions. *Br. J. Urol.* 72, 736-739.
- Thut C.J., Goodrich J.A. and Tjian R. (1997). Repression of p53-mediated transcription by MDM2: a dual mechanism. *Genes Dev.* 11, 1974-1986.
- Wagner U., Sauter G., Moch H., Novotna H., Epper R., Mihatsch M. and Waldman F. (1995). Patterns of p53, erbB-2, and EGF-r expression in premalignant lesions of the urinary bladder. *Hum. Pathol.* 26, 970-978.
- Weinberg R.A. (1991). Tumor suppressor genes. *Science* 254, 1138-1146.
- Wilson B.S., Herzig M.A. and Lloyd R.V. (1984) Immunoperoxidase staining for Ia-like antigens in paraffin embedded tissues from melanoma and lung carcinoma. *Am. J. Pathol.* 115, 102-116.
- Wright C., Thomas D., Mellon K., Neal D. and Horne C. (1995). Expression of retinoblastoma gene product and p53 protein in bladder carcinoma: correlation with Ki-67 index. *Br. J. Urol.* 75, 173-179.
- Xiao Z.X., Chen J., Levine A.J, Modjtahed N., Xing J., Sellers W.R. and Livingston D.M. (1995). Interaction between the retinoblastoma protein and the oncoprotein MDM2. *Nature* 375, 694-698.
- Zuk J. and Walker R. (1988). HLA class II sublocus expression in benign and malignant breast epithelium. *J. Pathol.* 155, 301-309.

Accepted February 18, 2000