

Microglial reaction in focal cerebral ischaemia induced by intra-carotid homologous clot injection

Y.-K. Ng and E.-A. Ling

Department of Anatomy, Faculty of Medicine, National University of Singapore, Singapore

Summary. This study examined the microglial reaction in a simulated thrombo-embolus ischaemia in rats given an intracarotid injection of a suspension of homologous blood clot. All rats including the controls receiving vehicle injection were perfused at 5 hours, and 1, 3 and 7 days post-operation. The brains were removed and processed for immunohistochemistry using a panel of monoclonal antibodies: OX-42, OX-18 and OX-6 for labeling of microglia. In rats given saline injection OX-42 immunoreactive microglial cells were observed to be distributed quite evenly throughout the whole brain. When injection of clot suspension was given, microglial cells responded vigorously, particularly in the ipsilateral hippocampus. Microglial reaction was also detected in the ipsilateral cerebral cortex, caudate as well as septal nuclei. The majority of the detected reactive microglial cells were hypertrophied showing thick or stout processes. Some rod-like and amoeboid microglia were also observed. Rarely did the reactive microglia express OX-6 immunoreactivity. All microglial cells were unreactive for OX-18. The actual mechanisms leading to the microglial activation as well as functions of reactive microglia in focal cerebral ischaemia remain speculative. In the absence of direct evidence, it could only be suggested that they may act as sensor cells for detection of subtle alterations in the microenvironment, probably in response to focal ischaemia and/or leakage of serum-derived factors induced by thrombo-embolus stroke.

Key words: Homologous clot, Focal ischaemia, Microglial reaction, Brain, Rats

Introduction

Occlusion of large cerebral arteries by electrocautery (Wu et al., 1997; Wu and Ling, 1998) and intra-arterial nylon insertion (Zhang et al., 1997b) or ligation/clamping (Zivin et al., 1995) have been the experimental models of choice for study of focal cerebral ischaemia.

Various models of thrombo-embolic induced cerebral ischaemia using foreign particles, e.g. intra-arterial injections of microspheres and air (Vise et al., 1977; Schuier et al., 1978; Zivin et al., 1995) have also been attempted. However, in actual clinical situations, cerebral stroke or transient ischaemic attack was most commonly caused by thrombo-embolism from vascular disease outside the brain (Clarke, 1994; Zivin et al., 1988). It is most likely that blood clot elements may interact with endothelial cells leading to the generation of neuro-humoral factors and subsequent pathological events (Dietrich et al., 1988). Thus the experimental animal model with induced homologous thrombo-embolic clot would be closest to the natural cause of cerebral vascular disease. In this connection, two different approaches have been adopted: 1) photochemically-induced vascular clot (Watson et al., 1985, 1987; Futrell et al., 1988; Dietrich et al., 1993); and 2) intra-arterial injection of homologous or autologous clot (Hill et al., 1955; Kudo et al., 1982; Kaneko et al., 1985; Zivin et al., 1988; Lyden et al., 1990; Zhang et al., 1997a). A hallmark of cerebral ischaemia is microglial reaction and most observations have been based on transient global ischaemic animals induced by four vessel occlusion (4-VO) (Morioka et al., 1992; Gehrmann et al., 1995; Finsen et al., 1996), a rare situation occurring in real life, if at all. Recently, some studies have shown microglial activation in focal ischaemia using the photochemically induced vasculature clot, or by occlusion of the middle cerebral artery using nylon or micromanipulator (Lehrmann et al., 1997; Zhang et al., 1997b; Schroeter et al., 1999). The present study was aimed to study the microglial response in transient focal brain ischaemia after intra-arterial injection of homologous clot. It was hoped that the procedure adopted would induce a neuropathological scenario closely simulating the likely events ensuing a cerebral stroke clinically. A better understanding of microglial reaction under such circumstances may provide useful information in studying the effects of neuroprotective drugs after ischaemia, e.g., propentofylline which has been reported to act on microglial cells (McRae et al., 1994; Wu et al., 1999).

Offprint requests to: Dr Yee-Kong Ng, Department of Anatomy, Faculty of Medicine, National University of Singapore, MD10, 4 Medical Drive, Singapore 117597. Fax: 65 - 778 7643. e-mail: antngyk@nus.edu.sg

Materials and methods

Materials

A total of 30 Wistar rats weighing between 250–300g was used in this study. Of these, 24 of them were given an injection of homologous blood clot while the remaining 6, which served as the control, received saline injection.

Surgical procedure

Following deep anaesthesia with an intra-peritoneal injection of 7% chloral hydrate (300 mg/kg), a midline incision was made at the neck. The left external jugular vein was then exposed and 20 μ l of blood were aspirated from it using a 28G syringe needle. The blood was then transferred and spread in a Petri dish and left to clot at room temperature (25 °C) for 20 minutes. The clot was then scraped from the dish and suspended in 40 μ l of saline. The clot in saline suspension was then aspirated repeatedly for a few minutes with a syringe. The left common, external and internal carotid arteries were then exposed. The external carotid artery just distal to the bifurcation of the common carotid artery was clamped with a vascular clamp. The left common carotid artery was then lifted up with a hook before a 30 μ l of embolus suspension was injected gradually into the arterial circulation using a 28G needle. After the injection, the clamp on the external carotid artery was removed. The injection site was sealed off with surgical following the withdrawal of needle. The neck incision was then closed with silk suture. The rectal temperature was monitored and maintained between 37 °C and 38 °C during the operation.

Tetrazolium staining

Six experimental rats receiving the homologous clot injection were killed at 5 hours and 1 day post-injection (each interval, n=3) with an overdose of intra-peritoneal injection of 7% chloral hydrate. Their brains were removed and cleared of all the meningeal covering. Using a brain sectioning block (Zivic Miller), the cerebrum was freshly sectioned into 1 mm thick coronal slices which were stained with tetrazolium-blue (TTZ, Sigma Co.), as was previously described by Chimon and Wong (1998). The stained sections were then fixed in 4% paraformaldehyde for storage and examined for areas of infarct.

Perfusion and tissue processing

Rats were sacrificed at 5 hours, 1, 3 and 7 days (each interval, n=6) after intra-carotid injection of clot suspension; all rats receiving saline injection were killed 1 day later. They were re-anaesthetized with 7% chloral hydrate before being perfused first with Ringer's solution followed by an aldehyde fixative composed of a mixture

of periodate-lysine-paraformaldehyde containing 2% paraformaldehyde as described previously (Ng and Ling, 1997). After perfusion the brain was removed and fixed in the same fixative for 2–4 h and was kept in 0.1M phosphate buffer containing 15% sucrose overnight at 4 °C.

Serial coronal frozen sections of the entire brain were cut at a thickness of 40 μ m and incubated in one of the following monoclonal antibodies diluted in 1:100 with phosphate buffered saline: OX-42 (SeraLab, MAS 370b), OX-18 (SeraLab, MAS 101b) and OX-6 (SeraLab, MAS 043b) monoclonal antibody for the detection of complement type 3 receptor (CR3), major histocompatibility complex (MHC) class I and II antigens on microglia, respectively. After incubation, the sections were rinsed in PBS for 15 min and later reacted in Vectastain ABC Kit (PK4002, Vector Laboratories, Burlingame, CA) against mouse IgG for half an hour in a humidified chamber. The sections were then rinsed in PBS and treated with a solution of 3-3'-diaminobenzidine tetrahydrochloride (DAB, Sigma-5637) and hydrogen peroxide (5 mg DAB, 10 ml PBS, 30 ml 0.3% H₂O₂). The sections were counterstained with 1% methyl green, dehydrated and mounted in Permount.

A total of 10 sections from each rat was also used for conventional histology staining with cresyl fast violet or haematoxylin and eosin.

Physiological variables

There were no significant differences among experimental and control groups in body temperature, heart rate or mean systolic or diastolic blood pressure monitored before and after injection of homologous clot or saline.

Results

In sections stained with TTZ, there was no obvious macroscopic sign of infarct in rats killed either at 5 hours or 1 day after intra-carotid injection of the homologous clot. In control rats given saline injection, the ubiquitous microglia with fine ramified processes were moderately stained with OX-42. There was no noticeable difference in microglial immunoreactivity between the two sides of the brain. In rats receiving clot suspension injection and being killed 1 day later, the following changes were observed in 4 of the 6 rats studied: many microglia in the cerebral cortex and hippocampus ipsilateral to the injection responded vigorously (Figs. 1a–g, 2a). OX-42-immunopositive microglia were distributed throughout the cerebral cortex, extending from the brain surface to the corpus callosum (Fig. 1b). Reactive microglia, intensely stained for OX-42, were very much more heavily populated at the CA1 and hilar regions in the ipsilateral hippocampus (Fig. 1g) when compared with the opposite side (Fig. 1f). Moderate increase in OX-42-immunoreactive microglia was also observed in the ipsilateral fornix, anterior commissure, the caudate as

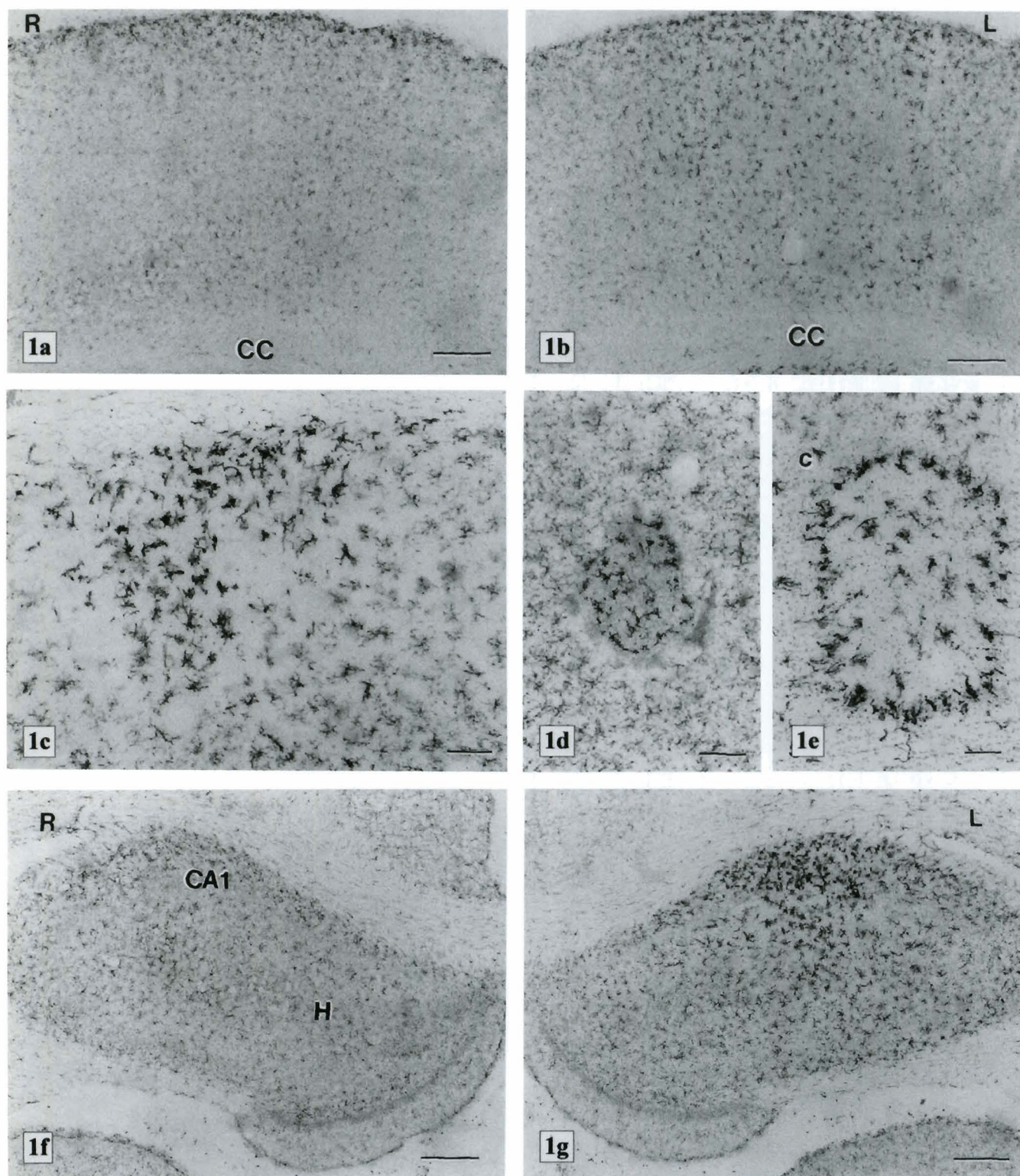


Fig. 1. a and b. Cerebral cortex contralateral (right) (R, Fig. 1a) and ipsilateral (left) (L, Fig. 1b) to the clot injection in a rat, 1 day post-injection. Many more OX-42-immunopositive microglia are distributed in the left cerebral cortex extending from the brain surface to the corpus callosum (CC). Scale bar: 300 μ m. **c.** Higher magnification of OX-42-immunoreactive microglial cells in amoeboid form in the left cerebral cortex. Scale bar: 100 μ m. **d.** A cluster of microglia intensely stained for OX-42 are seen embedded in a mass of amorphous-like substance. The cells are clearly hypertrophied compared with those at the periphery. Left cerebral cortex. Scale bar: 100 μ m. **e.** Numerous amoeboid OX-42-immunopositive microglia are seen to surround what may be a focal ischaemic lesion site in the left cerebral cortex. The lesion, which shows a paler staining compared with the rest of the tissues, contains relatively fewer cells. c: capillary. Scale bar: 100 μ m. **f and g.** Coronal sections through the cerebrum showing both the right (R, Fig. 1f) and left (L, Fig. 1g) hippocampus from a rat, 1 day after injection of homologous clot. Large numbers of OX-42-immunoreactive microglial cells are localized at the CA1 zone and hilum (H) of the left hippocampus. Scale bar: 300 μ m.

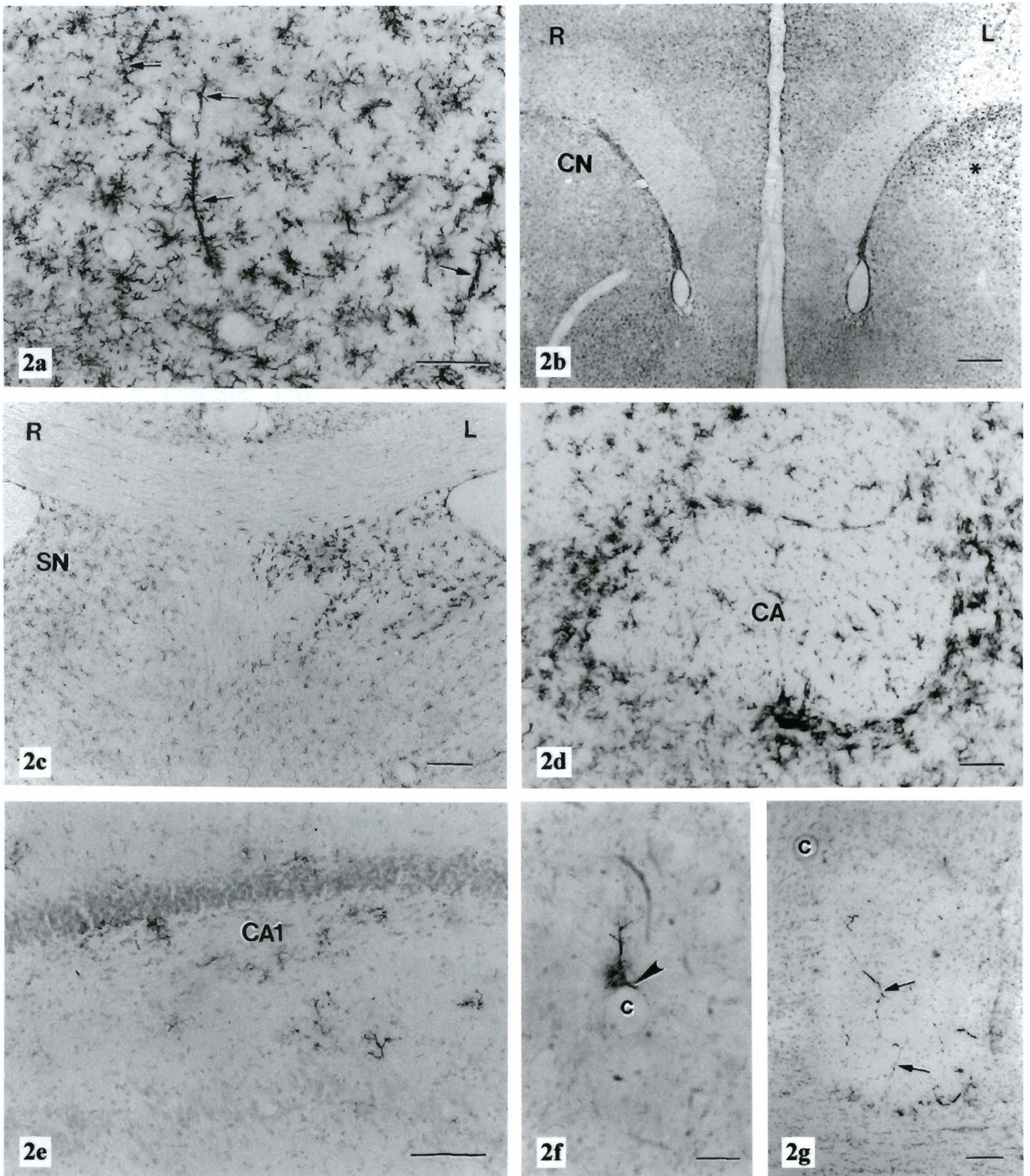


Fig. 2. **a.** Higher magnification of OX-42 microglia. They are widely distributed in the hilus of the left hippocampus. Note the occurrence of microglial rod cells (arrows). Scale bar: 100 μm . **b.** Caudate nucleus (CN) of a rat, 1 day after operation. The left (L) nucleus (*) shows more OX-42-immunopositive microglial cells. Scale bar: 200 μm . **c.** Right (R) and left (L) septal nuclei (SN), immunostained with OX-42. Many more OX-42-immunoreactive microglia are present in the left septal nucleus. Scale bar: 200 μm . **d.** Numerous OX-42-immunoreactive microglia are seen to encircle the left anterior commissure (CA). Scale bar: 200 μm . **e.** Section of the left hippocampus immunostained with OX-6. Several OX-6-immunoreactive microglia are scattered in the CA1 region. Scale bar: 100 μm . **f.** A few OX-6-immunostained microglial cells are closely associated with a blood capillary (c) in the left cerebral cortex. Processes from one of the microglia appear to make contacts with the capillary wall (arrowhead). Scale bar: 50 μm . **g.** A consecutive section of Fig. 5, showing the left cerebral cortex, immunostained for OX-18. The endothelia of some cerebral capillaries are immunoreactive for OX-18 antibody (arrows). No immunopositive microglial cell is detected. c: capillary (cf. Fig. 1e). Scale bar: 100 μm .

well as the septal nuclei (Fig. 2b-d).

The majority of the OX-42-immunoreactive cells had assumed the stage of reactive spiny microglial shape in the above-mentioned areas affected by the clot suspension injection. Furthermore, many of them were hypertrophic bearing thick or stout processes giving some of them an amoeboid appearance (Figs. 1c, 2a,d). In some areas, the reactive microglial cells appeared to transform into elongated rod cells (Fig. 2a).

An interesting feature after the clot suspension injection was the occurrence of clusters of OX-42-immunostained cells admixed with an isolated mass of amorphous-like substance (Fig. 1d). Another striking feature was the occurrence of many OX-42-stained microglia, delineating what seemed to be foci of ischaemia (Fig. 1e) which appeared to be more lightly stained than the surrounding tissues.

The above-mentioned microglial alterations, however, were not observed in rats killed at 5 hours, or 3 and 7 days after the clot injection. In these animals, the distribution of OX-42-immunoreactive microglial phenotype was comparable to that in the control rats.

Except for some immunopositive cells in the meninges and choroid plexuses, OX-6-positive cells were absent in the control rats. A small number of OX-6-positive microglia, however, were observed in the ipsilateral cerebral cortex and hippocampus of rats sacrificed at 1 day after the blood clot injection (Fig. 2e). Occasionally, the long extending microglial processes were found to be closely associated with the blood vessels or capillaries (Fig. 2f).

Except for the vascular endothelial cells, OX-18-immunoreactive cells were undetected in either the control or rats receiving the blood clot injection (Fig. 2g).

In sections stained with cresyl fast violet or haematoxylin and eosin, there was no noticeable difference in histological features in the cerebrum between the control and experimental sides. Neither was there any evidence of neurodegeneration on closer examination in areas where reactive microglia were prevalent, notably in the ipsilateral hippocampus.

Discussion

Studies of microglial reaction following induced cerebral ischaemia or infarction have been based primarily on global cerebral ischaemia induced by the 4-VO method (Schmidt-Kastner et al., 1990; Morioka et al., 1992; Jørgensen et al., 1993; Kato et al., 1994, 1995). The use of nylon monofilament cerebral vascular occlusion has also been attempted for the same purpose (Zhang et al., 1997b). These methods do not simulate actual clinical stroke in human due to thrombo-embolism originating from vascular diseases (Clarke, 1994; Zivin et al., 1988). Blood components of the thrombo-embolus, especially platelets may be partially responsible for regional cerebral ischaemia. Thus, in designing an experimental model for cerebral ischaemia

all this should be taken into consideration.

The present study has shown that microglial cells were activated mainly in the ipsilateral hippocampus. This concurs with earlier observations made in global cerebral ischaemia (Schmidt-Kastner et al., 1990; Morioka et al., 1992; Jørgensen et al., 1993; Kato et al., 1994, 1995). Along with the above, microglia in the cerebral cortex, caudate and septal nuclei as well as fornix were also activated by the ischaemic insult.

It has been reported that microglial activation in global cerebral ischaemic brain induced by the 4-VO technique occurred in a graded fashion (Schmidt-Kastner et al., 1990; Morioka et al., 1992; Jørgensen et al., 1993; Kato et al., 1994, 1995; Finsen et al., 1996). Thus, microglia were found to express an early and transient induction of increased levels of CR3 and MHC class I antigens, followed by a progressive induction of leucocyte common antigen (LCA) and ultimately MHC class II antigen. The early onset of MHC class I expression and delayed up-regulation of MHC class II antigens were also observed in other experimental CNS lesions, including nerve sectioning (Streit et al., 1989; Rao and Lund, 1989) and kainic acid or 6-hydroxydopamine injections (Akiyama et al., 1988, 1989). It was suggested that the sequential expression of MHC class I antigen followed by that of class II antigen was likely to reflect a programmed cellular response taken by microglia during their activation as a result of neuronal damage (Morioka et al., 1992; Kato et al., 1995). The expression of MHC antigens in the present study differs from that with the 4-VO-induced global cerebral ischaemia. Firstly, MHC class I antigen was not elicited in microglia in our model and, secondly, MHC class II antigen was expressed only in a subgroup of microglia 1 day after ischaemic induction in the affected areas of the brain. Expression of MHC class II antigen has also been reported 22 hours after focal ischaemia, induced by middle cerebral artery occlusion with nylon (Zhang et al., 1997b). The present results suggest that it may be more difficult to elicit MHC class I antigen by ischaemic changes induced by injection of thrombo-embolus clot. It also raises doubt the hypothesis of programmed cellular response leading to sequential expression of MHC class I and II antigens in microglia. The actual mechanisms leading to microglial activation and induction of MHC antigen expression on microglia in focal ischaemia remain uncertain, although it may be speculated that vascular damage and leakage of serum-derived factors are probably involved.

The increase in number of microglia after thrombo-embolus clot injection may be attributed to proliferation of resident microglia as has been shown recently by Postler et al. (1997) in human post-infarction brains. Postler et al. (1997) have demonstrated an actual proliferation of active microglia at the periphery of infarction up to day 3 post-infarction. Using liposomes containing dichloromethylene diphosphonate, which depletes haematogenous macrophages, Schroeter et al. (1997) showed that the initial phagocytic response after

photochemically-induced focal brain ischaemia was an intrinsic property of the nervous system mainly performed by resident microglia. However, upregulation of CR3 in microglia contributing to the numerical increase of OX-42-immunoreactive cells following clot-injection could not be ruled out.

Areas considered to be focal ischaemic lesions of different sizes were observed in some areas of the CNS. As these were absent in control rats, they must be attributed to local vascular obstruction caused by the injected emboli. Against this is the lack of obvious areas of infarct in TTZ-stained sections. A possible explanation may be that the TTZ staining was not sensitive enough to detect microscopic areas of infarct, which could have resulted with the present model. In sections stained with conventional histology methods, such as haematoxylin and eosin as well as the Nissl staining, there was no evidence of neuronal degeneration in all the experimental rats receiving embolus injection. This was also true in the ipsilateral hippocampus in which OX-42 immunoreactivity which marked the sites of CR-3 receptor of microglia was markedly upregulated. The lack of obvious infarct and neuronal degeneration in the present model differ from that reported by Lehrmann et al. (1997) and Zhang et al. (1997a). The discrepancy may be attributed to different methods used to induce the focal cerebral ischaemia. Lehrmann et al. (1997) had used micromanipulator to block the middle cerebral artery, while Zhang et al. (1997a) had injected the blood clot directly into the middle cerebral artery via a catheter. All these could have caused a more severe blockage of perfusion or ischaemia to a vast area of the brain resulting in drastic neurodegeneration.

A feature worthy of note in this study was the occurrence of clusters of activated microglia delineating the ischaemic lesion. It is suggested that they may function to protect the surrounding normal neurons from potential adverse factors that may be released from the ischaemic neurons affected by the clot injection. This is because neurons in ischaemic brain induced by middle cerebral artery occlusion have been shown to release excitatory amino acids such as glutamate and activation of N-methyl-D-aspartate (Rothman and Olncy, 1987; Collaco et al., 1994). The latter were linked to dysfunction in energy metabolism, which would eventually result in calcium overloading in neurons (Dienel, 1984; Choi, 1988).

The functional significance of microglial response in simulated thrombo-embolus-induced brain ischaemia remains unclear. Activated microglia are believed to aggravate degeneration in various CNS pathologies and experimental lesions, by secreting neurotoxic substances including oxygen radicals, nitrous oxide, glutamate and even microglia-derived tissue plasminogen activator (Colton and Gilbert, 1987; Piani et al., 1991; Zielasek et al., 1992; Giulian et al., 1993; Rogove and Tsirka, 1998). On the other hand, cytokines like interleukin-1 β and transforming growth factor (TGF)- β 1 are produced in

both focal as well as global cerebral ischaemic brains (Wiessner et al., 1993; Buttini et al., 1994; Lehrmann et al., 1995; Finsen et al., 1996). Much of the TGF- β 1 found in the ischaemic brains has been shown to be produced by activated microglia in areas of cerebral ischaemia. TGF- β 1 is known to deactivate macrophages (Tsunawaki et al., 1988), suppress microglial cytotoxicity (Merill and Zimmerman, 1991), and act as an immunosuppressive molecule (Ruscetti and Palladino, 1991). Recent evidence also shows that microglia can secrete trophic factors such as glial cell-line derived neurotrophic factor, brain-derived neurotrophic factors and the potent dopaminergic neurotrophic factor in the injured striatum (Batchelor et al., 1999). In the light of the above findings, it is suggested that the reactive microglia induced by the clot injection may be involved in similar functions but probably more in neuronal protection. This takes into consideration the fact that there was no obvious sign of cell death at various time intervals after the clot injection. It is noteworthy that while microglial reaction was drastically induced in rats killed at 1 day, it readily subsided in longer surviving rats killed at 3 and 7 days. It is suggested that the injected homologous clot could have been degraded, and hence, the ischaemic damage was only of transient nature. Another possibility may be that the microglial reaction had helped to restore and prevent further harmful damage resulting from the ischaemic insult induced by the clot injection.

Acknowledgements. This work was supported by research grants (RP 950363 and RP 970328) from the National University of Singapore. We would like to thank Mr Tajuddin b. Marican, Mrs Ng Geok Lan, and Mr Gobalakrisnan for their expert technical assistance.

References

- Akiyama H. and McGeer P.L. (1989). Microglial response to 6-hydroxydopamine-induced substantia nigra lesions. *Brain Res.* 489, 247-253.
- Akiyama H., Itagaki S. and McGeer P.L. (1988). Major histocompatibility complex antigen expression on rat microglia following epidural kainic acid lesions. *J. Neurosci. Res.* 20, 147-157.
- Batchelor P.E., Liberatore G.T., Wong J.Y., Porritt M.J., Frerichs F., Donnan G.A. and Howells D.W. (1999). Activated macrophages and microglia induce dopaminergic sprouting in the injured striatum and express brain-derived neurotrophic factor and glial cell line-derived neurotrophic factor. *J. Neurosci.* 19, 1708-1716.
- Buttini M., Sauter A. and Boddeke H.W.G.M. (1994). Induction of interleukin-1 β mRNA after focal cerebral ischaemia in the rat. *Mol. Brain Res.* 23, 126-134.
- Chimon G.N. and Wong P.T.-H. (1998). Ischemic tolerance and lipid peroxidation in the brain. *Neuroreport* 9, 2269-2272.
- Choi D.W. (1988). Calcium-mediated neurotoxicity: relationship to specific channel types and role in ischaemic damage. *Trends Neurosci.* 10, 465-469.
- Clarke C.R.A. (1994). Neurological diseases and diseases of voluntary muscle. In: *Clinical medicine*. 3rd ed. Kumar P. and Clark M. (eds).

Microglial reaction in focal cerebral ischaemia

- Baillière Tindall. London. pp 871-956.
- Collaco M.Y., Aspey B.S., Bellerocche J.S. and Harrison M.J. (1994). Focal ischaemia causes an extensive induction of immediate genes that are sensitive to MK-801. *Stroke* 25, 1855-1860.
- Colton C.A. and Gilbert G.L. (1987). Production of superoxide anions by a CNS macrophages, the microglia. *FEBS Lett.* 223, 284-28.
- Dienel G.A. (1984). Regional accumulation of calcium in postischaemic rat brain. *J. Neurochem.* 43, 913-925.
- Dietrich W.D., Prado R., Watson B.D. and Nakayama H. (1988). Middle cerebral artery thrombosis: acute blood-brain barrier consequences. *J. Neuropathol. Exp. Neurol.* 47, 443-451.
- Dietrich W.D., Prado R., Halley M. and Watson B.D. (1993). Microvascular and neuronal consequences of common carotid artery thrombosis and platelet embolization in rats. *J. Neuropathol. Exp. Neurol.* 52, 351-360.
- Finsen B., Lehmann E., Castellano B., Kiefer R. and Zimmer J. (1996). The role of microglial cells and brain macrophages in transient global cerebral ischaemia. In: *Topical issues in microglia research.* Ling E.A., Tan C.K. and Tan C. (eds). Singapore Neuroscience Association. Singapore. pp 297-318.
- Futrell N., Watson B.D., Dietrich W.D., Prado R., Milikan C. and Ginsberg M.D. (1988). A new model of embolic stroke produced by photochemical injury to the carotid artery in the rat. *Ann. Neurol.* 23, 251-257.
- Gehrmann J.B., Wiessner R.B., Hossmann K.A. and Kreutzberg G.W. (1995). Reactive microglia in cerebral ischaemia – an early mediator of tissue-damage. *Neuropathol. Appl. Neurobiol.* 21, 277-289.
- Giulian D., Vaca K. and Corpuz M. (1993). Brain glia release factors with opposing actions upon neuronal survival. *J. Neurosci.* 13, 29-37.
- Hill N.C., Millikan C.H., Wakim K.G. and Sayre G.P. (1955). Studies in cerebrovascular disease. VII. Experimental production of cerebral infarction by intracarotid injection of homologous blood clot. Preliminary report. *Mayo Clinical Proceed.* 30, 625-633.
- Jørgensen M.B., Finsen B.R., Jensen M.B., Castellano B., Diemer N.H. and Zimmer J. (1993). Microglial and astroglial reactions to ischemic and kainic acid-induced lesions of the adult rat hippocampus. *Exp. Neurol.* 120, 70-88.
- Kaneko D., Nakamura N. and Ogawa T. (1985). Cerebral infarction in rats using homologous blood emboli: Development of a new experimental model. *Stroke* 16, 76-84.
- Kato H., Kogure K., Araki T. and Itoyama Y. (1994). Astroglial and microglial reactions in the gerbil hippocampus with induced ischemic tolerance. *Brain Res.* 664, 69-76.
- Kato H., Kogure K., Araki T. and Itoyama Y. (1995). Graded expression of immunomolecules on activated microglia in the hippocampus following ischemia in a rat model of ischemic tolerance. *Brain Res.* 694, 85-93.
- Kudo M., Aoyama A., Ichimori S. and Fukunaga N. (1982). An animal model of cerebral infarction. Homologous blood clot emboli in rats. *Stroke* 13, 505-509.
- Lehrmann E., Kiefer R., Finsen B., Diemer N.H., Zimmer J. and Hartung H.-P. (1995). Cytokines in cerebral ischaemia: expression of transforming growth factor beta-1 (TGF- β 1) mRNA in the postischemic adult rat hippocampus. *Exp. Neurol.* 131, 114-123.
- Lehrmann E., Christensen T., Finsen B., Diemer N.H., Zimmer J. and Hartung H.-P. (1995). Cytokines in cerebral ischaemia: expression of transforming growth factor beta-1 (TGF- β 1) mRNA in the postischemic adult rat hippocampus. *Exp. Neurol.* 131, 114-123.
- Lehrmann E., Christensen T., Zimmer J., Diemer N.H. and Finsen B. (1997). Microglial and macrophage reactions mark progressive changes and define the penumbra in the rat neocortex and striatum after transient middle cerebral artery occlusion. *J. Comp. Neurol.* 386, 461-476.
- Lyden P.D., Madden K.P., Clark W.M., Sasse K.C. and Zivin J.A. (1990). Incidence of cerebral hemorrhage after antifibrinolytic treatment for embolic stroke in rabbits. *Stroke* 21, 1589-1593.
- McRae A., Rudolph K.A. and Schubert P. (1994). Propentofylline depresses amyloid and Alzheimer's CSF microglial antigens after ischaemia. *Neuroreport* 5, 1193-1196.
- Merrill J.E. and Zimmerman R.P. (1991). Natural and induced cytotoxicity of oligodendrocytes by microglia is inhibitable by TGF- β . *Glia* 4, 327-331.
- Morioka T., Kalehua A.N. and Streit W.J. (1992). Progressive expression of immunomolecules on microglial cells in rat dorsal hippocampus following transient forebrain ischaemia. *Acta Neuropathol.* 83, 149-157.
- Ng Y.K. and Ling E.A. (1997). Induction of major histocompatibility class II antigen on microglial cells in postnatal and adult rats following intraperitoneal injections of lipopolysaccharide. *Neurosci. Res.* 28, 111-118.
- Piani D., Frei K., Do K.Q., Cuend M. and Fontana A. (1991). Murine brain macrophages induced NMDA receptor mediated neurotoxicity in vitro by secreting glutamate. *Neurosci. Lett.* 133, 159-162.
- Postler E., Lehr A., Schluesener H. and Meyermann R. (1997). Expression of the S-100 proteins MRP-8 and MRP-14 in ischaemic brain lesions. *Glia* 19, 27-34.
- Rao K. and Lund R.D. (1989). Degeneration of optic axons induces the expression of major histocompatibility antigens. *Brain Res.* 488, 332-335.
- Rogove A.D. and Tsirka S.E. (1998). Neurotoxic responses by microglia elicited by excitotoxic injury in the mouse hippocampus. *Curr. Biol.* 8, 19-25.
- Rothman S.M. and Olney J.W. (1987). Excitotoxicity and NMDA receptor. *Trends Neurosci.* 10, 299-302.
- Ruscetti F.W. and Palladino M.A. (1991). Transforming growth factor- β and the immune system. *Prog. Growth Factor Res.* 3, 159-175.
- Schmidt-Kastner R., Szymas J. and Hossmann K.-A. (1990). Immunohistochemical study of glial reaction and serum-protein extravasation in relation to neuronal damage in rat hippocampus after ischemia. *Neuroscience* 38, 527-540.
- Schroeter M., Jander S., Huitinga I., Witte O.W. and Stoll G. (1997). Phagocytic response in photochemically induced infarction of rat cerebral cortex – the role of resident microglia. *Stroke* 28, 382-386.
- Schroeter M., Jander S., Witte O.W. and Stoll G. (1999). Heterogeneity of the microglial response in photochemically induced focal ischemia of the rat cerebral cortex. *Neuroscience* 89, 1367-1377.
- Schüier F.J., Vise W.M., Hossmann K.-A. and Zülch K.J. (1978). Cerebral microembolization. II. Morphological studies. *Arch. Neurol.* 35, 264-270.
- Streit W.J., Graeber M.B. and Kreutzberg G.W. (1989). Peripheral nerve lesion produces increased levels of major histocompatibility complex antigens in the central nervous system. *J. Neuroimmunol.* 21, 117-123.
- Tsunawaki S., Sporn M., Ding A. and Nathan C. (1988). Deactivation of macrophages by transforming growth factor- β . *Nature* 334, 260-262.
- Vise W.M., Schüier F.J., Hossmann K.-A., Takagi S. and Zülch K.J. (1977). Cerebral microembolization. I. Pathophysiological studies.

Microglial reaction in focal cerebral ischaemia

- Arch. Neurol. 34, 660-665.
- Watson B.D., Dietrich W.D., Busto R., Watchel M.S. and Ginsberg M.D. (1985). Induction of reproducible brain infarction by photochemically initiated thrombosis. *Ann. Neurol.* 17, 497-504.
- Watson B.D., Dietrich W.D., Prado R. and Ginsberg M.D. (1987). Argon laser-induced arterial photothrombosis. *J. Neurosurg.* 66, 748-754.
- Wiessner C., Gehrman J., Lindholm D., Topper R., Kreutzberg G.W. and Hossmann K.-A. (1993). Expression of transforming growth factor-beta 1 and interleukin-1 beta mRNA in rat brain following transient forebrain ischaemia. *Acta Neuropathol.* 86, 439-446.
- Wu Y.P. and Ling E.A. (1998). Induction of microglial and astrocytic response in the adult rat lumbar spinal cord following middle cerebral artery occlusion. *Exp. Brain Res.* 118, 235-242.
- Wu Y.P., Tan C.K. and Ling E.A. (1997). Expression of fos-like immunoreactivity in the brain and spinal cord of rats following middle cerebral artery occlusion. *Exp. Brain Res.* 115, 129-136.
- Wu Y.P., McRae A., Rudolphi K. and Ling E.A. (1999). Propentofylline attenuates microglial reaction in the rat spinal cord induced by middle cerebral artery occlusion. *Neurosci. Lett.* 260, 17-20.
- Zhang R.L., Chopp M., Zhang Z.G., Jiang Q. and Ewing J.R. (1997a). A rat model of focal embolic cerebral ischemia. *Brain Res.* 766, 83-92.
- Zhang Z., Chopp M. and Powers C. (1997b). Temporal profile of microglial response following transient (2h) middle cerebral artery occlusion. *Brain Res.* 744, 189-198.
- Zielasek J., Taush M., Toyka K.V. and Hartung H.-P. (1992). Production of nitrite by neonatal rat microglial cells/brain macrophages. *Cell Immunol.* 141, 111-120.
- Zivin J.A., DeGirolami U., Kochhar A., Lyden P.D., Mazzarella V., Hemenway C.C. and Henry M.E. (1995). A model for quantitative evaluation of embolic stroke therapy. *Brain Res.* 435, 305-309.
- Zivin J.A., Lyden P.D., DeGirolami U., Kochhar A., Mazzarella V., Hemenway C.C. and Johnston P. (1988). Tissue plasminogen activator. Reduction of neurologic damage after experimental embolic stroke. *Arch. Neurol.* 45, 387-391.

Accepted October 13, 2000