

Colonic endocrine cells in rats with chemically induced colon carcinoma

B. Sitohy and M. El-Salhy

Institute of Public Health and Clinical Medicine, Departments of Medicine,
Section for Gastroenterology and Hepatology, University Hospital, Umeå

Summary. Colonic carcinoma was induced in male Sprague-Dawley rats by injecting them with 1,2-dimethylhydrazine dihydrochloride. Control rats were injected with EDTA solution. Tissue specimens of colon from four groups of animals: (i) rats without tumour, (ii) with dysplasia and lymphoid hyperplasia, (iii) with colonic adenocarcinoma, and (iv) controls, were investigated. The colonic endocrine cells were detected by immunocytochemistry and quantified by computerised image analysis. Peptide YY (PYY)- and serotonin-immunoreactive cells were found in the colon of all the groups investigated. There were few somatostatin- or enteroglucagon-immunoreactive cells and no pancreatic polypeptide (PP)-immunoreactive cells in the colon of any of the groups studied. The density of PYY-immunoreactive cells increased significantly in rats with dysplasia and lymphoid hyperplasia and in rats with colon carcinoma. There was no statistically significant difference as regards cell secretory index (CSI) or nuclear area of PYY-immunoreactive cells in any of treated groups examined. Nor was there any statistically significant difference between all treated animal groups and controls, as regards cell density, CSI, or nuclear area of serotonin-immunoreactive cells. The present observations in an animal model of human colon carcinoma support the assumption that neuroendocrine peptides in the gut are involved in the carcinogenesis of colorectal carcinoma. However, The nature of the changes in the colonic endocrine cells observed here differed from those in patients with colon carcinoma, possibly due to a difference between the response of young rats to an induced colon carcinoma and a spontaneously developed carcinoma in elderly humans, or due to a species difference.

Key words: Adenocarcinoma, Colon, Computerised image analysis, Peptide YY, Serotonin

Introduction

Several neuroendocrine peptides in the gut have been reported to affect the development and growth of colorectal carcinoma (Kusyk et al., 1986; Winsett et al., 1986; Lamote and Willens, 1988; Guo et al., 1990; Narayan et al., 1990; Tausuta et al., 1990; Qin et al., 1991, 1992; Van-Tol et al., 1991; Dy et al., 1992; Gamet et al., 1992; Yoshinaga et al., 1992; Ruzniewski et al., 1993; Radulovic et al., 1994; Di-Paolo et al., 1995; Iishi et al., 1995; Stewart et al., 1995; Robbins, 1996). Thus, gastrin, neurotensin and bombesin/gastrin-releasing peptide (GRP) have been found to promote the proliferation and growth of colon cancer cells in humans and other animals (Kusyk et al., 1986; Winsett et al., 1986; Lamote and Willens, 1988; Smith and Solomon, 1988; Guo et al., 1990; Narayan et al., 1990; Tausuta et al., 1990; Alonos et al., 1992; Yoshinaga et al., 1992). In contrast, somatostatin analogues, galanin and vasoactive intestinal polypeptide (VIP), have been reported to inhibit the growth of human and rat colon cancer cells, both in xenografts and *in vitro* (Kusyk et al., 1986; Winsett et al., 1986; Lamote and Willens, 1988; Smith and Solomon, 1988; Guo et al., 1990; Narayan et al., 1990; Tausuta et al., 1990; Qin et al., 1991, 1992; Van-Tol et al., 1991; Dy et al., 1992; Gamet et al., 1992; Yoshinaga et al., 1992; Ruzniewski et al., 1993; Radulovic et al., 1994; Di-Paolo et al., 1995; Iishi et al., 1995; Stewart et al., 1995; Robbins, 1996). Consequently, recent findings of reduced somatostatin, galanin and serotonin in patients with colorectal carcinoma (El-Salhy et al., 1998a-c) and abnormal colonic levels of neuroendocrine peptides in rats with chemically-induced colon carcinoma (El-Salhy and Wilander, 1999) suggest that the neuroendocrine peptides/amines may play a significant role in colon carcinoma development and growth.

Chemically-induced colonic carcinoma in rats has been used in several studies as a model for human colon carcinoma (Habs and Schmähl, 1978; Bansal et al., 1978) and has been claimed to have histological, histochemical, ultrastructural, cytokinetic and histogenetic features similar to human neoplasm (Spjut

and Smith, 1967; Wiebeck et al., 1973; Filip, 1975; Pozhariski, 1975; Cole, 1978; Shamsuddin and Trump, 1981; Ward and Ohshima, 1985; Traynor et al., 1986; McGarrity et al., 1987; Shetye et al., 1990). The present study was undertaken to ascertain whether colonic endocrine cells are affected in this animal model, as has been described in patients with colon carcinoma (El-Salhy et al., 1998a-c).

Material and methods

Animals

Colon carcinoma was induced in 7-week-old male Sprague-Dawley rats (Møllegaard Breeding and Research Centre A/s, Denmark) weighing about 200 g, as described in details earlier (El-Salhy and Wilander, 1999). Briefly, the rats were injected s.c. once a week for 12 weeks with 21 mg/kg body weight of 1,2 dimethylhydrazine dihydrochloride (M.W. 133.2, Sigma, Stockholm) suspended in 1 ml of EDTA solution as a stabilising agent. For control purposes, 15 rats were injected s.c. with 1 ml of EDTA solution over the same period, at the end of which, all the rats were killed by exposure to CO₂. The gastrointestinal tract was dissected, rinsed in 0.9% saline solution and inspected for possible tumours. In rats with suspected tumours in the colon, tissue specimens from the colon, 3 cm from the tumour, and from proximal colon of the controls were dissected and fixed overnight in 4% buffered formaldehyde, dehydrated, embedded in paraffin wax, and cut into 5 µm-thick sections. The sections were stained with haematoxylin-eosin and van Gieson stains. The colonic endocrine cells were investigated in 8 controls, 8 treated rats without histological changes, 6 rats with colonic dysplasia and lymphoid hyperplasia, and 6 rats with colonic adenocarcinoma.

Immunocytochemistry

The sections from the colon of all animal groups were immunostained with the avidin-biotin-complex (ABC) method (Dakopatts, Glostrup, Denmark) as described earlier in detail (El-Salhy and Suhr, 1996). The primary antibodies used were anti-peptide YY (PYY), anti-pancreatic polypeptide (PP), anti-glucagon, anti-somatostatin and anti-serotonin. A detailed account

of the antisera used is given in Table 1. Specificity controls were the same as those described previously (El-Salhy and Suhr, 1996). Briefly, the sections were incubated with non-immune serum instead of the primary antibodies, or with the primary antibody pre-incubated with the corresponding or structurally related antigen.

Computerised image analysis

This was performed by the Quantimet 500MC image processing and analysis system (Leica, Cambridge, England) linked to an Olympus microscope, type BX50. The program used in this system is QWIN (Leica's Windows-based image analysis tool kit, version 1.02). In addition, the system included QUIPS (version 1.02), an interactive programming system. The slides were coded and the performer was not aware of the identity of the sections. Measurements were performed with x20 and x40 objectives. At these magnifications, each pixel of the image corresponds to 0.414 and 0.21 µm, respectively and each field in the monitor represented a tissue area of 0.04 and 0.009 mm², respectively. Measurements were made in 20 randomly chosen fields for each individual and peptide. These fields were selected from three to four sections, 50 µm apart.

The parameters measured were the number of immunoreactive cells, the area of epithelial cells, the area of immunoreactively stained secretory parts, and the nuclear area of immunoreactive cells. Using QUIPS, an automated standard sequence analysis operation was created as described earlier in detail (El-Salhy et al., 1997). Briefly, the number of the immunoreactive cells was counted using field measurements. The areas of the epithelial cells and the immunoreactively stained secretory areas were measured using a threshold setting. The data from each field were tabulated, computed and statistically analysed automatically. The section thickness was determined in the microscope by reading screw at the upper and lower section surfaces as described previously (Pinto et al., 1995). The number of various endocrine cells/mm³ of the epithelial cells was estimated as described previously (El-Salhy et al., 1997). The CSI was calculated by the previously described formula (El-Salhy et al., 1997) as follows: CSI = VS/CN, where VS = the volume of the immunoreactive area in randomly selected cells expressed in µm³, and

Table 1. Detailed account of the antisera used.

ANTISERA AGAINST	WORKING DILUTION	CODENo.	SOURCE
Synthetic polypeptide YY (PYY), (P)	1:1500	B52-1	Eurodiagnostica, Malmö, Sweden
Synthetic human pancreatic polypeptide (PP), (P)	1:1000	A619	Dakopatts, Glostrup, Denmark
Pancreatic porcine glucagon ¹ (P)	1:2500	B-31	Eurodiagnostica
Synthetic human somatostatin (P)	1:1600	A566	Dakopatts
Serotonin (M)	1:1500	M869	Dakopatts

(P): polyclonal antibodies; (M): monoclonal antibodies. ¹: specific for glucagon N-terminus and cross-reacts with both pancreatic glucagon and enteroglucagon.

CN = the number of cells measured. The nuclear areas of 10 randomly chosen cells for each individual and peptide/amine were measured using manual menu and field measurements with a x40 objective.

Statistical analysis

Comparison between treated rats and controls was performed with the Wilcoxon non-parametric test. P-values below 0.05 were considered significant.

Results

Immunocytochemistry

Numerous PYY- (Fig.1) and serotonin-immunoreactive cells were found in the colon of all the animal groups investigated. Somatostatin- and enteroglucagon-immunoreactive cells were few, which precluded all further quantification. PP-immunoreactive cells could not be detected in the colon of any animal groups studied, which agrees with previous observations (El-Salhy and Lundquist, 1984).

Computerised image analysis

The results of the morphometric analyses are shown in Fig. 2. The density of PYY-immunoreactive cells increased significantly in rats with dysplasia and lymphoid hyperplasia and in rats with colon carcinoma ($P=0.002$ and 0.02 , respectively). There was no statistically significant difference between controls and treated rats that did not develop macro- or microscopical changes regarding the PYY-immunoreactive cells. There was no statistically significant difference as regards the CSI or nuclear area of PYY-immunoreactive cells between all treated groups examined and controls. Nor was there any statistically significant difference between all the treated animal groups and controls regarding cell density, CSI or nuclear area of serotonin-immunoreactive cells.

Discussion

In the present investigation, abnormal colonic endocrine cells were observed in rats with colonic dysplasia and lymphoid hyperplasia, and with colonic carcinoma, though not in rats treated with the same carcinogen but without developing any

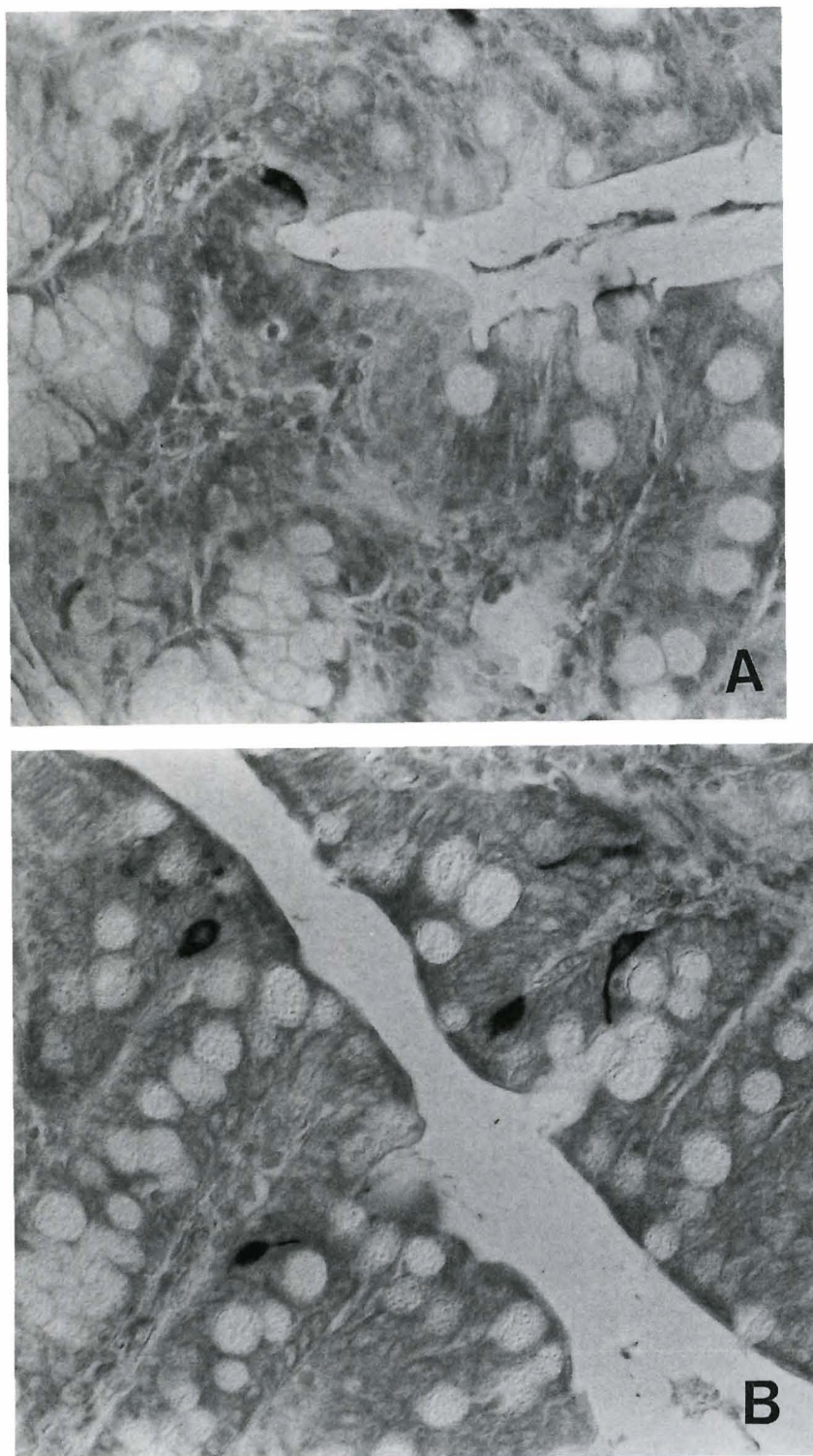


Fig. 1. PYY-immunoreactive cells in the colon of a control rat (A) and of a rat with colonic adenocarcinoma (B). x 400

Colonic endocrine cells in colon carcinoma

signs of neoplasm. This finding indicates that this alteration in colonic endocrine cells is connected with the development of carcinoma and is not an effect of the carcinogenic substance, 1,2 dimethylhydrazine dihydrochloride, on colonic endocrine cells. The present observation of high density of PYY-immunoreactive cells in the colon of rats that developed colonic dysplasia

and lymphoid hyperplasia, as well as colonic carcinoma is consistent with previous radio-immunoassay results (El-Salhy and Wilander, 1999). PYY is known for its anti-secretory effect (Rangachari, 1991), delays intestinal transit, and is considered to be one of the mediators of the ileal brake (Mannon and Talyor, 1994) The possible role played by PYY in the development of

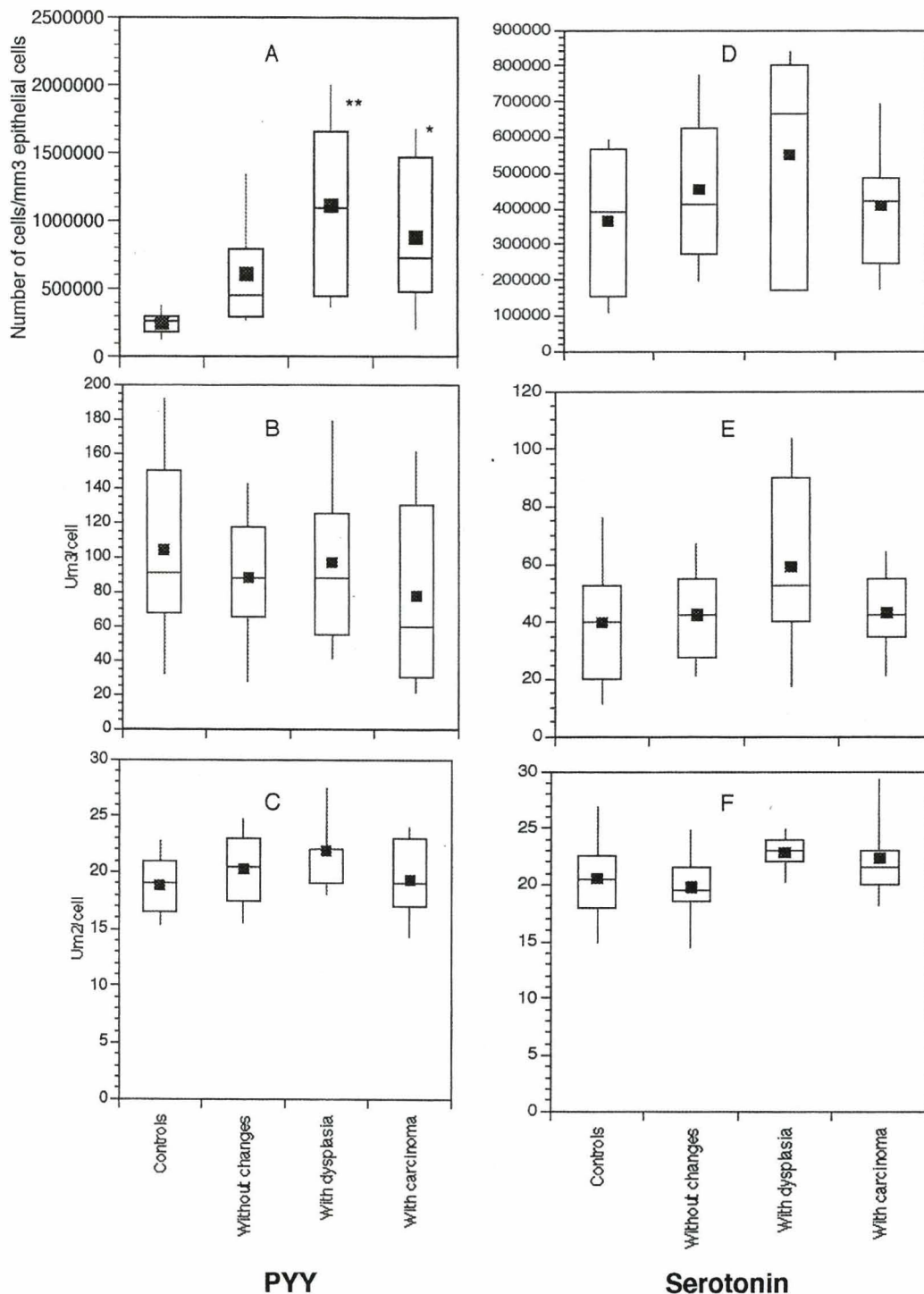


Fig. 2. Morphometric measurements of cell density (A), cell secretory index (B), and nuclear area (C) of PYY-immunoreactive cells, and cell density (D), the cell secretory index (E) and nuclear area (F) of serotonin-immunoreactive cells. The top, bottom, and line through the middle of the box correspond to the 75th percentile, the 25th percentile and 50th percentile (median). The whiskers on the bottom extend from the 10th percentile and top the 90th percentile. The black box represents the arithmetic mean. *: $p < 0.05$; **: $p < 0.01$.

colon carcinoma remains to be determined.

The present observation of abnormal colonic endocrine cells in an animal model of human colon carcinoma, together with earlier findings in the colon of patients with colon carcinoma (El-Salhy, et al., 1998a), support the assumption that neuroendocrine peptides in the gut are involved in the carcinogenesis of colorectal carcinoma (El-Salhy et al., 1998a-c). It is noteworthy, however, that the endocrine cell type and nature of the changes in the colonic endocrine cells observed here, differed from those observed in patients with colon carcinoma (El-Salhy et al., 1998a,c). Thus, whereas somatostatin- and serotonin-immunoreactive cell densities were low in the colon of patients with colon carcinoma (El-Salhy et al., 1998a), their density was not affected in rats with dysplasia and lymphoid hyperplasia, or in rats with colon carcinoma. Moreover, the density of PYY-immunoreactive cells was high in rats with dysplasia and lymphoid hyperplasia and in rats with colon carcinoma, but was unaffected in the colon of patients with colon carcinoma (El-Salhy et al., 1998a). It is worth noting that the age of rats used in this investigation was about 5 months at the end of the experiments. The 50% survival point of male Sprague-Dawley rats is 30 months and the survival dips steeply at 25 months (Kaspariet et al., 1989). Thus, the changes in the colonic endocrine cells observed in rats studied here represent a response of young rats to an induced colon carcinoma rather than a spontaneously developed carcinoma in elderly humans as reported previously (El-Salhy et al., 1998a-c). One can not, however, rule out the possibility that this was due to species differences.

Acknowledgements. This study received financial support by grants from Lion's Cancer Research Foundation, Åke Wiberg's Foundation and Sahlberg's Foundation.

References

- Alonos M., Galera M., Reyes G., Calabuig R., Vinals A. and Rius X. (1992). Effects of pentagastrin and somatostatin analog (SMS 201-995) on growth of CT26 *in vivo* adenocarcinoma of the colon. *Surg. Gynecol. Obstet.* 175, 441-444.
- Bansal B.R., Mobini J. and Bansal S.R. (1978). Multimodal immunotherapy of primary gastrointestinal tumours in rats. *Histol. Correl.* 42, 2070-2096.
- Cole J.W. (1978). Experimental carcinogenesis of colon and rectum-similarities to man. In: *Cancer campaign*. Grundman E. (ed). Gustav Fischer Verlag. Stuttgart. pp 71-78.
- Di-Paolo A., Bocci G., Innocenti F., Agen C., Nardini D., Danesi R. and Del-Tacca M. (1995). Inhibitory effect of somatostatin analogue SMS 201-995 and cytokines on the proliferation of human colon adenocarcinoma cell lines. *Pharmacol. Res.* 32, 135-139.
- Dy D.Y., Whitehead R.H. and Morris D.L. (1992). SMS 201.995 inhibits *in vitro* and *in vivo* growth of human colon cancer. *Int. J. Cancer* 52, 917-923.
- El-Salhy M. and Lundquist M. (1984). Immunocytochemical investigation of polypeptide YY (PYY) and pancreatic polypeptide (PP) in the gastrointestinal tract of three rodents. *Biochem. Res.* 5, 401-404.
- El-Salhy M. and Suhr O. (1996). Endocrine cells in rectal biopsy specimens from patients with familial amyloidotic polyneuropathy. *Scand. J. Gastroenterol.* 3, 68-73.
- El-Salhy M. and Wilander E. (1999). Colonic neuropeptides in rats with chemically induced colon carcinoma. *Gl. Cancer.* 3, 73-78.
- El-Salhy M., Sandström O., Näsström E., Mustajbasic M. and Zachrisson S. (1997). Application of computer image analysis in endocrine cell quantification. *Histochem. J.* 29, 249-256.
- El-Salhy M., Mahdavi J. and Norrgård Ö. (1998a). Colonic endocrine cells in patient with carcinoma of the colon. *Euro. J. Gastroenterol. Hepatol.* 10, 517-522.
- El-Salhy M., Norrgård Ö. and Bostrom A. (1998b). Low levels of colonic somatostatin and galanin in patients with colon carcinoma. *Gl. Cancer.* 2, 221-225.
- El-Salhy M., Norrgård Ö., Franzen L. and Forsgren S. (1998c). Colonic endocrine cells in patients with carcinoma of the rectum with special regard to preoperative irradiation. *Gl. Cancer.* 2, 285-292.
- Fillip M.I. (1975). Mucous secretion in rat mucosa during carcinogenesis induced by dimethylhydrazine. *Br. J. Cancer* 32, 60-77.
- Gamet L., Murat J.C., Remaury A., Remesy C., Valet P., Paris H. and Denis-Pouxviel C. (1992). Vasoactive intestinal peptide and forskolin regulate proliferation of HT29 human colon adenocarcinoma cell line. *J. Cell Physiol.* 150, 501-509.
- Guo Y.S., Baijal M., Jin G.F., Thompson J.C., Townsend C.M. Jr. and Singh P. (1990). Growth -promoting effects of gastrin on mouse colon cancer cells *in vitro*: absence of autocrine effects. *In Vitro Cell Dev. Biol.* 26, 871-877.
- Habs M. and Schmähl D. (1978). Experimental testing of chemotherapeutic agents in aucthonous tumours with special reference to colorectal cancer. In: *Cancer campaign*. Grundan E. (ed). Gustav Fischer Verlag. Stuttgart. pp 217-225.
- Ishii H., Tatsuta M., Baba M., Uehara H., Yano H. and Nakaizumi A. (1995). Chemoprevention by galanin against colon carcinogenesis induced by azoxymethane in wistar rats. *Int. J. Cancer* 61, 861-863.
- Kaspariet J., Deerberg F., Rapp K. and Weislo K. (1989). Mortality and tumor incidence of Han: SPRED-rats. Zentralinstitut für versuchstierzucht, Abteilung Pathologie, Hannover, BFD.
- Kusyk C.J., McNeil N.O. and Johnson L.R. (1986). Stimulation of growth of colon cancer line by gastrin. *Am. Physiol.* 251, 597-601.
- Lamote J. and Willens G. (1988). Stimulating effect of pentagastrin on cancer cell proliferation Kinetic in chemically induced colon cancer in rats. *Regul. Pept.* 20, 1-9.
- Mannon P. and Taylor I. (1994) The pancreatic polypeptide family. In: *Gut peptides*. Walsh J.H. and Dockray G. (eds). Raven Press. New York. pp 341-370.
- McGarrity T.J., Via E.A. and Colony P.C. (1987). Quantitative and qualitative changes in sialomucins during 1,2-dimethylhydrazine-induced colon carcinogenesis in rat. *J. Natl. Cancer Inst.* 79, 1375-1382.
- Narayan S., Guo Y.S., Townsend C.M. Jr and Singh P. (1990). Specific binding and growth effects of bombesin-related peptides on mouse cancer cell *in vitro*. *Cancer Res.* 50, 6772-6778.
- Pinto H., Portela-Gomes L., Kohnert K.-D., De Sousa J. and Albuquerque A. (1995). The distribution of endocrine cell types of the gastrointestinal mucosa in genetically diabetic (db/db) mice. *Gastroenterology* 108, 401-404.
- Pozhariscki K.M. (1975). Morphology and morphogenesis of experimental epithelial tumours of the intestine. *J. Natl. Cancer Inst.*

Colonic endocrine cells in colon carcinoma

- 50, 1115-1135.
- Qin Y., Schally A.V. and Willems G. (1991). Somatostatin analogue RC-160 inhibits the growth of transplanted colon cancer in rats. *Int. J. Cancer* 47, 765-770.
- Qin Y., Schally A.V. and Willems G. (1992). Treatment of liver metastases of human colon cancer in nude mice with somatostatin analogue RC-160. *Int. J. Cancer* 52, 791-796.
- Radulovic S., Schally A.V., Reile H., Halmos G., Szepeshazi K., Groot K., Milovanic S., Miller G. and Tang T. (1994). Inhibitory effects of antagonists of bombesin /gastrin releasing peptide (GRP) and somatostatin analog (RC-160) on growth of TH-29 human colon cancers in nude mice. *Acta Oncol.* 33, 693-701.
- Rangachari P. (1991). Effects of neuropeptides on intestinal ion transport. In: *Neuropeptides function in gastrointestinal tract*. Daniel E. (ed). CRC Press. Boca Raton. pp 429-446.
- Robbins R.J. (1996). Somatostatin and cancer. *Metab. Clin. Exp.* 45, 98-100.
- Ruszniewski P., Lehy T., Reyl-Desmars F., Le-Roux S. and Lewin M.J.M. (1993). Octreotide (SMS 201-995) inhibits the growth of colon peritoneal carcinomatosis in Bodix rats. *Regul. Pept.* 43, 141-147.
- Shamsuddin A.K.M. and Trump B.F. (1981). *In vitro* studies of colon carcinogenesis. Light microscopic, histochemical and ultrastructural studies of histogenesis of azoxymethane-induced colon carcinomas in Fisher 344 rats. *J. Natl. Cancer Inst.* 66, 389-401.
- Shetye J.D., Rubino C.A., Harmerenberg U., Ware J., Duvander A. and Mellstedt H. (1990). Tumour-associated antigens common to human and chemically induced colonic tumours of the rat. *Cancer Res.* 50, 6358-6363.
- Smith J.P. and Solomon T.E. (1988). Effects of gastrin, proglumide, somatostatin on growth of human colon cancer. *Gastroenterology* 95, 1541-1548.
- Spjut H.J. and Smith M.N.A. (1967). A comparative electron microscopic study of human and rat colonic polyps and carcinomas. *Exp. Mol. Pathol.* 6, 11-24.
- Stewart G.J., Connor J.L., Lawson J.A., Preketes A., King J. and Morris J.L. (1995). Octreotide reduces the kinetic index, proliferating cell nuclear antigen-maximum proliferative index, in patients with colorectal cancer. *Cancer* 76, 572-578.
- Tausuta M., Ishi H., Baba M. and Taniguchi H. (1990). Enhancement by neurotensin of experimental carcinogenesis induced in rat colon by azoxymethane. *Br. J. Cancer* 62, 368-371.
- Traynor O.J., Costa N.L. and Wood C.B. (1986). A scanning electron microscopy study of changes in rat colonic mucosa during carcinogenesis. *J. Surg. Res.* 41, 529-537.
- Van-Tol E.A., Verspaget H.W., Pena A.S., Jansen J.B., Aparicio-Pages M.N. and Lambers C.B. (1991). Modulatory effects of VIP and related peptides from gastrointestinal tract on cell mediated cytotoxicity against tumor cells *in vitro*. *Immunol. Invest.* 20, 257-267.
- Ward J.M. and Ohshima M. (1985). Comparative histogenesis and pathology of naturally occurring human and experimental induced large bowel cancer in rats. In: *Carcinoma of the large bowel and its precursors*. Mastromarino A.J. (ed). Liss Co. New York. pp 203-315.
- Wiebeck B., Krey U., Lohrs U. and M. E. (1973). Morphological and autoradiographical investigations on experimental carcinogenesis and polyp development in the intestinal tract of rats and mice. *Vichows Arch. (B)*. 360, 179-193.
- Winsett O.E., Townsend C.M.J., Glass E.J. and Thompson J.C. (1986). Gastrin stimulates growth of colon cancer. *Surgery* 99, 302-307.
- Yoshinaga K., Evers B.M., Izukura M., Parekh D., Townsend C.M. Jr and Thompson J.C. (1992). Neurotensin stimulates growth of colon cancer. *Surg. Oncol.* 1, 127-134.

Accepted May 2, 2001