

Invited Review

Enzymes involved in purine metabolism - A review of histochemical localization and functional implications

Y. Moriwaki, T. Yamamoto and K. Higashino

Third Department of Internal Medicine, Hyogo College of Medicine, Nishinomiya, Hyogo, Japan

Summary. Many enzymes are involved in the biosynthesis, interconversion, and degradation of purine compounds. The exact function of these enzymes is still unknown, but they seem to play important roles other than in purine metabolism. To elucidate their functional roles, it is imperative to clarify their tissue distribution at the cellular or subcellular level. The present review summarizes the currently available information about their histochemical localization and proposed functions.

In general, 5'-nucleotidase has been considered as a marker enzyme for the plasma membrane, and is considered to be a key enzyme in the generation of adenosine, a potential vasodilator. However, from its wide range of localization in tissues it is also considered to be related to the membrane movement of cells in the transitional epithelium, cellular motile response, transport process, cellular growth, synthesis of fibrous protein and calcification, lymphocyte activation, neurotransmission, and oxygen sensing mechanism. Adenosine deaminase (ADA) is present in all tissues in mammals. Although the main function of ADA is the development of the immune system in humans, it seems to be associated with the differentiation of epithelial cells and monocytes, neurotransmission, and maintenance of gestation. Purine nucleoside phosphorylase (PNP) is generally considered as a cytosolic enzyme, but recently, mitochondrial PNP, a different protein from cytosolic PNP, was reported. PNP is also widely expressed in human tissues. It is found in most tissues of the body, but the highest activity is in peripheral blood granulocyte and lymphoid tissues. It is also related to the development of T-cell immunity in humans as is ADA. Moreover, its contribution to centriole replication and/or regulation of microtubule assembly has been suggested. Immunohistochemical localization of xanthine oxidase has been reported in various tissues from various animal species. Xanthine oxidase has been suggested to be involved in the pathogenesis of post-ischemic reperfusion tissue injury through the generation of

reactive oxygen species, while the extensive tissue localization of xanthine dehydrogenase/oxidase suggests several other roles for this enzyme, including a protective barrier against bacterial infection by producing either superoxide radicals or uric acid. Furthermore, an involvement in cellular proliferation and differentiation has been suggested. Urate oxidase is generally considered a liver-specific enzyme, except for bovines which possess this enzyme in the kidney. Urate oxidase is exclusively located in the peroxisomes of fish, frogs, and rats, but was lost in birds, some reptiles, and primates during evolution. A histochemical demonstration of allantoin-degrading enzymes has not been performed, but these enzymes have been located in peroxisomes by sucrose density gradient centrifugation. AMP deaminase activity is higher in skeletal muscle than in any other tissues. AMP deaminase may be involved in a number of physiological processes, such as the conversion of adenine nucleotide to inosine or guanine nucleotide, stabilizing the adenylate energy charge, and the reaction of the purine nucleotide cycle. There are three distinct isozymes (A, B, C) with different kinetic, physical, and immunological properties. Isozymes A, B, C have been isolated from muscle, liver (kidney), and heart tissue, respectively. In the muscle, AMP deaminase isozymes exist in a different part, suggesting a multiple functional role of this enzyme. High hypoxanthine-guanine phosphoribosyltransferase (HGPRT) activity is found in some regions of a normal adult human brain. However, very little is known regarding the histochemical tissue localization of HGPRT. Immunohistochemical localization of its developmental expression suggests that HGPRT may not be essential for purine nucleotide supplement in the segmentation of brain cells, but may play a significant role in the developing hippocampus.

Key words: Purine metabolism-related enzymes, Tissue distribution, Histochemistry, Function

Offprint requests to: Yuji Moriwaki, M.D., Third Department of Internal Medicine, Hyogo College of Medicine, Mukogawa-cho 1-1, Nishinomiya, Hyogo 663-8501, Japan. Fax: 81-798-45-6474. e-mail: tetsuya@hyo-med.ac.jp

Introduction

There are two major pathways in purine ribo-

Enzymes of the purine metabolism

nucleotide biosynthesis and degradation (Fig. 1). One is *de novo* purine synthesis, and the other is the purine reutilizing pathway by which purine bases and nucleosides are salvaged to respective ribonucleotides. The pathway of *de novo* purine synthesis consists of 11 enzymatic reactions, forming inosine monophosphate (IMP) (Wyngaarden and Kelley, 1976). As the initial step, PRPP (5'-phosphoribosyl 1-pyrophosphate) synthetase produces PRPP, a key substrate in *de novo* purine synthesis (Wyngaarden and Kelley, 1976; Becker and Kim, 1987), from Mg-adenosine triphosphate (ATP) and ribose 5-phosphate. Then, amidophosphoribosyl-transferase catalyzes the condensation of PRPP with L-glutamine to generate phosphoribosylamine. The succeeding reactions in the *de novo* pathway are directed to the construction and closure of the purine ring (Palella and Fox, 1989). All synthesized purine compounds are ultimately derived from inosine monophosphate (IMP). Three enzymes are involved in the purine nucleotide cycle: adenosine monophosphate (AMP) deaminase,

adenylosuccinate synthetase, and adenylosuccinate lyase (Goodman and Lowenstein, 1977). AMP is recycled to IMP by the reaction of AMP deaminase. De-phosphorylation of AMP, IMP, xanthosine monophosphate (XMP), and guanosine monophosphate (GMP) is catalyzed by purine 5'-nucleotidase and nonspecific phosphatases to adenosine, inosine, xanthosine, and guanosine (Fox, 1978). Adenosine is further degraded to inosine by adenosine deaminase (ADA). Purine nucleoside phosphorylase (PNP) mainly cleaves the nucleosides inosine and guanosine to hypoxanthine and guanine, respectively. The oxidation of hypoxanthine to xanthine, and subsequently to uric acid, is catalyzed by xanthine oxidase. In humans and primates, uric acid is the end product of purine catabolism. In lower vertebrates, however, uric acid further undergoes degradation to allantoin, allantate, ureidoglycollate, urea, and finally NH_3 , by urate oxidase, allantoinase, allantoicase, ureidoglycollate lyase, and urease, respectively. The purine salvage

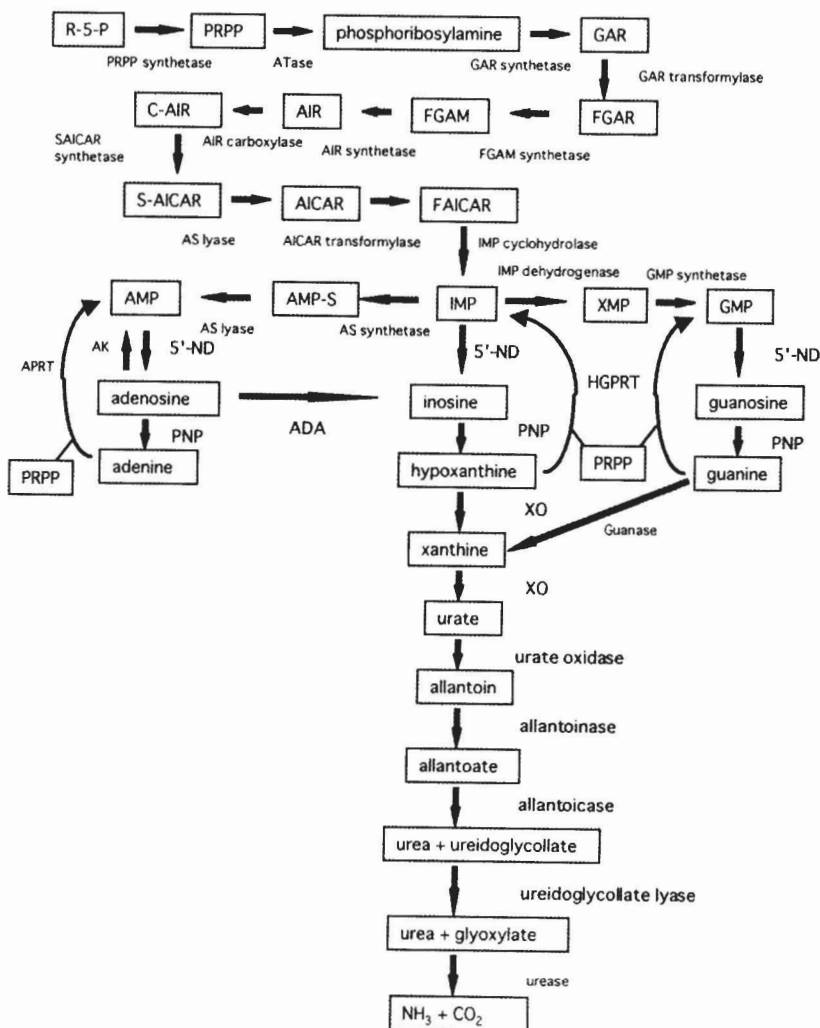


Fig. 1. Pathways in purine ribonucleotide biosynthesis, interconversion, and degradation. Abbreviations: ATase, amidophosphoribosyl-transferase; AK, adenosine kinase; APRT, adenine phosphoribosyltransferase; HGPRT, hypoxanthine-guanine phosphoribosyltransferase; 5'-ND, 5'-nucleotidase; ADA, adenosine deaminase; PNP, purine nucleoside phosphorylase; XO, xanthine oxidase; R-5-P, ribose-5-phosphate; PRPP, 5'-phosphoribosyl 1-pyrophosphate; GAR, 5'-phosphoribosylglycineamide; FGAR, 5'-phosphoribosyl N-formylglycineamide; FGAM, 5'-phosphoribosyl N-formylglycineamidine; AIR, 5'-phosphoribosyl-5-aminoimidazole; C-AIR, 5'-phosphoribosyl-5-amino-4-imidazole carboxylate; S-AICAR, 5'-phosphoribosyl-5-amino-4-imidazole-succinocarboxamide; AICAR, 5'-phosphoribosyl-5-amino-4-imidazolecarboxamide; FAICAR, 5'-phosphoribosyl-5-formamido-4-imidazolecarboxamide; IMP, inosine monophosphate; AMP, adenosine monophosphate; AMP-S, adenylosuccinate; XMP, xanthosine monophosphate; GMP, guanosine monophosphate.

pathway involves hypoxanthine-guanine phosphoribosyltransferase (HGPRT) which salvages hypoxanthine and guanine to IMP, and adenine phosphoribosyltransferase (APRT) which salvages adenine to AMP (Wyngaarden and Kelley, 1976; Arnold, 1978).

In recent years, some of the enzymes involved in purine metabolism, especially in purine nucleotide interconversion and catabolism, have been extensively investigated with regard to their structures, substrate specificities, tissue and subcellular localization/expression, molecular cloning, and regulation. Enzymes involved in purine metabolism play an important role in the different pathophysiological conditions either besides or along with purine metabolism. The aim of this article is to review the results of research currently reported on the enzyme, immunohistochemical localization of these enzymes in various tissues and species at light and electron microscopic levels, and to refer to their possible roles in several pathophysiological conditions.

5'-nucleotidase

5'-nucleotidase (EC 3.1.3.5) is a phosphatase that catalyzes the hydrolysis of 5'-phosphates of ribose and deoxyribose nucleotides to nucleoside and phosphate. 5'-nucleotidase is grouped into four forms according to their cellular location and kinetic properties: one membrane-bound form (ecto-5'-nucleotidase, e-N), a soluble form (e-Ns) derived from the GPI-anchored e-N, and two cytosolic 5'-nucleotidase forms differentiated from their affinities for AMP (cytoplasmic 5'-nucleotidase-I, c-N-I) or IMP (cytoplasmic 5'-nucleotidase-II, c-N-II) (Zimmermann, 1992). Many histochemical studies have been performed concerning the tissue localization of this enzyme, since it is considered a key enzyme in the regulation of many biological processes by generating adenosine, a potential vasodilator. 5'-nucleotidase is widely distributed throughout mammalian tissues, but most work has been concerned with the tissue localization of ecto-5'-nucleotidase.

5'-nucleotidase has been considered as a marker enzyme for the plasma membrane. 5'-nucleotidase activity has been observed on the plasma membrane of lymphocytes (Uusitalo and Karnovsky, 1977), neutrophils (Robinson and Karnovsky, 1983), cartilage cells (Rodan et al., 1977), urinary bladder epithelium of rats (Wilson and Hodges, 1979), liver epithelial and fibroblast cells (Berman et al., 1980), ventricular choroid plexus epithelial cells (Masuzawa et al., 1982), and the retina of frogs (Hussain and Baydoun, 1985) by the commonly used lead-based ultracytochemistry. In addition, 5'-nucleotidase activity has been found in the lysosomes (Masuzawa et al., 1982; Wada et al., 1987), microsomes (Widnell et al., 1972), and Golgi complex (Little and Widnell, 1975; Brandan and Fleischer, 1982) by the same method. In spite of the slightly higher inactivation of 5'-nucleotidase activity, the cerium-based method is considered to be superior to the lead-based

method because of its lower nonspecific precipitate (Blok et al., 1982; Robinson and Karnovsky, 1983). By an enzyme-histochemical method using the cerium ion technique, 5'-nucleotidase activity has been found on the plasma membrane of all bladder transitional epithelial cells, including the free surface of superficial cells, suggesting that 5'-nucleotidase present on the luminal surface of superficial cells plays a special role in the membrane movement of these cells in the transitional epithelium by accelerating actin polymerization (Zhang et al., 1991). 5'-nucleotidase activity has also been shown in murine peritoneal resident macrophage (Blok et al., 1982). In the rat liver, 5'-nucleotidase activity has been observed in the canalicular and sinusoidal plasma membranes and was found to be higher in the pericentral than the periportal areas (Frederiks et al., 1988). 5'-nucleotidase might function in association with the production of adenosine, permeability of the plasma membrane, and regulation of glycolysis (Masuzawa et al., 1982). Also, ecto-5'-nucleotidase may act as an anchoring protein for intercellular actins, and modify their availability for cellular motile response (Rohr and Mannherz, 1979). 5'-nucleotidase is also related to the transport process (Gartner et al., 1978), cellular growth (Hardonk and Koudstaal, 1968a,b), synthesis of fibrous protein, calcification (Gibson and Fullmer, 1967), and lymphocyte activation (Thompson et al., 1987). 5'-nucleotidase is immunolocalized in the nervous system. 5'-nucleotidase is distributed heterogeneously within areas of the brain. Kaur et al. (1984) localized 5'-nucleotidase activity in microglial cells in the rat brain, while Schubert et al. (1979) localized the enzyme in the rat hippocampus. 5'-nucleotidase activity was also localized in glial cells and the main types of asymmetrical synapses in the developing and mature cerebellum of the mouse (Bailly et al., 1995). Thus, 5'-nucleotidase appears as a marker of glia and Purkinje cell synapses across cerebellar compartments. The presence of 5'-nucleotidase in brain tissue suggests that it may take part in the catabolism of nucleic acid and in the process of neurotransmission (Schubert et al., 1979). Schoen et al. (1993), using enzyme cytochemistry, demonstrated the redistribution of 5'-nucleotidase from synaptic to glial localization during the developmental period in the cat visual cortex, and suggested another role of this enzyme besides synaptic malleability. Changes in purinergic neuromodulation and/or cell adhesion by 5'-nucleotidase might take part in the functional differentiation of the visual cortex. In the peripheral nervous system, 5'-nucleotidase is localized in the Schwann-cell membrane (Grondal et al., 1988). In the kidney and liver, both 5'-nucleotidase and erythropoietin were found to be localized in renal peritubular cells and Ito cells, in which cytochrome *b₅₅₈* a putative oxygen sensor protein, is also contained (Bachmann and Ramasubbu, 1997). Ecto-5'-nucleotidase activity in the liver was slightly higher in the pericentral zone than in the periportal zone. In addition, anemia exaggerates this gradient (Schmid et

Enzymes of the purine metabolism

al., 1994). From these observations, it was suggested that 5'-nucleotidase is involved in the oxygen sensing mechanism *via* a hydrolysis of AMP to adenosine, stimulating erythropoietin synthesis. 5'-nucleotidase is also present in peritubular luminal membranes, fibroblasts (in the cortical labyrinth), mesangial cells, and lymph capillaries (Le Hir and Kaissling, 1989; Gandhi et al., 1990; Bachmann and Ramasubbu, 1997). Both the activity and protein of ecto-5'-nucleotidase were highest in the P₁ segment of the brush border of the proximal tubules (Dawson et al., 1989). 5'-nucleotidase is presumed to play a role in the tubules in the salvage of nucleotides present in the primary urine (Le Hir and Kaissling, 1993). The existence of 5'-nucleotidase-positive fibroblasts in the vicinity of blood capillaries suggests a possible role of these cells in inflammatory processes, in addition to the delivery of adenosine to target cells. Immuno-gold electron microscopy of dog heart tissue showed that cytosolic, not an ecto-5'-nucleotidase, is localized in cardiac myocytes and

endothelium, but not in the plasma membrane and interstitium (Darvish et al., 1993). Borgers and Thoné (1992) localized 5'-nucleotidase activity at the pericyte plasma membranes in the left ventricular myocardium of humans, dogs, pigs, rabbits, guinea pigs and rats. However, its activity in cardiac muscle cells was present only in the rat tissue. Endothelial cells were only reactive to rat 5'-nucleotidase. The failure of Borgers and Thoné (1992), and Rubio et al. (1973), to detect 5'-nucleotidase in the myocardium and endothelial cells may be ascribed to the lead nitrate staining that they used, since lead nitrate is a potent inhibitor of cytosolic 5'-nucleotidase (Darvish et al., 1993). Yokota et al. (1988), using an antibody against cytosolic 5'-nucleotidase (c-N-II), investigated the localization of 5'-nucleotidase by light and electron microscopy in chicken livers, and demonstrated its localization in the cytoplasmic matrix of parenchymal cells, Kupffer cells, and endothelial cells, but not in cell organelles, such as mitochondria, endoplasmic reticulum, peroxisome, or

Table 1. Histochemical tissue demonstration of 5'-nucleotidase at cellular and subcellular levels in various species.

SPECIES	TISSUE LOCALIZATION	CELLULAR OR SUBCELLULAR LOCALIZATION	METHOD	REFERENCE
Rat	liver	microsome	EH (EM)	Widnell et al., 1972
Rat	liver	Golgi complex	EH (EM)	Little and Widnell, 1975; Brandan and Fleischer, 1982
Mouse	lymphocyte	plasma membrane	EH (EM)	Uusitalo and Karnovsky, 1977
Chicken embryo	epiphyseum	cartilage cell	EH (EM)	Rodan et al., 1977
Rat	urinary bladder	epithelium	EH (EM)	Wilson and Hodges, 1979
Rat	brain	hippocampus	silver impregnation	Schubert et al., 1979
Rat	choroid plexus	epithelial cell	EH (EM)	Masuzawa et al., 1982
Rat	liver	lysosome	EH (EM)	Masuzawa et al., 1982; Wada et al., 1987
Mouse	macrophage	plasma membrane, cell-surface invagination	EH (EM)	Blok et al., 1982
Guinea pig	neutrophil	plasma membrane	EH (EM)	Robinson and Karnovsky, 1983
Frog	retina	inner retinal layer plasma membrane of Muller cell process	EH (LM) EH (EM)	Hussain and Baydoun, 1985
Chicken	liver heart small intestine	sinusoidal cell, bile canalicular region vascular system enterocyte	IH (LM)	Heidemann et al., 1985
Rat	liver	canalicular and sinusoidal plasma membrane	EH (LM)	Frederiks et al., 1988
Chicken	liver	parenchymal cell, Kupffer cell, endothelial cell	IH (LM, EM)	Yokota et al., 1988
Electric ray	electric organ	Schwann cell	IH (EM)	Grondal et al., 1988
Rat	kidney	lymphatic capillary	IH (LM, EM)	Le Hir and Kaissling, 1989
Human, dog, pig, Guinea pig, rat	heart	pericyte	EH (EM)	Borgers and Thoné, 1992
Dog	heart	myocyte, endothelium	IH (EM)	Darvish et al., 1993
Mouse	brain (cerebellum)	glia, Purkinje cell	EH (EM)	Bailly et al., 1995
Rat	kidney	peritubular cell, fibroblast, mesangial cell	fluorescence, IH (LM)	Bachmann and Ramasubbu, 1997; Gandhi et al., 1990;
Rat	liver	Ito cell	fluorescence	Bachmann and Ramasubbu, 1997

EH: enzyme histochemistry; IH: immunohistochemistry; EM: electron microscopy; LM: light microscopy; ISH: *in situ* histochemistry.

nuclei. Heidemann et al. (1985) also demonstrated the localization of 5'-nucleotidase in chicken liver (sinusoidal cell), heart (vascular system), and small intestine (enterocyte). Corte-Real et al. (1993) examined 5'-nucleotidase in *Leishmanias* species by immuno-gold labeling and cerium cytochemistry, and demonstrated that it was localized at the surface of the cell body, the flagellum, and the flagellar pocket membrane, the results suggesting that *Leishmanias* possess mechanisms capable of hydrolyzing nucleotide monophosphates. Periplasmic 5'-nucleotidase of bacteria is considered to be involved in the supply of carbon for the cell (Bengis-Garber and Kushner, 1981). Plant cytosolic 5'-nucleotidase probably serves in the metabolism of cytokinin (Burch and Stuchbury, 1986), as well as regulation of the nucleotide pool size (Carter and Tipson, 1986).

As to the usefulness of 5'-nucleotidase in clinical medicine, Hilton et al. (1991), using an enzyme-histochemical method, investigated the localization of 5'-nucleotidase activity in muscle biopsy specimens of various inflammatory muscle diseases, demonstrating an extensive interstitial reaction associated with inflammatory infiltrates. From the results, they suggested that 5'-nucleotidase is useful for the diagnosis of inflammatory muscle diseases. Enzyme histochemistry of 5'-nucleotidase has been utilized to diagnose malignancy (Magnusson et al., 1974; Wilson and Hodges, 1979). Invernizzi et al. (1990) studied the distribution of 5'-nucleotidase in B cell leukemia by enzyme histochemistry and suggested the usefulness of this enzyme as a maturation marker in chronic B cell leukemia. These studies suggested that 5'-nucleotidase is a useful marker for transformation. 5'-nucleotidase is more specific than alkaline phosphatase in the diagnosis of hepatobiliary diseases. Therefore, it is widely used in examinations for hepatobiliary diseases. The tissue distribution and pathophysiological roles of 5'-nucleotidase are summarized in Tables 1 and 7.

Adenosine deaminase (ADA)

Adenosine deaminase (ADA, EC 3.5.4.4) is an enzyme catalyzing the conversion of adenosine and deoxyadenosine to inosine and deoxyinosine respectively. ADA is present in all tissues in mammals. ADA activity is high in the spleen and duodenum, while it is low in the blood, brain, muscle, pancreas, and testis in the rat, guinea pig, mouse, cat, rabbit, dog, and calf (Brady and O'Donovan, 1965). In humans, the highest activity has been found in the thymus (Adams and Harkness, 1976) or spleen (Van der Weyden and Kelley, 1976), while in mice, the highest levels of ADA are present in the proximal small intestine (Mohamedali et al., 1993). In the rat, high activities are found in the lung, spleen, and intestine (Centelles et al., 1987). Chechik et al. (1981), using anti-human ADA antisera, localized this enzyme in human thymus and tonsil tissue, lymphocytes, and several hematopoietic cell lines

immunohistochemically. ADA was seen predominantly in the cortex of the thymus, but it was not observed in the bone marrow nuclear cells. Chechik and SenGupta (1981) showed that anti-calf ADA can be used for the immunohistochemical localization in rat, human, and mouse tissue. Then, Chechik et al. (1983), using an anti-calf ADA polyclonal antibody, also localized this enzyme immunohistochemically in the tissues of rats as well as calves, and demonstrated a similar tissue distribution of ADA in both species. ADA was distributed in the lymphoid system, such as the thymus gland, spleen, and lymph node, but the distribution was uneven in these tissues. ADA-positive cells were predominantly seen in the red pulp of the spleen, medullary region of the lymph node, and cortical region of the thymus, consistent with the results of Barton et al. (1979) who showed that high ADA activity was preferentially associated with cortical thymocytes. In the peripheral lymphoid tissues, T cells have a higher ADA activity than B cells (Sullivan et al., 1977). In addition, immunoreactivity was observed in the lamina propria of the intestine, the mononuclear interstitial cells of the kidney, heart, and lung, and in endothelial cells, Kupffer cells, and bile canaliculi of the liver. However, ADA was not stained in hepatocytes of these species. In the heart, ADA has been localized in the endothelium and interstitial cells of rats and calves (Chechik et al., 1983). Schrader and West (1990) also demonstrated the presence of this enzyme in arteriolar, capillary and venular endothelium, and in pericytes of the rabbit heart. So far, the role of pericytes has been underestimated, but the presence of ADA and/or 5'-nucleotidase suggests a possible role of pericytes in the metabolism of adenosine. ADA is considered to be a cytosolic enzyme. However, immunological studies by light and electron microscopy using an anti-calf ADA polyclonal antibody demonstrated that ADA is localized in the external side of the plasma membrane of erythrocytes, lymphocytes, monocytes, and platelets in humans (Franco et al., 1990; Aran et al., 1991). Flow cytometric assay enables us to quantitate ADA expression in single cells (SenGupta et al., 1985), and it is expected to be utilized in the characterization of subpopulations of normal cells. Cellular and subcellular localization of ADA in the brain was investigated in the rat, guinea pig, mouse, and rabbit, demonstrating variations in the cellular localization of ADA among animal species (Yamamoto et al., 1987). ADA was detected in oligodendroglia and in endothelial cells lining blood vessels in the rabbit cerebrum, brain stem, and cerebellum (Schrader et al., 1987). The results suggest that these cells might play a role in controlling the extracellular adenosine concentration by ADA. An *in situ* histochemistry of mice tissues demonstrated ADA mRNA in the epithelia of the tongue, esophagus, forestomach, and duodenum, as well as in the decidua (Witte et al., 1991).

The pathophysiological role of ADA is presumed from its deficiency and adenosine degradation. ADA plays an important role in the development of the

immune system in humans and its deficiency is associated with severe combined immunodeficiency (Giblett et al., 1972; Cohen, 1975). The main function of ADA in lymphocytes appears to be protection of these cells from the toxic effects of high concentrations of adenosine and deoxyadenosine (Cohen et al., 1978; Fox and Kelley, 1978). Moreover, ADA seems to be associated with the differentiation of epithelial cells (Trotta and Balis, 1977) and monocytes (Fischer et al., 1976), neurotransmission (Nagy et al., 1984), and maintenance of gestation (Mohamedali et al., 1993). Besides lymphoid tissues, ADA is ubiquitously localized in such tissues as the liver, kidney, lung, and digestive tracts in humans (Moriwaki et al., unpublished). The ubiquitous localization of this enzyme may be considered in view of adenosine removal. The localization of ADA in the absorptive area of the digestive tract suggests a mechanism for removal of adenosine entering the body from the digestive tract. ADA in the liver may play a role in the removal of adenosine from blood derived from the gut, so that tissues fed *via* the circulatory system, except the portal vein, would not be affected by an excessive concentration of adenosine. ADA in the lung may contribute to the metabolism of adenosine before entering the heart. In clinical medicine, the measurement of the level of ADA in the pleural fluid is of value in the differential diagnosis of tuberculous from carcinomatous pleuritis (Moriwaki et al., 1989). It has been suggested that ADA and adenosine play a key role on the pathological conditions such as asthma (Ronchetti et al., 1984) and anoxia (Stefanovich, 1982). The tissue distribution and pathophysiological roles of ADA are summarized in Tables 2 and 7.

Purine nucleoside phosphorylase (PNP)

Purine nucleoside phosphorylase (PNP, EC 2.4.2.1) is the enzyme next to ADA in the purine catabolic pathway. PNP catalyzes the reversible reaction of purine nucleosides and inorganic phosphate to the corresponding purine bases and ribose-1-phosphate. PNP is a trimer of approximately 90,000 daltons. PNP is a cytoplasmic enzyme, and is found in a variety of organisms, both procaryotic and eucaryotic. However, recently PNP was also found in bovine liver mitochondria (Haag and Lewis, 1994). From its several unique properties, it is considered to be a different protein from cytosolic PNP. PNP has been localized cytochemically in only a limited number of tissues. PNP is widely expressed in human tissues, but the activity varies from tissue to tissue. The highest activity is in peripheral granulocytes (Carson et al., 1977). Peripheral lymphocytes also have high PNP activity. Rubio et al. (1972) developed an electron microscopic method for the localization of PNP activity using lead ion. Since then, PNP has been demonstrated as an enzyme, histochemically, and localized in the capillary endothelium of the heart (Rubio et al., 1972; Berne and Rubio, 1974; Borgers and Thone, 1992), lung (Mentzer et al., 1975), brain (Rubio et al., 1978), and liver (Rubio, 1974). In the liver, Kupffer cells are also very active, while liver parenchymal cells have lesser activities (Rubio and Berne, 1980). However, the method advocated by Rubio et al. (1972) requires tissue fixation and lead ion, which inhibit PNP activity. Therefore, Frederiks et al. (1993) developed a procedure for the localization of PNP activity using tetranitro BT and xanthine oxidase as an auxiliary enzyme, and they demonstrated that the pericentral hepatocyte showed a

Table 2. Histochemical tissue demonstration of ADA at cellular and subcellular levels in various species.

SPECIES	TISSUE LOCALIZATION	CELLULAR OR SUBCELLULAR LOCALIZATION	METHOD	REFERENCE
Human	thymus tonsil	cortical region	IH (LM) IH (LM)	Chechik et al., 1981
Rat, calf	thymus spleen lymph nodes intestine kidney, heart, lung liver	cortical region red pulp medullary region lamina propria mononuclear interstitial cell endothelial cells, Kupffer cells, bile canaliculi	IH (LM)	Chechik et al., 1983
Rabbit	cerebrum, brain stem, cerebellum	oligodendroglia, endothelial cells	IH (LM)	Schrader et al., 1987
Rabbit	heart	vascular endothelium, pericytes	IH (LM)	Schrader and West, 1990
Human	RBC, lymphocytes, monocytes, platelet	plasma membrane	IH (LM, EM)	Franco et al., 1990; Aran et al., 1991
Mouse	tongue, esophagus, forestomach, duodenum decidua	epithelium (squamous, villi) capsularis cell, spongiorhoblastic layer, decidua basalis	ISH	Witte et al., 1991
Mouse	tongue, esophagus, forestomach, small intestine, decidua		immunoblotting	Mohamedali et al., 1993

Abbreviations are the same as in Table 1.

higher PNP activity than the periportal hepatocyte. Borgers and Thoné (1992) examined the localization of PNP activity in the heart of humans, dogs, pigs, rabbits, guinea pigs, and rats. PNP activity was present in the pericytes as well as vascular endothelium. In addition, PNP activity was positive in human, dog, guinea pig, and rat nerve cells. However, PNP activity was absent in myocardial cells or smooth muscle cells, being consistent with the results reported by Rubio and Berne (1980) using rats and guinea pigs. RBC was unreactive to PNP in dog, guinea pig and rat tissue. Immunofluorescence microscopy using a polyclonal antibody to human PNP and ultrastructural enzyme cytochemistry localized PNP to the cytoplasm of lymphoblasts and fibroblasts (Pruslin and Reem, 1980), the centrioles and cytoplasm of leukocytes (human), and basal bodies of ciliated epithelium (mouse, *Tetrahymena*) (Oliver et al., 1981). The localization of PNP to centriole and basal bodies over a broad phylogenetic range suggests the possible role of purine metabolism in the function of microtubule organizing centers; that is centriole replication and/or regulation of microtubule assembly. Borgers et al. (1977) described PNP in human leukocytes as confined to cytosol, except for the centriole. They proposed cytosolic PNP as a possible marker for T-cells. Supporting this connotation, Itoh et al. (1984), using an immunohistochemical method, localized PNP in T cells, but not in B cells. PNP is considered to be essential for normal T cell function, and its deficiency is associated with severely defective T cell immunity (Giblett et al., 1975; Stoop et al., 1977; Markert, 1991). In contrast, Oliver et al. (1981) observed that no consistent pattern of PNP staining intensity was linked to a particular class of leukocytes. The localization of PNP in the brain was confined to both astroglial and

microglial cells, while neurons were negative for the localization of this enzyme in a normal adult rat brain (Castellano et al., 1990). Astrocytes in the rat brain showed a pronounced PNP activity, while those in a guinea pig showed a weak activity (Van Reempts et al., 1988). The tissue distribution and pathophysiological roles of PNP are summarized in Tables 3 and 7.

Xanthine oxidase

Xanthine oxidase (EC 1.2.3.2) is the final enzyme that catalyzes the conversion of hypoxanthine to xanthine, and subsequently to uric acid in humans, anthropoid apes, and birds. Unlike other oxidases, xanthine oxidase exists in two forms: a NAD⁺-dependent dehydrogenase form and an oxygen-dependent oxidase form. Xanthine oxidase can be converted to xanthine dehydrogenase, and vice versa. Tissue localization of xanthine oxidase has been extensively investigated, since it has been suggested to be involved in the pathogenesis of post-ischemic reperfusion tissue injury through the formation of free radicals (McCord, 1985). Immunohistochemical localization of xanthine oxidase has been reported in various tissues from various animal species. Some of them were reviewed by Kooij (1994) and Moriwaki et al. (1997). In bovine tissues, xanthine oxidase was detected in milk-secreting epithelial cells and capillary endothelial cells of the mammary gland, liver sinusoid, heart, lung, intestine, and skeletal muscles, but not in the epithelial cells of the intestine, hepatocyte, or brain (Bruder et al., 1983). In the chicken liver, Hattori (1989) reported the localization of xanthine dehydrogenase (chickens have only xanthine dehydrogenase) in the hepatocytes, Kupffer cells, and endothelial cells lining

Table 3. Histochemical tissue demonstration of PNP at cellular and subcellular levels in various species.

SPECIES	TISSUE LOCALIZATION	CELLULAR OR SUBCELLULAR LOCALIZATION	METHOD	REFERENCE
Rat, human, pig	heart	capillary endothelium	EH (EM)	Berne and Rubio, 1974; Rubio et al., 1972; Borgers and Thone, 1992
Guinea pig	liver	capillary wall	EH (EM)	Rubio, 1974
Rat, dog, guinea pig	lung	endothelial cell	EH (EM)	Mentzer et al., 1975
Rat	brain	capillary endothelium	EH (EM)	Rubio et al., 1978
Guinea pig, rat	heart kidney liver	endothelial cell microvilli of proximal tubules Kupffer cell	EH (EM)	Rubio and Berne, 1980
Human	leukocyte	centrioles, cytoplasm	IH (fluorescent)	Oliver et al., 1981
Mouse, <i>Tetrahymena</i>	ciliated epithelium	basal body	EH (EM)	
Rat	brain	astroglial, microglial cells	EH (LM)	Castellano et al., 1990
Human, dog, guinea pig, rat, pig	heart	pericyte, vascular endothelium, nerve cell	EH (EM)	Borgers and Thone, 1992
Mouse	small intestine, liver		immunoblotting	Mohamedali et al., 1993
Bovine	liver	mitochondria	biochemical	Haag and Lewis, 1994

Abbreviations are the same as in Table 1.

the hepatic sinusoids. In rats, immunohistochemical localization of xanthine oxidase has been only rarely investigated, except for in the liver. However, Moriwaki et al. (1996a) recently demonstrated the ubiquitous localization of this enzyme in rat tissues other than the liver, such as a strong staining in the renal tubules, as well as in esophageal, gastric, and small and large intestinal and bronchial epithelia. Positive staining was also found in the adrenal gland, skeletal muscle, spleen, and cerebral hippocampus. In humans, Hellsten-Westing (1993) observed the immunoreactivity of this enzyme in vascular smooth muscle cells, endothelial cells of the capillaries and of the smaller vessels in the cardiac and skeletal muscle, as well as in macrophage and mast cells. Xanthine oxidase was detected in sinusoidal and capillary endothelial cells in cryostat sections of the liver, heart, kidney, and placenta (Bruder et al., 1984). Moriwaki et al. (1996b) also demonstrated the ubiquitous localization of this enzyme in human tissues, such as an intense reactivity in surface epithelia of the tongue, esophagus, trachea, sweat glands, and mammary glands; and weak but positive reactivity in the glandular cells of the small and large intestine and renal tubules, skeletal muscle, gastric epithelial cells, alveoli of the lung, spleen, and liver cytoplasm.

Ultrastructural localization of xanthine oxidase has been studied by many investigators. However, the results of subcellular localization of xanthine oxidase in the liver peroxisomes are conflicting. Angermuller et al. (1987), using a cerium ion capturing method, reported the localization of xanthine oxidase activity in the endothelial cell cytoplasm and crystalline cores of peroxisomes in rat hepatocytes. Dikov et al. (1988), using a ferricyanide reduction method, localized the enzyme activity in the limiting membrane and the matrix of peroxisomes in rat hepatocytes. However, these authors did not detect any xanthine oxidase activity in the hepatocytes. Moreover, in their studies the possibility that uric acid produced by xanthine oxidase serves as a substrate for urate oxidase was not excluded. In contrast, Ichikawa et al. (1992), using an anti-rat liver xanthine oxidase antibody and protein A-gold, investigated the subcellular localization of xanthine oxidase in rat hepatocytes, and reported labeling over the cytosol but not on the cell organelles, such as the endoplasmic reticulum, Golgi complex, lysosomes, or peroxisomes. Immunoelectron microscopically, Jarasch et al. (1981) using an antibody to xanthine oxidase obtained from the bovine milk lipid globule, also demonstrated the localization of this enzyme in the cytoplasm of capillary endothelial cells in the bovine liver and endothelial cells from the lactating mammary gland. Samra et al. (1991) were the first to demonstrate the presence of xanthine oxidase in the interstitial cells and endothelial cells of rat myocardial small vessels. As to the mode of existence of xanthine oxidase in the capillary endothelium, Adachi et al. (1993) suggested that xanthine oxidase is bound to the capillary endothelium *via* sulphated glycosaminoglycans.

Enzyme histochemistry using a tetrazolium salt reduction method has demonstrated the localization of xanthine dehydrogenase in various tissues such as the liver, kidney, and intestine of several vertebrates. Xanthine dehydrogenase activity has been detected in the fixed (Sackler, 1966) and unfixed frozen sections by the tetrazolium reduction method, with hypoxanthine as a substrate. In the enzyme histochemistry of xanthine dehydrogenase/oxidase, specific inhibitors of xanthine dehydrogenase/oxidase, and the use of unfixed frozen sections and polyvinyl alcohol as a tissue protectant, are desirable to avoid inactivation or loss in the solution. In rats, Kooij et al. (1992b), using a tissue protectant, demonstrated the ubiquitous localization of xanthine dehydrogenase activity, such as in the epithelium of the skin, vagina, uterus, penis, liver, oral and nasal cavities, tongue, esophagus, forestomach, small intestine, and adrenal cortex, as well as in endothelial cells. McIndoe et al. (1974) demonstrated xanthine dehydrogenase activity in the liver (hepatocytes), kidney (epithelium), pancreas (acinar cells), and small intestine (epithelium) of chickens. In human tissues, Auscher et al. (1980) detected xanthine oxidase activity in the epithelial villi of the duodenum and jejunum, but not in the large intestine or rectum. Kooij et al. (1992a) also demonstrated xanthine oxidase activity only in the liver and jejunum, the result being consistent with the biochemical data. Previously, allopurinol was used as an inhibitor of the enzyme histochemistry for xanthine dehydrogenase/oxidase. However, allopurinol is not only an inhibitor, but also a substrate for xanthine oxidase (Moriwaki et al., 1993). Therefore, the use of more specific inhibitors of xanthine oxidase such as BOF-4272 (Sato et al., 1991) or TEI-6720 (Osada et al., 1993) is preferable for this purpose. Moriwaki et al. (1998), using TEI-6720 as an inhibitor of xanthine oxidase, clearly demonstrated its activity in the rat liver, kidney, stomach, small and large intestine, adrenal gland, tongue, and lung. The disparity between the immunohistochemical (Bruder et al., 1984; Hellsten-Westing, 1993; Moriwaki et al., 1996b) and enzyme histochemical results of the localization of xanthine oxidase (Kooij et al., 1992a) in human tissues may be derived from the relatively low sensitivity of the enzyme histochemical method compared to the immunohistochemistry and/or presence of xanthine oxidase as an inactive form as suggested by Ikegami and Nishino (1986).

To exclude the possible presence of inactive forms or inhibitor(s) of xanthine oxidase, biological methods, such as enzyme histochemistry or *in situ* histochemistry, will be required. Recently, *in situ* histochemistry demonstrated xanthine oxidase mRNA in the capillary endothelium of equine skeletal muscle (Rasanen et al., 1993), supporting the results of enzyme and immunohistochemical localization of this enzyme. Therefore, xanthine oxidase is more likely to be translated and expressed in endothelial cells. The expression of xanthine oxidase mRNA has been studied in mouse (Terao et al., 1992), rat (Moriwaki et al., unpublished),

Enzymes of the purine metabolism

and human (Xu et al., 1994) tissues by immunoblot analysis. In the mouse, xanthine oxidase mRNA is expressed only in the liver and intestine, while in the human and rat, it is expressed in a variety of tissues.

The ubiquitous localization of xanthine oxidase shown by enzyme and immunohistochemical studies suggests a multifunctional role of this enzyme. Because of the formation of free radicals, xanthine oxidase has been implicated in the pathogenesis of post-ischemic reperfusion tissue injury. The extensive tissue localization of xanthine dehydrogenase/oxidase suggests several roles for this enzyme, including a protective barrier against bacterial infection. Xanthine oxidase may play a beneficial role by producing superoxide radicals. Tubaro et al. (1980a-c) suggested a role of xanthine oxidase as an antimicrobial agent. Van den Munckhof et al. (1995) demonstrated its activity around bacteria in

the epithelium of the esophagus, supporting this role. Moreover, it has been suggested that uric acid serves as an antioxidant. Therefore, xanthine oxidase serves as a defense mechanism by generating uric acid as well (Ames et al., 1981). Xanthine oxidase has also been suggested to be involved in influenza virus infection (Akaike et al., 1990), IRDS (Boda et al., 1984), ARDS (Grum et al., 1987), cutaneous photosensitivity (Athar et al., 1989), and burn injury (Saez et al., 1984). Furthermore, an involvement of this enzyme in cellular proliferation and differentiation has been suggested (Kooij et al., 1992b). Other pathophysiological functions of xanthine oxidase includes pigmentation of insects (Watt, 1972), protection against toxic plants (Krenitsky et al., 1972, 1974), metabolism of xenobiotics (Beedham, 1985). Xanthinuria is a rare inherited disease, in which a deficiency of xanthine oxidase activity results

Table 4. Histochemical tissue demonstration of xanthine oxidase at cellular and subcellular levels in various species.

SPECIES	TISSUE LOCALIZATION	CELLULAR OR SUBCELLULAR LOCALIZATION	METHOD	REFERENCE
Chicken	liver, kidney, pancreas, small intestine	hepatocyte, epithelium, acinar cell, proximal tubule	EH (LM)	McIndoe et al., 1974
Human	duodenum, jejunum	epithelial villi	EH (LM)	Auscher et al., 1980
Bovine	liver, mammary gland	endothelial cell	IH (EM)	Jarasch et al., 1981
Bovine	mammary gland, liver, heart, lung, intestine, skeletal muscle	epithelial and capillary endothelial cells	USERIA	Bruder et al., 1983
Human	placenta	endothelial cell	IH (LM)	Bruder et al., 1984
Rat	liver	crystalline core of peroxisome	EH (EM)	Angermuller et al., 1987
Rat	liver	limiting membrane, matrix of peroxisome	EH (EM)	Dikov et al., 1988
Chicken	liver	hepatocyte, Kupffer cell, endothelial cell	IH (LM)	Hattori, 1989
Rat	liver	cytosol of hepatocyte	IH (EM)	Ichikawa et al., 1992
Mouse	liver, intestine		immunoblotting	Terao et al., 1992
Human	jejunum liver	enterocyte, goblet cell, lamina propria sinusoidal cell, hepatocyte	EH (LM)	Kooij et al., 1992a
Rat	skin, vagina, uterus, penis, liver, tongue, esophagus, stomach, intestine	epithelial cell, sinusoidal cell, endothelial cell, connective tissue fibroblast	EH (LM) EH (LM)	Kooij et al., 1992b Kooij et al., 1992b; Moriwaki et al., 1998
Human	heart, muscle macrophage, mast cell	vascular smooth muscle, endothelium	IH (LM)	Hellsten-Westling, 1993
Horse	muscle	capillary endothelium	ISH	Rasanen et al., 1993
Human	heart, brain, placenta, lung, liver, kidney, skeletal muscle, pancreas, spleen, thymus, prostate, testis, ovary, intestine, WBC		immunoblotting	Xu et al., 1994
Rat	lung, heart, kidney, liver, skeletal muscle		immunoblotting	Moriwaki et al., unpublished
Rat	duodenum esophagus	cytoplasmic matrix of goblet cell, enterocyte cytoplasmic matrix of epithelial cell	EH (LM, EM)	Van den Munckhof et al., 1995
Rat	liver, kidney, esophagus, intestine, lung, adrenal, skeletal muscle, spleen, cerebrum	epithelial cell, renal tubules, hippocampus ependymal cell	IH (LM)	Moriwaki et al., 1996a
Human	tongue, esophagus, lung, sweat gland, mammary gland, stomach, kidney, intestine, spleen, liver, skeletal muscle	epithelium, glandular cell, renal tubules	IH (LM)	Moriwaki et al., 1996b

Abbreviations are the same as in Table 1. USERIA, ultrasensitive enzymic radioimmunoassay.

in an increase in hypoxanthine and xanthine (Yamamoto et al., 1991, 1992). The majority of the case are asymptomatic, but some patients show urinary xanthine stone, myopathy, and arthropathy.

To understand the pathophysiological role of xanthine oxidase, it requires: 1) the separate localization of xanthine oxidase from xanthine dehydrogenase, 2) quantitative histochemistry; and 3) an understanding of the regulatory mechanism. Although immunohistochemical methods are not able to discriminate the two forms of the enzyme, cerium-based enzyme histochemistry can detect the oxidase form and has been used for the localization of oxidases in a variety of tissues and cells (Frederiks and Marx, 1993). However, the drawback of the cerium method seems to be its limitation to use by electron microscopy, since cerium hydroperoxide is almost invisible at the light microscopic level. In general, what is known about the enzyme and immunohistochemistry are qualitative. However, quantitative histochemical methods have been reported (Frederiks et al., 1994, 1995), which enable us to evaluate tissue xanthine oxidase activity *in situ* in different pathological conditions. According to Frederiks and Bosch (1996), xanthine oxidoreductase (xanthine oxidase + xanthine dehydrogenase) activity in the rat liver is more abundant in the pericentral zone than in the periportal zone, and the ratio of xanthine oxidase to total xanthine oxidoreductase *in situ* remains constant at a level of 4%, as opposed to the 10 to 20% stated in literature. They suggested that the main function of xanthine oxidoreductase in the liver is the oxidation of xanthine rather than in the generation of reactive oxygen species. *In situ* hybridization analysis will provide some histochemical information as to the regulation of this enzyme. The review articles of Kooij (1994) and Moriwaki et al. (1997) cover the details of the tissue distribution and pathophysiological role of xanthine oxidase (see Tables 4 and 7).

Urate oxidase

Urate oxidase (EC 1.7.3.3) is a tetrameric cuproprotein with a molecular weight of 125 kd that catalyzes the oxidation of uric acid, forming allantoin, H_2O_2 , and CO_2 . The end product of purine metabolism differs from species to species. Most mammals possess uricase activity, thus excreting allantoin in the urine as an end product of purine metabolism. However, humans, anthropoid apes, birds, and some reptiles are lacking this enzyme, and excrete uric acid in the urine as the end product of purine metabolism. Light microscopic localization of urate oxidase activity was described by Graham and Karnovsky (1965), using 3-amino-9-ethyl carbazole as an electron donor. Light microscopic enzyme histochemistry showed a reactivity for urate oxidase in liver cells from lower mammals, prosimians, and platyrrhine monkeys. These studies showed that there was no preferential distribution of the reaction product in the liver cell areas (De la Iglesia et al., 1966;

Nakajima and Bourne, 1970). Viewing the enzyme by electron microscopy, it has been demonstrated that urate oxidase is localized in the matrix and membrane, as well as the core of rat or mouse liver peroxisomes (Yokota and Nagata, 1974; Veenhuis and Wendelaar Bonga, 1979; Angermuller and Fahimi, 1986). In addition, Yokota and Nagata (1974) demonstrated the enzyme in peroxisomes, as well as the endoplasmic reticulum and Golgi apparatus, suggesting the possibility of the presence of a urate oxidase antigen without activity in the matrix. This result seems inconsistent with the immunohistochemical one that urate oxidase was not localized in the endoplasmic reticulum or the Golgi complex (Volkl et al., 1988), and the biochemical one that urate oxidase activity is contained in peroxisome cores. However, in the study of Angermuller and Fahimi using a cerium-based method (1986), urate oxidase staining of the matrix and membrane was best seen in peroxisomes with large cores, while those without cores showed very little reaction in the matrix, suggesting that the staining of the matrix may derive from diffusion of H_2O_2 or cerium perhydroxide from the cores. Also, the indirect method using DAB for localization of peroxisomal oxidases (Veenhuis and Wendelaar Bonga, 1979) has proven to be unreliable for urate oxidase, since prolonged incubation of rat liver tissue in DAB gives rise to an electron-dense reaction product in the mitochondria as well as peroxisomes (Angermuller and Fahimi, 1981). Recently, Van den Munckhof et al. (1994) studied the localization of urate oxidase activity in the rat liver using unfixed cryostat sections because of the controversial results as to the subcellular localization of this enzyme. Consequently, urate oxidase activity was present not only in the core, but also in the matrix of peroxisomes. Although urate oxidase is usually confined to the crystalline cores of peroxisomes in the rat liver (Angermuller and Fahimi, 1986), it is not confined to the cores of peroxisomes, and has been noted diffusely in the matrix of some peroxisomes in regenerating rat liver tissue (Yamamoto and Fahimi, 1987), or is associated with the peroxisome membrane in the carp liver (Kramar et al., 1974) and in the peroxisomal matrix in fish and amphibian livers (Noguchi et al., 1979; Fujiwara et al., 1987). The distribution of urate oxidase in various rat tissues and in the livers of several mammalian species was investigated by immunoelectron microscopy as well as immunoblotting, using an anti-rat urate oxidase polyclonal antibody. Immunoblot analysis demonstrated that urate oxidase was not present in the rat kidney, jejunum, adrenal gland, or pancreas, but was only in the liver, suggesting urate oxidase to be a liver-specific protein in rats. In the livers of other mammals, urate oxidase was detected in two strains of mice, as well as hamsters, dogs, cats, and cows, but not in a *Cynomolgus* monkey or humans. Protein A-gold immunoelectron microscopy demonstrated that urate oxidase was exclusively localized in the crystalloid core of the peroxisome in hepatic parenchymal cells in the two strains of mice, as well as the hamsters, dogs, cats, and

Enzymes of the purine metabolism

cows. In contrast, urate oxidase was not present in the limiting membrane or the matrix of hepatic peroxisomes in these species. The peroxisome proliferator did not induce urate oxidase in the rat liver (Usuda et al., 1988a).

Urate oxidase was not detectable in human or nonhuman primate liver tissue which lacks a discernible core in the peroxisome. These results suggest a close association of urate oxidase and peroxisome cores in the liver. However, the absence of urate oxidase does not necessarily reflect the absence of cores in peroxisomes, since some peroxisomes without a core, such as in a soy bean nodule, have shown diffuse staining by protein-A gold histochemistry (Van den Bosch, 1986). Peroxisomes in extrahepatic rat tissues did not stain against urate oxidase as shown by the histochemical data which demonstrated no urate oxidase activity in the rat kidney (Graham and Karnovsky, 1965). It has also been recognized by immunoblot and slot blot analyses that revealed that urate oxidase was a liver-specific protein in rats (Motojima and Goto, 1990). Therefore, it is worthy of special mention that bovine kidney peroxisome possesses urate oxidase (Usuda et al., 1988b).

Enzyme histochemical localization of urate oxidase in the rat liver was reported by Veenhuis and Wendelaar Bonga (1979), using a cerium technique. They showed that urate oxidase was present in the peroxisomal matrix as well as the cores of rat hepatocytes. Vaughn et al. (1982) demonstrated the presence of urate oxidase activity in leguminous plants using this method on unfixed material, while Thomas and Trelease (1981) failed to demonstrate the enzyme activity in a potato tuber or castor bean endosperm fixed with form-

aldehyde-glutaraldehyde, the result probably being due to the high sensitivity of urate oxidase to aldehyde fixation (Graham and Karnovsky, 1965). Although these authors suggested that the cerium method may not be suitable for localization of urate oxidase in plant peroxisomes, Angermüller and Fahimi (1986), surveying optimal conditions for a cerium technique to demonstrate urate oxidase, verified the ultrastructural localization of the enzyme in the crystalline cores of rat hepatic peroxisomes by enzyme-histochemistry.

In situ histochemistry demonstrated that urate oxidase mRNA was homogeneously distributed throughout the rat liver lobule (Schad et al., 1996), and that it was rich in hepatocytes. In contrast, endothelial and perisinusoidal cells, bile duct epithelial cells, and fibroblasts of the periportal zone were negative for urate oxidase mRNA, since these cells possess only a few small peroxisomes (Fahimi et al., 1976).

As for the role of urate oxidase, triggering the germination of bacterial spores (Salas et al., 1985) and participation in bean seedling establishment (Capote-Mainez and Sanchez, 1997) have been suggested. The tissue distribution and pathophysiological roles of urate oxidase are summarized in Table 5 and 7.

Allantoinase, allantocase, ureidoglycollate lyase

Allantoinase, allantocase, and ureidoglycollate lyase are the enzymes that are involved in the degradation of allantoin to urea and glycollate, and are located in the peroxisomes. The tissue distribution of these enzymes has not been studied by histochemistry. However, as seen by sucrose density gradient centrifugation,

Table 5. Histochemical tissue demonstration of urate oxidase at cellular and subcellular levels in various species.

SPECIES	TISSUE LOCALIZATION	CELLULAR OR SUBCELLULAR LOCALIZATION	METHOD	REFERENCE
Squirrel monkey	liver	peroxisome (core > matrix)	EH (EM)	De la Iglesia et al., 1966
Lower mammals, Prosimians, Platyrrhine monkeys	liver	parenchymal cell	EH (LM)	Nakajima and Bourne, 1970
Carp	liver	peroxisome (membrane)	EH (EM)	Kramar et al., 1974
Mouse, rat	liver	peroxisome (core, matrix, membrane) ER, Golgi complex	IH (EM)	Yokota and Nagata, 1974
Fish, frog	liver	peroxisome (matrix)	sucrose gradient	Noguchi et al., 1979; Fujiwara et al., 1987
Rat	liver	peroxisome (core, matrix, membrane)	EH (EM)	Angermüller et al., 1986
Soy bean	nodule	peroxisome	IH (EM)	Van den Bosch, 1986
Mouse, hamster, Dog, cat, cow	liver	peroxisome (core)	IH (EM)	Usuda et al., 1988a
Hog	kidney	peroxisome	IH (EM)	Usuda et al., 1988b
Rat	liver	peroxisome (core, matrix)	EH (EM)	Van den Munkhof et al., 1994
Rat	liver	hepatocyte	ISH	Schad et al., 1996

Abbreviations are the same as in Table 1.

allantoinase (EC 3.5.2.5) seems to be localized in the peroxisome matrix and allantoicase (EC 3.5.3.4) in the peroxisomal membrane in fish and crustacean livers (Noguchi et al., 1979). Ureidoglycollate lyase (EC 4.3.2.3) was also found in the peroxisomes of marine fish livers (Takada and Noguchi, 1986). These allantoin-degrading enzymes are considered to have been lost in mammals during evolution. It is noteworthy, however, that ureidoglycollate lyase was found in rat tissues (Fujiwara and Noguchi, 1995). In the rat liver, ureidoglycollate lyase was located in the mitochondria; however, in contrast, the fish liver ureidoglycollate lyase was located in the peroxisomes. The exact reason for the presence of ureidoglycollate lyase is unclear, but other roles, such as creatine synthesis, rather than purine metabolism, is assumed. The tissue distribution and pathophysiological roles of allantoin-degrading enzymes are summarized in Tables 6 and 7.

AMP-deaminase

AMP deaminase (EC 3.5.4.6) is an enzyme that catalyzes the hydrolytic deamination of AMP, producing IMP and ammonia, and its activity is higher in skeletal muscle than in any other tissues. AMP deaminase may be involved in a number of physiological processes, such as the conversion of adenine nucleotide to inosine or guanine nucleotide (Askari and Rao, 1968), stabilizing the adenylate energy charge (Chapman and Atkinson, 1973; Coffee and Solano, 1977), and the reaction of the purine nucleotide cycle (Bogusky et al., 1976; Schultz and Lowenstein, 1976). AMP deaminase activity in rats

appears to be localized similarly in all muscle fiber types. However, histochemical staining for AMP deaminase demonstrated that fast-twitch fibers contained much more AMP deaminase activity than slow-twitch fibers (Meyer et al., 1980). Similarly, hamster gastrocnemius fast-glycolytic fibers showed the strongest staining for AMP deaminase, while the slow-oxidative fibers showed only a weak staining for this enzyme. Capillary endothelium and all fiber types associated with actomyosin were stained most strongly (Gilloteaux and Ader, 1983). AMP deaminase was found to be bound to the myosin filament on fluorescent antibody staining (Ashby et al., 1979). On the contrary, Higuchi et al. (1987), using an anti-rabbit AMP deaminase antibody, immunohistochemically found the enzyme localized in rimmed vacuoles in the skeletal muscles of adult onset acid maltase deficiency or distal myopathy with a rimmed vacuole formation, and suggested that AMP deaminase in the rimmed vacuoles does not seem to be associated with myosin, since the rimmed vacuoles were considered to be autophagocytic ones that were not stained for myosin ATPase. In addition, they suggested that the AMP deaminase found in rimmed vacuoles is associated with the formation of autophagocytic vacuoles. AMP deaminase exists as a tetramer, and there are three distinct isozymes (A, B, C) with different kinetic, physical, and immunological properties. Isozymes A, B, and C were isolated from muscle, liver (kidney), and heart tissue, respectively. In rat skeletal muscle, isozyme A is mainly localized in sarcolemma and interfibril, while isozymes B and C are mainly located in the non-myofibril elements of the muscle.

Table 6. Histochemical tissue demonstration of allantoin-degrading enzymes, AMP-deaminase, and HGPRT at cellular and subcellular levels in various species.

	SPECIES	TISSUE LOCALIZATION	CELLULAR OR SUBCELLULAR LOCALIZATION	METHOD	REFERENCE
Allantoinase	fish, crustacea	liver	peroxisome matrix	sucrose gradient	Noguchi et al., 1979
Allantoicase	fish, crustacea	liver	peroxisome membrane	sucrose gradient	Noguchi et al., 1979
Ureidoglycollate lyase	marine fish	liver	peroxisome	sucrose gradient	Takada and Noguchi, 1986
	rat	liver	mitochondria	sucrose gradient	Fujiwara and Noguchi, 1995
	fish	liver	peroxisome	sucrose gradient	
AMP-deaminase	hamster	gastrocnemius muscle	fast glycolytic > slow oxidative	EH (LM)	Gilloteaux and Ader, 1983
	rat	plantaris and soleus muscle	muscle fiber (fast-twitch>slow twitch)	EH (LM)	Meyer et al., 1980
	chicken	pectral muscle (culture)	myosin filament	fluorescent staining	Ashby et al., 1979
	human	skeletal muscle	rimmed vacuole	IH (LM)	Higuchi et al., 1987
	rat	skeletal muscle	sarcolemma, interfibril	fluorescent, IH (LM)	Thompson et al., 1992
isozyme A					
isozyme B	rat	skeletal muscle	connective tissue		
isozyme C	rat	skeletal muscle	vascular wall, capillary endothelium, RBC		
HGPRT	mouse	brain (cerebellum)	Purkinje cells, hippocampus	IH (LM)	Ikeda et al., 1993

Abbreviations are the same as in Table 1.

Enzymes of the purine metabolism

Isozyme B is principally associated with connective tissues surrounding neural elements and the muscle spindle capsule, and isozyme C is mainly associated with arterial and venous walls, capillary endothelium, and erythrocytes. This localization suggests a multiple functional role for this enzyme (Thompson et al., 1992).

Fishbein et al. (1978), using a histochemical method for the demonstration of AMP deaminase activity, discovered the presence of muscle AMP deaminase deficiency in humans. Histochemical staining of AMP deaminase in biopsy specimens from various types of muscle diseases was performed by Nagao et al. (1986) to elucidate the change, if any, of AMP deaminase activity in neuromuscular disorders. They concluded that the decreased AMP deaminase activity was related to the intensity of the pathological change, rather than the kind of the disease.

Studies on the distribution of AMP deaminase in organs, except for muscle, are few, including those on AMP deaminase in the rat kidney. It was suggested that the highest activity was in the distal nephron, in striking

contrast to 5'-nucleotidase whose activity was highest in the proximal nephron (Cole et al., 1982). Other enzymes involved in the purine nucleotide cycle in the rat kidney besides AMP deaminase, namely adenylosuccinate synthetase and adenylosuccinate lyase, had higher activity in the medulla than in the cortex, suggesting that the purine nucleotide cycle operates primarily in the medulla of the rat kidney (Pawelczyk and Angielski, 1988). The tissue distribution and pathophysiological roles of AMP deaminase are summarized in Tables 6 and 7.

Hypoxanthine guanine phosphoribosyl transferase (HGPRT)

Hypoxanthine guanine phosphoribosyl transferase (HGPRT, EC 2.4.2.8) is a purine salvage enzyme which catalyzes the conversion of hypoxanthine or guanine to IMP or GMP, respectively. High HGPRT activity is found in some regions of a normal adult human brain. Moreover, high activities of HGPRT were observed in

Table 7. Pathophysiological roles of enzymes involved in purine metabolism.

ENZYME	FUNCTION	REFERENCE
5'-nucleotidase	synthesis of fibrous protein and calcification cellular growth transport process cellular motile response neurotransmission supply of carbon source cytokinin metabolism regulation of nucleotide pool size lymphocyte activation cellular contact formation synaptogenesis ? oxygen sensing	Gibson and Fullmer, 1967 Hardonk and Koudstaal, 1968a,b Gartner et al., 1978 Rohr and Mannherz, 1979 Schubert et al., 1979 Bengis-Garber and Kushner, 1981 Chen et al., 1981; Burch and Stuchbury, 1986 Carter and Tipson, 1986 Thompson et al., 1987 Schoen et al., 1988; Vogel et al., 1991 Schoen et al., 1993 Bachmann and Ramasubbu, 1997
ADA	SCID differentiation (epithelial cell, monocyte) anoxia asthma neurotransmission maintenance of gestation	Giblett et al., 1972; Cohen, 1975 Trotta and Balis, 1977; Fischer et al., 1976 Stefanovich, 1982 Ronchetti et al., 1984 Nagy et al., 1984 Mohamedali et al., 1993
PNP	SCID centriole replication, microtubule assembly immune and repair reaction	Giblett et al., 1975; Stoop et al., 1977 Oliver et al., 1981 Castellano et al., 1990
Xanthine oxidase	pigmentation protection against toxic plants ? reperfusion tissue injury metabolism of xenobiotics xanthinuria cellular differentiation/proliferation bacteriocidal activity	Watt, 1972 Krenitsky, 1978 McCord, 1985 Beedham, 1985 Yamamoto et al., 1991, 1992 Kooj et al., 1992b Van den Munkhof et al., 1995
Urate oxidase	germination of bacterial spores seedling establishment	Salas et al., 1985 Capote-Mainez and Sanchez, 1997
Ureidoglycollate lyase	creatine synthesis ?	Fujiwara et al., 1995
AMP-deaminase	AMP deaminase deficiency stabilizing adenylate energy charge	Fishbein et al., 1978 Chapman and Atkinson, 1973; Coffee and Solano, 1977
HGPRT	Lesch-Nyhan syndrome	Sculley et al., 1991
APRT	2,8-DHA(dihydroxyadenine) urolithiasis cytokinin metabolism	Kamatani et al., 1992 Chen et al., 1982; Doree and Guern, 1973

the brains of horses, as well as those of humans and rabbits, suggesting that this enzyme is functionally important in the equine brain (Harkness et al., 1990). However, very little is known regarding the histochemical tissue localization of HGPRT, except for one study (Ikeda et al., 1993), and there have been no studies by *in situ* histochemistry to localize the distribution of HGPRT mRNA in tissues. Immunohistochemical localization and its developmental expression has been studied in the mouse brain (Ikeda et al., 1993). HGPRT was present in the Purkinje cells of the cerebellum throughout growth. On the contrary, HGPRT was almost not detectable in the new born mouse hippocampus, but later its increased reactivity was observed in the granular cells of the hippocampus. From these observations, it was suggested that HGPRT may not be an essential purine nucleotide supplement in the segmentation of brain cells, but may play a significant role in the developing hippocampus. Complete deficiency of HGPRT results in Lesch-Nyhan syndrome, which is characterized by hyperuricemia, self-mutilation, mental retardation, choreoathetosis, and spasticity (Sculley et al., 1991). The tissue distribution and pathophysiological roles of HGPRT are summarized in Tables 6 and 7.

Adenine phosphoribosyl transferase (APRT)

Adenine phosphoribosyl transferase (APRT, EC 2.4.2.7) is generally referred to as a purine salvage enzyme together with HGPRT. APRT catalyzes the formation of AMP and inorganic phosphate from adenine and PRPP. APRT is widely distributed in human tissues, with the highest activity found in the liver. It is generally accepted that APRT is a cytosolic enzyme (Arnold, 1978), but studies using membrane vesicles of erythrocytes (De Bruyn and Oei, 1977) or lymphocytes (Yip et al., 1982) suggest that APRT is loosely bound to the cell membrane. Adenosine phosphorylase is involved in the salvage of adenine in animals and microorganisms. However, in higher plants, the salvage of adenine is accomplished by the action of APRT not by adenosine phosphorylase. APRT has been found in various species of plants (Burch and Stuchbury, 1986), and the role of this enzyme in the metabolism of cytokinin has been suggested (Chen et al., 1982; Doree and Guern, 1973). In humans, deficiency of APRT results in 2,8-dihydroxyadenine urolithiasis because of an inability to salvage the purine base adenine to AMP (Kamatani et al., 1992). The tissue distribution and pathophysiological roles of APRT are summarized in Tables 6 and 7.

Adenosine kinase

Adenosine kinase (EC 2,7,1,20) is an enzyme that converts adenosine to AMP. To our knowledge, there have been no previous studies concerning the histochemical tissue localization of adenosine kinase. However, activities of adenosine kinase were measured

biochemically, together with other adenosine regulating enzymes, in muscle, nervous tissues, lungs, etc of various invertebrates and vertebrates. The activities of adenosine kinase are generally lower than those of 5'-nucleotidase in muscle and brain tissue, whereas those in the mouse liver, lung, and blood were found to be rather higher (Arch and Newsholme, 1978). The high activities of adenosine kinase in the liver, lung, and blood may play a significant role in the removal of adenosine so that other tissues, such as the heart, would not be influenced by accumulated adenosine.

Conclusion

Enzymes involved in purine metabolism have been demonstrated to be ubiquitously distributed in various tissues of different animal and plant species. While the exact function of these enzymes is still unknown, they seem to play important roles other than in purine metabolism. To elucidate their functional roles, it is imperative to clarify the mechanism of regulation and/or expression of these enzymes at the cellular or subcellular level, as well as their tissue distribution. However, since few studies have been performed on the dynamic changes in the expression of these enzymes at the protein or mRNA levels, further studies utilizing methods such as *in situ* hybridization techniques will be required.

References

- Adachi T., Fukushima T., Usami Y. and Hirano K. (1993). Binding of human xanthine oxidase to sulphated glycosaminoglycans on the endothelial-cell surface. *Biochem. J.* 289, 523-527.
- Adams A. and Harkness R.A. (1976). Adenosine deaminase activity in thymus and other human tissues. *Clin. Exp. Immunol.* 26, 647-649.
- Akaike T., Ando M., Oda T., Ijiri S., Araki S. and Maeda H. (1990). Dependence on O₂⁻ generation by xanthine oxidase of pathogenesis of influenza virus infection in mice. *J. Clin. Invest.* 85, 739-745.
- Ames B.N., Cathcart R., Scwiers E. and Hochstein P. (1981). Uric acid provides an antioxidant defence in humans against oxidant- and radical-caused aging and cancer: A hypothesis. *Proc. Natl. Acad. Sci. USA* 78, 6858-6862.
- Angermuller S. and Fahimi H.D. (1981). Selective cytochemical localization of peroxidase, cytochrome oxidase and catalase in rat liver with 3, 3'-diaminobenzidine. *Histochemistry* 7, 33-44.
- Angermuller S. and Fahimi H.D. (1986). Ultrastructural cytochemical localization of uricase in peroxisomes of rat liver. *J. Histochem. Cytochem.* 34, 159-165.
- Angermuller S., Bruder G., Volkl A., Wesch H. and Fahimi H.D. (1987). Localization of xanthine oxidase in crystalline cores of peroxisomes. A cytochemical and biochemical study. *Eur. J. Cell Biol.* 45, 137-144.
- Aran J.M., Colomer D., Matutes E., Vives-Corrons J.L. and Franco R. (1991). Presence of adenosine deaminase on the surface of mononuclear blood cells; Immunohistochemical localization using light and electron microscopy. *J. Histochem. Cytochem.* 39, 1001-1008.
- Arch J.R.S. and Newsholme E.A. (1978). Activities and some properties

Enzymes of the purine metabolism

- of 5'-nucleotidase, adenosine kinase and adenosine deaminase in tissues from vertebrates and invertebrates in relation to the control of the concentration and the physiological role of adenosine. *Biochem. J.* 174, 965-977.
- Arnold W.J. (1978). Purine salvage enzymes. In: Uric acid. Kelly W.N. and Weiner I.M. (eds). Springer-Verlag. Berlin. pp 43-61.
- Ashby B., Frieden C. and Bischoff R. (1979). Immunofluorescent and histochemical localization of AMP deaminase in skeletal muscle. *J. Cell Biol.* 81, 361-373.
- Askari A. and Rao S.N. (1968). Regulation of AMP deaminase by 2,3-diphosphoglyceric acid: a possible mechanism for the control of adenine nucleotide metabolism in human erythrocytes. *Biochim. Biophys. Acta* 151, 198-203.
- Athar M., Elmets C.A., Bickers D.R. and Mukhtar H. (1989). A novel mechanism for the generation of superoxide anions in hematomorphin derivative-mediated cutaneous photosensitization. Activation of the xanthine oxidase pathway. *J. Clin. Invest.* 83, 1137-1143.
- Auscher C., Amory N., Van der Kemp P. and Delbarre F. (1980). Xanthine oxidase activity in human intestines. Histochemical and radiochemical study. *Adv. Exp. Med. Biol.* 122B, 197-201.
- Bachmann S. and Ramasubbu K. (1997). Immunohistochemical colocalization of the alpha-subunit of neutrophil NADPH oxidase and ecto-5'-nucleotidase in kidney and liver. *Kidney Int.* 51, 479-482.
- Bailly Y., Schoen S.W., Delhaye-Bouchaud N., Kreutzberg G.W. and Mariani J. (1995). 5'-nucleotidase activity as a synaptic marker of parasagittal compartmentation in the mouse cerebellum. *J. Neurocytol.* 24, 879-890.
- Barton R., Martiniuk F., Hirschhorn R. and Goldschneider I. (1979). The distribution of adenosine deaminase among lymphocyte populations in the rat. *J. Immunol.* 122, 216-220.
- Becker M.A. and Kim M. (1987). Regulation of purine synthesis de novo in human fibroblasts by purine nucleosides and phosphoribosylpyrophosphate. *J. Biol. Chem.* 262, 14531-14537.
- Beedham C. (1985). Molybdenum hydroxylases as drug-metabolising enzymes. *Drug Metab. Rev.* 16, 119-156.
- Bengis-Garber C. and Kuschner D.J. (1981). Purification and properties of 5'-nucleotidase from the membrane of *Vibrio costicola*, a moderately halophilic bacterium. *J. Bacteriol.* 146, 24-32.
- Berman J.J., Tong C. and Williams G.M. (1980). 5'-nucleotidase activities in cultured rat liver epithelial and fibroblast cells. *J. Histochem. Cytochem.* 28, 174-177.
- Berne R.M. and Rubio R. (1974). Adenine nucleotide metabolism in the heart. *Circ. Res.* 34-35, Suppl. III, 109-120.
- Blok J., Onderwater J.J.M., de Water R. and Ginsel L.A. (1982). A cytochemical method for the demonstration of 5'-nucleotidase in mouse peritoneal macrophages, with cerium ions used as trapping agent. *Histochemistry* 75, 437-443.
- Boda D., Nemeth I., Hencz P. and Denes K. (1984). Effect of allopurinol treatment in premature infants with idiopathic respiratory distress syndrome. *Dev. Pharmacol. Ther.* 7, 357-367.
- Bogusky R.T., Lowenstein L.M. and Lowenstein J.M. (1976). The purine nucleotide cycle. A pathway for ammonia production in the rat kidney. *J. Clin. Invest.* 58, 326-335.
- Borgers M. and Thone F. (1992). Species differences in adenosine metabolic sites in the heart. *Histochem. J.* 24, 445-452.
- Borgers M., Verhaegen H., De Brabander M., Thone F., Van Reempts J. and Geuens G. (1977). Purine nucleoside phosphorylase, a possible histochemical marker for T-cells in man. *J. Immunol. Meth.* 16, 101-110.
- Brady T.G. and O'Donovan C.I. (1965). A study of the tissue distribution of adenosine deaminase in six mammal species. *Comp. Biochem. Physiol.* 14, 101-120.
- Brandan E. and Fleischer B. (1982). Orientation and role of nucleoside diphosphatase and 5'-nucleotidase in Golgi vesicles from rat liver. *Biochemistry* 21, 4640-4645.
- Bruder G., Heid H.W., Jarasch E-D. and Mather I.H. (1983). Immunological identification and determination of xanthine oxidase in cells and tissues. *Differentiation* 23, 218-225.
- Bruder G., Jarasch E-D. and Heid H.W. (1984). High concentrations of antibodies to xanthine oxidase in human and animal sera. Molecular characterization. *J. Clin. Invest.* 74, 783-794.
- Burch L.R. and Stuchbury T. (1986). Metabolism of purine nucleotides in the tomato plant. *Phytochemistry* 25, 2445-2449.
- Capote-Mainez N. and Sanchez F. (1997). Characterization of the common bean uricase II and its expression in organs other than nodules. *Plant Physiol.* 115, 1307-1317.
- Carson D.A., Kaye J. and Seegmiller J.E. (1977). Lymphospecific toxicity in adenosine deaminase deficiency and purine nucleoside phosphorylase deficiency: possible role of nucleoside kinase(s). *Proc. Natl. Acad. Sci. USA* 74, 5677-5681.
- Carter S.G. and Tipson C.L. (1986). Purification and characterization of a 5'-nucleotidase from *Zea mays* microsomes. *Phytochemistry* 25, 33-37.
- Castellano B., Gonzalez B., Finsen B.R. and Zimmer J. (1990). Histochemical demonstration of purine nucleoside phosphorylase (PNPase) in microglial and astroglial cells of adult rat brain. *J. Histochem. Cytochem.* 38, 1535-1539.
- Centelles J.J., Franco R. and Bozal J. (1987). Distribution of adenosine deaminase in some rat tissues. Inhibition by ethanol and dimethyl sulfoxide. *Comp. Biochem. Physiol.* 86B, 95-98.
- Chapman A.G. and Atkinson D.E. (1973). Stabilization of adenylate energy charge by the adenylate deaminase reaction. *J. Biol. Chem.* 248, 8309-8312.
- Chechik B.E. and Sengupta S. (1981). Detection of human, rat, and mouse adenosine deaminase by immunochemical and immunomorphologic methods using antiserum to calf enzyme. *J. Immunol. Meth.* 45, 165-176.
- Chechik B.E., Baumal R. and SenGupta S. (1983). Localization and identity of adenosine deaminase-positive cells in tissues of the young rat and calf. *Histochem. J.* 15, 373-387.
- Chechik B.E., Schrader W.P. and Minowada J. (1981). An immunomorphologic study of adenosine deaminase distribution in human thymus tissue, normal lymphocytes, and hematopoietic cell lines. *J. Immunol.* 126, 1003-1007.
- Chen C-M., Melitz D.K. and Clough F.W. (1982). Metabolism of cytokinin: phosphoribosylation of cytokinin bases by adenine phosphoribosyltransferase from wheat germ. *Arch. Biochem. Biophys.* 214, 634-641.
- Coffee C.J. and Solano C. (1977). Rat muscle 5'-adenylic acid aminohydrolase. Role of K⁺ and adenylate energy charge in expression of kinetic and regulatory properties. *J. Biol. Chem.* 252, 1606-1612.
- Cohen F. (1975). Clinical features in combined immunodeficiency diseases and adenosine deaminase deficiency: A molecular defect. Academic. New York. p 245.
- Cohen A., Hirschhorn R., Horowitz S.D., Rubinstein A., Polmar S.H., Hong R. and Martin Jr. D.W. (1978). Deoxyadenosine triphosphate

Enzymes of the purine metabolism

- as a potentially toxic metabolite in adenosine deaminase deficiency. Proc. Natl. Acad. Sci. USA 75, 472-476.
- Cole B.R., Hays A.E., Boylan J.G., Burch H.B. and Lowry O.H. (1982). Distribution of enzymes of adenylate and guanylate nucleotide metabolism in rat nephron. Am. J. Physiol. 243, F349-F355.
- Corte-Real S., Porrozzini R., de Nazareth M. and de Meirelles L. (1993). Immunogold labeling and cerium cytochemistry of the enzyme ecto-5'-nucleotidase in promastigote forms of *Leishmania* species. Memórias do Instituto Oswaldo Cruz 88, 407-412.
- Darvish A., Postlewaite J.J. and Metting P.J. (1993). Immunogold localization of adenosine 5'-monophosphate specific cytosolic 5'-nucleotidase in dog heart. Hypertension 21, 906-910.
- Dawson T.P., Gandhi R., Le Hir M. and Kaissling G. (1989). Ecto 5'-nucleotidase: localization by light microscopic histochemistry and immuno-histochemistry methods in the rat kidney. J. Histochem. Cytochem. 37, 39-47.
- De Bruyn C.H.M.M. and Oei T.L. (1977). Purine phosphoribosyltransferases in human erythrocyte ghosts. Adv. Exp. Med. Biol. 76A, 139-152.
- De la Iglesia F.A., Porta E.A. and Hartroft W.S. (1966). Histochemical urate oxidase activity and microbodies in nonhuman primate liver. J. Histochem. Cytochem. 14, 685-687.
- Dikov V.A., Alexandrov I., Roussinova A. and Boyadjieva-Michailova A. (1988). Ultracytochemischer Nachweis von Enzymen durch Reduktion von Kalium hexacyanoferrat III. I. Eine Methode zum Nachweis der Xanthinoxidase. Acta. Histochem. 83, 107-115.
- Doree M. and Guern J. (1973). Short-term metabolism of some exogenous cytokinins in *Acer pseudoplatanus* cells. Biochim. Biophys. Acta 304, 611-622.
- Fahimi H.D., Gray A.B. and Hezog V.K. (1976). Cytochemical localization of catalase and peroxidase in sinusoidal cells of rat liver. Lab. Invest. 34, 192-201.
- Fishbein W.N., Armbrustmacher V.W. and Griffin J.L. (1978). Myo-adenylate deaminase deficiency: a new disease of muscle. Science 200, 545-549.
- Fischer D., Van der Weyden M.B., Snyderman R. and Kelley W.N. (1976). A role for adenosine deaminase in human monocyte maturation. J. Clin. Invest. 58, 399-407.
- Fox I.H. (1978). Degradation of purine nucleotides. In: Uric acid. Kelley W.N. and Weiner I.M. (eds). Springer-Verlag. New York. p 93.
- Fox I.H. and Kelley W.N. (1978). The role of adenosine and 2'-deoxyadenosine in mammalian cells. Annu. Rev. Biochem. 47, 655-686.
- Franco R., Aran J.M., Colomer D., Matutes E. and Vives-Corrons J.L. (1990). Association of adenosine deaminase with erythrocyte and platelet plasma membrane: An immunological study using light and electron microscopy. J. Histochem. Cytochem. 38, 653-658.
- Frederiks W.M. and Bosch K.S. (1996). The proportion of xanthine oxidase activity of total xanthine oxidoreductase activity *in situ* remains constant in rat liver under various (patho)physiological conditions. Hepatology 24, 1179-1184.
- Frederiks W.M. and Marx F. (1993). A histochemical procedure for light microscopic demonstration of xanthine oxidase activity in unfixed cryostat sections using cerium ions and a semipermeable membrane techniques. J. Histochem. Cytochem. 41, 667-670.
- Frederiks W.M., Bosch K.S. and Kooij A. (1995). Quantitative *in situ* analysis of xanthine oxidoreductase activity in rat liver. J. Histochem. Cytochem. 43, 723-726.
- Frederiks W.M., Bosch K.S. and Gulik T.V. (1993). A quantitative histochemical procedure for the demonstration of purine nucleoside phosphorylase activity in rat and human liver using Tetranitro BT and xanthine oxidase as auxiliary enzyme. Histochem. J. 25, 86-91.
- Frederiks W.M., Bosch K.S., Van den Munckhof R.J.M. and van Noorden C.J.F. (1994). A quantitative histochemical study of xanthine oxidase activity in rat liver using cerium capture method in the presence of polyvinyl alcohol. J. Histochem. Cytochem. 42, 1091-1097.
- Frederiks W.M., Marx F. and Myagkaya G.L. (1988). A quantitative histochemical study of 5'-nucleotidase activity in rat liver after ischemia. J. Pathol. 154, 277-286.
- Fujiwara S. and Noguchi T. (1995). Degradation of purines: only ureidoglycollate lyase out of four allantoin-degrading enzymes is present in mammals. Biochem. J. 312, 315-318.
- Fujiwara S., Ohashi H. and Noguchi T. (1987). Comparison of intraperoxisomal localization form and properties of amphibian (*Rana catesbeiana*) uricase with those of other animal uricases. Comp. Biochem. Physiol. 86B, 23-26.
- Gandhi R., Le Hir M. and Kaissling B. (1990). Immunolocalization of ecto-5'-nucleotidase in the kidney by a monoclonal antibody. Histochemistry 95, 165-174.
- Gartner L.P., Seibel W., Hiatt J.L. and Provenza D.V. (1978). Electron microscopic localization of 5'-nucleotidase in the stratum intermedium and ameloblasts. Histochem. J. 10, 115-122.
- Giblett E.R., Anderson J.E., Cohen F., Pollara B. and Meuwissen H.J. (1972). Adenosine-deaminase deficiency in two patients with severely impaired cellular immunity. Lancet 2, 1067-1069.
- Giblett E.R., Ammann A.J., Wara D.W., Sandman R. and Diamond L.K. (1975). Nucleoside-phosphorylase deficiency in a child with severely defective T-cell immunity and normal B-cell immunity. Lancet 1, 1010-1013.
- Gibson W. and Fullmer H. (1967). Histochemistry of the periodontal ligament: II. The phosphatases. Periodontics 5, 226-232.
- Gilloteaux J. and Ader M. (1983). AMP deaminase histoenzymology in hamster skeletal muscle. Acta. Histochem. 73, 47-51.
- Goodman M.N. and Lowenstein J.M. (1977). The purine nucleotide cycle: Studies of ammonia production by skeletal muscle *in situ* and in perfused preparations. J. Biol. Chem. 252, 5054-5060.
- Graham R.C. and Karnovsky M.J. (1965). The histochemical demonstration of uricase activity. J. Histochem. Cytochem. 13, 448-453.
- Grondal E.J.M., Janetzko A. and Zimmermann H. (1988). Monospecific antiserum against 5'-nucleotidase from *Torpedo electric* organ: immunocytochemical distribution of the enzyme and its association with Schwann cell membranes. Neuroscience 24, 351-363.
- Grum C.M., Ragsdale R.A., Ketel L.H. and Simon R.H. (1987). Plasma xanthine oxidase activity in patients with adult respiratory distress syndrome. J. Crit. Care 2, 22-26.
- Haag R. and Lewis R.A. (1994). The partial purification and characterization of purine nucleoside phosphorylase from mammalian mitochondria. Mol. Cell Biochem. 135, 126-136.
- Hardonk M.J. and Koudstaal J. (1968a). 5'-nucleotidase II. The significance of 5'-nucleotidase in the metabolism of nucleotides studied by histochemical and biochemical methods. Histochemie 12, 18-28.
- Hardonk M.J. and Koudstaal J. (1968b). 5'-nucleotidase IV. Localization of 5'-nucleotidase and alkaline phosphatase isoenzymes in the kidney of young and adult mice. Histochemie 15, 290-299.
- Harkness P.A., McCreanor G.M., Allsop J., Snow D.H., Harris R.C., Rosedale P.O. and Ousey J.C. (1990). Hypoxanthine phospho-

- ribosyltransferase activity in tissues and hypoxanthine concentrations in plasma and CSF of the horse in comparison with other species. *Comp. Biochem. Physiol* 97B, 591-596.
- Hattori Y. (1989). Localization of xanthine dehydrogenase in chicken liver. *Acta. Histochem. Cytochem.* 22, 617-624.
- Heidemann M., Dieckhoff J., Hlavsa C. and Mannherz H.G. (1985). Isolation of 5'-nucleotidase from chicken gizzard, its properties, and subcellular localization in chicken tissues using monospecific antibodies. *Eur. J. Cell Biol.* 37, 122-129.
- Hellsten-Westing Y. (1993). Immunohistochemical localization of xanthine oxidase in human cardiac and skeletal muscle. *Histochemistry* 100, 215-222.
- Higuchi I., Ishiura S., Nonaka I. and Sugita H. (1987). Immunohistochemical localization of AMP deaminase in rimmed vacuoles in human skeletal muscle. *Muscle Nerve* 10, 790-800.
- Hilton D.A., Eagles M.E. and Fletcher A. (1991). Histochemical demonstration of 5'-nucleotidase activity in inflammatory muscle disease. *Arch. Pathol. Lab. Med.* 115, 362-364.
- Hussain S.T. and Baydoun E.A.H. (1985). Cytochemical localization of 5'-nucleotidase in the frog (*Rana pipiens*) retina; A histochemical and cytochemical study. *J. Histochem. Cytochem.* 33, 1067-1072.
- Ichikawa M., Nishino T., Nishino T. and Ichikawa A. (1992). Subcellular localization of xanthine oxidase in rat hepatocytes: high-resolution immunoelectron microscopic study combined with biochemical analysis. *J. Histochem. Cytochem.* 40, 1097-1103.
- Ikeda K., Iida T. and Nakagawa S. (1993). Postnatal expression of hypoxanthine guanine phosphoribosyltransferase in the mouse brain. *Enzyme Protein* 47, 65-72.
- Ikegami T. and Nishino T. (1986). The presence of desulfo xanthine dehydrogenase in purified and crude enzyme preparations from rat liver. *Arch. Biochem. Biophys.* 247, 254-260.
- Invernizzi R., De Fazio P., Fenoglio C., Ippoliti G., Zambelli L.M., Razzano M. and Ascarei E. (1990). 5'-nucleotidase in chronic B cell leukemias: a cytochemical and ultrastructural study. *Am. J. Hematol.* 34, 37-43.
- Itoh G., Ikeda H., Nakano M., Baba H. and Hayashi Y. (1984). Detection of purine nucleoside phosphorylase in paraffin sections by the immunoperoxidase method. *J. Histochem. Cytochem.* 32, 783-787.
- Jarasch E-D., Grund C., Bruder G., Heid H.W., Keenan T.W. and Franke W.W. (1981). Localization of xanthine oxidase in mammary gland epithelium and capillary endothelium. *Cell* 25, 67-82.
- Kamatani N., Hakoda M., Otsuka S., Yoshikawa H. and Kashiwazaki S. (1992). Only three mutations account for almost all defective alleles causing adenosine phosphoribosyltransferase deficiency in Japanese patients. *J. Clin. Invest.* 90, 130-135.
- Kaur C., Ling E.A. and Wong W.C. (1984). Cytochemical localisation of 5'-nucleotidase in amoeboid microglial cells in postnatal rats. *J. Anat.* 139, 1-7.
- Kooij A. (1994). A re-evaluation of the tissue distribution and physiology of xanthine oxidoreductase. *Histochem. J.* 26, 889-915.
- Kooij A., Bosch K.S., Frederiks W.M. and van Noorden C.J.F. (1992b). High levels of xanthine oxidoreductase in rat endothelial, epithelial and connective tissue cells. *Virchows Arch. (B)* 62, 143-150.
- Kooij A., Schijns M., Frederiks W.M., van Noorden C.J.F. and James J. (1992a). Distribution of xanthine oxidoreductase activity in human tissues - a histochemical and biochemical study. *Virchows Arch. (B)* 63, 17-23.
- Kramar R., Goldenberg H., Bock P. and Klobucar N. (1974). Peroxisomes in the liver of the carp (*Cyprinus carpio* L.). Electron microscopic cytochemical and biochemical studies. *Histochemistry* 40, 137-154.
- Krenitsky T.A. (1978). Aldehyde oxidase and xanthine oxidase - functional and evolutionary relationships. *Biochem. Pharmacol.* 27, 2763-2764.
- Krenitsky T.A., Neil S.M., Elion G.B. and Hitchings G.H. (1972). A comparison of the specificities of xanthine oxidase and aldehyde oxidase. *Arch. Biochem. Biophys.* 150, 585-599.
- Krenitsky T.A., Tuttle J.V., Cattau E.L. Jr and Wang P. (1974). A comparison of the distribution and electron acceptor specificities of xanthine oxidase and aldehyde oxidase. *Comp. Biochem. Physiol.* 49B, 687-703.
- Le Hir M. and Kaissling B. (1989). Distribution of 5'-nucleotidase in the renal interstitium of the rat. *Cell Tissue Res.* 258, 177-182.
- Le Hir M. and Kaissling B. (1993). Distribution and regulation of renal ecto-5'-nucleotidase: implications for physiological functions of adenosine. *Am. J. Physiol.* 264, F377-F387.
- Little J. and Widnell C.C. (1975). Evidence for the translocation of 5'-nucleotidase across hepatic membranes *in vivo*. *Proc. Natl. Acad. Sci. USA* 72, 4013-4017.
- Magnusson B.C., Heyden G. and Svensson S.E. (1974). Histochemical observations on 5'-nucleotidase activity in squamous cell carcinomas of the rat. *Histochemistry* 42, 1-8.
- Markert M.L. (1991). Purine nucleoside deficiency. *Immunodef. Rev.* 3, 45-81.
- Masuzawa T., Shimabukuro H. and Sato F. (1982). Enzyme histochemistry of ventricular choroid plexus (Part V): Localization of nucleoside phosphatase and 5'-nucleotidase activities. *Neurol. Med. Chir. (Tokyo)* 22, 875-878.
- McCord J.M. (1985). Oxygen-derived free radicals in postischemic tissue injury. *N. Engl. J. Med.* 312, 159-163.
- McIndoe W.M., Wight P.A.L. and MacKenzie G.M. (1974). Histochemical demonstration of xanthine dehydrogenase in the tissue of domestic fowl. *Histochem. J.* 6, 339-345.
- Mentzer R.M. Jr., Rubio R. and Berne R.M. (1975). Release of adenosine by hypoxic canine lung tissue and its possible role in pulmonary circulation. *Am. J. Physiol.* 229, 1625-1631.
- Meyer R.A., Gilloteaux J. and Terjung R.L. (1980). Histochemical demonstration of differences in AMP deaminase activity in rat skeletal muscle-fibers. *Experientia* 36, 676-677.
- Mohamedali K.A., Guicherit O.M., Kellems R.E. and Rudolph F.B. (1993). The highest levels of purine catabolic enzymes in mice are present in the proximal small intestine. *J. Biol. Chem.* 268, 23728-23733.
- Moriwaki Y., Kohjiro N., Itoh M., Nakatsuji Y., Okada M., Ishihara H., Tachibana I. and Kokubu T. (1989). Discrimination of tuberculous from carcinomatous pleural effusion by biochemical markers: Adenosine deaminase, lysozyme, fibronectin and carcinoembryonic antigen. *Jpn. J. Med.* 28, 478-484.
- Moriwaki Y., Yamamoto T., Nasako Y., Takahashi S., Suda M., Hiroishi K., Hada T. and Higashino. (1993). *In vitro* oxidation of pyrazinamide and allopurinol by rat liver aldehyde oxidase. *Biochem. Pharmacol.* 46, 975-981.
- Moriwaki Y., Yamamoto T., Yamaguchi K., Takahashi S. and Higashino K. (1996a). Immunohistochemical localization of aldehyde and xanthine oxidase in rat tissues using polyclonal antibodies. *Histochem. Cell Biol.* 105, 71-79.
- Moriwaki Y., Yamamoto T., Yamaguchi K., Suda M., Yamakita J., Takahashi S. and Higashino K. (1996b). Immunohistochemical

Enzymes of the purine metabolism

- localization of xanthine oxidase in human tissues. *Acta. Histochem. Cytochem.* 29, 153-162.
- Moriwaki Y., Yamamoto T. and Higashino K. (1997). Distribution and pathophysiologic role of molybdenum-containing enzymes. *Histol. Histopathol.* 12, 513-524.
- Moriwaki Y., Yamamoto T., Yamakita J., Takahashi S. and Higashino K. (1998). Comparative localization of aldehyde oxidase and xanthine oxidoreductase activity in rat tissues. *Histochem. J.* 30, 69-74.
- Motojima K. and Goto S. (1990). Characterization of liver-specific expression of rat uricase using monoclonal antibodies and cloned cDNAs. *Biochim. Biophys. Acta* 1087, 316-322.
- Nagao H., Habara S., Morimoto T., Sano N., Takahashi M., Kida K. and Matsuda H. (1986). AMP deaminase activity of skeletal muscle in neuromuscular disorders in childhood. *Histochemical and biochemical studies. Neuropediatrics* 17, 193-198.
- Nagy J.I., LaBella L.A. and Buss M. (1984). Immunohistochemistry of adenosine deaminase: Implications for adenosine neurotransmission. *Science* 224, 166-168.
- Nakajima Y. and Bourne G.H. (1970). Histochemical studies on urate oxidase in several mammals with special reference to uricolytic ability of primates. *Histochemie* 22, 20-24.
- Noguchi T., Takada Y. and Fujiwara S. (1979). Degradation of uric acid to urea and glyoxylate in peroxisomes. *J. Biol. Chem.* 254, 5272-5275.
- Oliver J.M., Osborne W.R., Pfeiffer J.R., Child F.M. and Berlin R.D. (1981). Purine nucleoside phosphorylase is associated with centrioles and basal bodies. *J. Cell Biol.* 91, 837-847.
- Osada Y., Tsuchimoto M., Fukushima H., Takahashi K., Kondo S., Hasegawa M. and Komoriya K. (1993). Hypouricemic effect of the novel xanthine oxidase inhibitor, TEI-6720, in rodents. *Eur. J. Pharmacol.* 241, 183-188.
- Palella T.D. and Fox I.H. (1989). Hyperuricemia and gout. In: *The metabolic basis of inherited disease*. Vol. 1. 6th ed. Scriver C.R., Beaudet A.L., Sly W.S. and Valle D. (eds). McGraw-Hill. New York. p 965.
- Pawelczyk T. and Angielski S. (1988). Activities of the enzymes involved in the purine nucleotide cycle in the rat kidney cortex and medulla. *Kidney Int.* 33, 393.
- Pruslin F.H. and Reem G.H. (1980). Immunofluorescence; A sensitive and rapid method for the detection of purine nucleoside phosphorylase in single cells. *J. Immunol. Meth.* 34, 127-132.
- Rasanen L.A., Karvonen U. and Poso A.R. (1993). Localization of xanthine dehydrogenase mRNA in horse skeletal muscle by *in situ* hybridization with digoxigenin-labeled probe. *Biochem. J.* 292, 639-641.
- Robinson J.M. and Karnovsky M.J. (1983). Ultrastructural localization of 5'-nucleotidase in guinea pig neutrophils based upon the use of cerium as capturing agent. *J. Histochem. Cytochem.* 31, 1190-1196.
- Rodan G.A., Bourret L.A. and Cutler L.S. (1977). Membrane changes during cartilage maturation. Increase in 5'-nucleotidase and decrease in adenosine inhibition of adenylate cyclase. *J. Cell Biol.* 72, 493-501.
- Rohr G. and Mannherz H.G. (1979). The activation of actin: DNase I complex with rat liver plasma membranes. The possible role of 5'-nucleotidase. *FEBS Lett.* 99, 351-356.
- Ronchetti R., Lucarini N., Lucarelli P., Martinez F., Macri F., Carapella E. and Bottini E. (1984). A genetic basis for heterogeneity of asthma syndrome in pediatric ages: adenosine deaminase phenotypes. *J. Allergy Clin. Immunol.* 74, 81-84.
- Rubio R., Berne R.M. and Dobson J.G. Jr. (1973). Sites of adenosine production in cardiac and skeletal muscle. *Am. J. Physiol.* 225, 938-953.
- Rubio R. (1974). Purine nucleoside phosphorylase. In: *Electron microscopy of enzymes*. Vol. 3. Hayat. M.A. (ed). Van Nostrand Reinhold. New York. p 54-67.
- Rubio R. and Berne R.M. (1980). Localization of purine and pyrimidine nucleoside phosphorylase in heart, kidney, and liver. *Am. J. Physiol.* 239, H721-H730.
- Rubio R., Berne R.M. and Winn H.R. (1978). Cerebral vascular smooth muscle and its control. *Ciba Foundation Symposium* 56. Elsevier. Excerpta Medica. Amsterdam: North Holland. p 355-373.
- Rubio R., Wiedmeier T. and Berne R.M. (1972). Nucleoside phosphorylase; localization and role in the myocardial distribution of purines. *Am. J. Physiol.* 222, 550-555.
- Sackler M.L. (1966). Xanthine oxidase from liver and duodenum of the rat. Histochemical localization and electrophoretic heterogeneity. *J. Histochem. Cytochem.* 14, 326-333.
- Saez J.C., Ward P.H., Gunther B. and Vivaldi E. (1984). Superoxide radical involvement in the pathogenesis of burn shock. *Circ. Shock* 12, 229-239.
- Salas J.A., Johnstone K. and Ellar D.J. (1985). Role of uricase in the triggering of germination of *Bacillus fastidiosus* spores. *Biochem. J.* 229, 241-249.
- Samra Z.Q., Oguro T., Fontaine R. and Ashraf M. (1991). Immunocytochemical localization of xanthine oxidase in rat myocardium. *J. Submicrosc. Cytol. Pathol.* 23, 379-390.
- Sato S., Tatsumi K. and Nishino T. (1991). A novel xanthine dehydrogenase inhibitor (BOF-4272). *Adv. Exp. Med. Biol.* 309A, 135-138.
- Schad A., Fahimi H.D., Volkl A. and Baumgart E. (1996). Nonradioactive detection of mRNA encoding for peroxisomal proteins: heterogeneous hepatic lobular distribution after treatment with a single dose of bezafibrate. *J. Histochem. Cytochem.* 44, 825-834.
- Schmid T.C., Loffing J., Le Hir M. and Kaissling B. (1994). Distribution of ecto-5'-nucleotidase in the rat liver: effect of anaemia. *Histochemistry* 101, 439-447.
- Schoen S.W., Graeber M.B., Toth L. and Kreutzberg G.W. (1988). 5'-nucleotidase in postnatal ontogeny of rat cerebellum: a marker for migrating nerve cells? *Dev. Brain Res.* 39, 125-136.
- Schoen S.W., Kreutzberg G.W. and Singer W. (1993). Cytochemical redistribution of 5'-nucleotidase in the developing cat visual cortex. *Eur. J. Neurosci.* 5, 210-222.
- Schrader W.P. and West C.A. (1990). Localization of adenosine deaminase and adenosine deaminase complexing protein in rabbit heart. *Circ. Res.* 66, 754-762.
- Schrader W.P., West C.A. and Strominger N.L. (1987). Localization of adenosine deaminase and adenosine deaminase complexing protein in rabbit brain. *J. Histochem. Cytochem.* 35, 443-451.
- Schubert P., Komp W. and Kreutzberg G.W. (1979). Correlation of 5'-nucleotidase activity and selective transneuronal transfer of adenosine in the hippocampus. *Brain Res.* 168, 419-424.
- Schultz V. and Lowenstein J.M. (1976). Purine nucleotide cycle. Evidence for the occurrence of the cycle in brain. *J. Biol. Chem.* 251, 485-492.
- Sculley D.G., Dawson P.A., Beacham I.R., Emmerson B.T. and Gordon R.B. (1991). Hypoxanthine-guanine phosphoribosyltransferase deficiency: analysis of HPRT mutations by direct sequencing and allele-specific amplification. *Hum. Genet.* 87, 688-692.
- SenGupta S., Petsche D., Gelfand E.W. and Chechik B.E. (1985). A

Enzymes of the purine metabolism

- ribosyltransferase activity in tissues and hypoxanthine concentrations in plasma and CSF of the horse in comparison with other species. *Comp. Biochem. Physiol.* 97B, 591-596.
- Hattori Y. (1989). Localization of xanthine dehydrogenase in chicken liver. *Acta. Histochem. Cytochem.* 22, 617-624.
- Heidemann M., Dieckhoff J., Hlavsa C. and Mannherz H.G. (1985). Isolation of 5'-nucleotidase from chicken gizzard, its properties, and subcellular localization in chicken tissues using monospecific antibodies. *Eur. J. Cell Biol.* 37, 122-129.
- Hellsten-Westing Y. (1993). Immunohistochemical localization of xanthine oxidase in human cardiac and skeletal muscle. *Histochemistry* 100, 215-222.
- Higuchi I., Ishiura S., Nonaka I. and Sugita H. (1987). Immunohistochemical localization of AMP deaminase in rimmed vacuoles in human skeletal muscle. *Muscle Nerve* 10, 790-800.
- Hilton D.A., Eagles M.E. and Fletcher A. (1991). Histochemical demonstration of 5'-nucleotidase activity in inflammatory muscle disease. *Arch. Pathol. Lab. Med.* 115, 362-364.
- Hussain S.T. and Baydoun E.A.H. (1985). Cytochemical localization of 5'-nucleotidase in the frog (*Rana pipiens*) retina; A histochemical and cytochemical study. *J. Histochem. Cytochem.* 33, 1067-1072.
- Ichikawa M., Nishino T., Nishino T. and Ichikawa A. (1992). Subcellular localization of xanthine oxidase in rat hepatocytes: high-resolution immunoelectron microscopic study combined with biochemical analysis. *J. Histochem. Cytochem.* 40, 1097-1103.
- Ikeda K., Iida T. and Nakagawa S. (1993). Postnatal expression of hypoxanthine guanine phosphoribosyltransferase in the mouse brain. *Enzyme Protein* 47, 65-72.
- Ikegami T. and Nishino T. (1986). The presence of desulfo xanthine dehydrogenase in purified and crude enzyme preparations from rat liver. *Arch. Biochem. Biophys.* 247, 254-260.
- Invernizzi R., De Fazio P., Fenoglio C., Ippoliti G., Zambelli L.M., Razzano M. and Ascari E. (1990). 5'-nucleotidase in chronic B cell leukemias: a cytochemical and ultrastructural study. *Am. J. Hematol.* 34, 37-43.
- Itoh G., Ikeda H., Nakano M., Baba H. and Hayashi Y. (1984). Detection of purine nucleoside phosphorylase in paraffin sections by the immunoperoxidase method. *J. Histochem. Cytochem.* 32, 783-787.
- Jarasch E-D., Grund C., Bruder G., Heid H.W., Keenan T.W. and Franke W.W. (1981). Localization of xanthine oxidase in mammary gland epithelium and capillary endothelium. *Cell* 25, 67-82.
- Kamatani N., Hakoda M., Otsuka S., Yoshikawa H. and Kashiwazaki S. (1992). Only three mutations account for almost all defective alleles causing adenine phosphoribosyltransferase deficiency in Japanese patients. *J. Clin. Invest.* 90, 130-135.
- Kaur C., Ling E.A. and Wong W.C. (1984). Cytochemical localisation of 5'-nucleotidase in amoeboid microglial cells in postnatal rats. *J. Anat.* 139, 1-7.
- Kooij A. (1994). A re-evaluation of the tissue distribution and physiology of xanthine oxidoreductase. *Histochem. J.* 26, 889-915.
- Kooij A., Bosch K.S., Frederiks W.M. and van Noorden C.J.F. (1992b). High levels of xanthine oxidoreductase in rat endothelial, epithelial and connective tissue cells. *Virchows Arch. (B)* 62, 143-150.
- Kooij A., Schijns M., Frederiks W.M., van Noorden C.J.F. and James J. (1992a). Distribution of xanthine oxidoreductase activity in human tissues - a histochemical and biochemical study. *Virchows Arch. (B)* 63, 17-23.
- Kramar R., Goldenberg H., Bock P. and Klobucar N. (1974). Peroxisomes in the liver of the carp (*Cyprinus carpio* L.). Electron microscopic cytochemical and biochemical studies. *Histochemistry* 40, 137-154.
- Krenitsky T.A. (1978). Aldehyde oxidase and xanthine oxidase - functional and evolutionary relationships. *Biochem. Pharmacol.* 27, 2763-2764.
- Krenitsky T.A., Neil S.M., Elion G.B. and Hitchings G.H. (1972). A comparison of the specificities of xanthine oxidase and aldehyde oxidase. *Arch. Biochem. Biophys.* 150, 585-599.
- Krenitsky T.A., Tuttle J.V., Cattau E.L. Jr and Wang P. (1974). A comparison of the distribution and electron acceptor specificities of xanthine oxidase and aldehyde oxidase. *Comp. Biochem. Physiol.* 49B, 687-703.
- Le Hir M. and Kaissling B. (1989). Distribution of 5'-nucleotidase in the renal interstitium of the rat. *Cell Tissue Res.* 258, 177-182.
- Le Hir M. and Kaissling B. (1993). Distribution and regulation of renal ecto-5'-nucleotidase: implications for physiological functions of adenosine. *Am. J. Physiol.* 264, F377-F387.
- Little J. and Widnell C.C. (1975). Evidence for the translocation of 5'-nucleotidase across hepatic membranes *in vivo*. *Proc. Natl. Acad. Sci. USA* 72, 4013-4017.
- Magnusson B.C., Heyden G. and Svensson S.E. (1974). Histochemical observations on 5'-nucleotidase activity in squamous cell carcinomas of the rat. *Histochemistry* 42, 1-8.
- Markert M.L. (1991). Purine nucleoside deficiency. *Immunodef. Rev.* 3, 45-81.
- Masuzawa T., Shimabukuro H. and Sato F. (1982). Enzyme histochemistry of ventricular choroid plexus (Part V): Localization of nucleoside phosphatase and 5'-nucleotidase activities. *Neurol. Med. Chir. (Tokyo)* 22, 875-878.
- McCord J.M. (1985). Oxygen-derived free radicals in postischemic tissue injury. *N. Engl. J. Med.* 312, 159-163.
- McIndoe W.M., Wight P.A.L. and MacKenzie G.M. (1974). Histochemical demonstration of xanthine dehydrogenase in the tissue of domestic fowl. *Histochem. J.* 6, 339-345.
- Mentzer R.M. Jr., Rubio R. and Berne R.M. (1975). Release of adenosine by hypoxic canine lung tissue and its possible role in pulmonary circulation. *Am. J. Physiol.* 229, 1625-1631.
- Meyer R.A., Gilloteaux J. and Terjung R.L. (1980). Histochemical demonstration of differences in AMP deaminase activity in rat skeletal muscle-fibers. *Experientia* 36, 676-677.
- Mohamedali K.A., Guicherit O.M., Kellems R.E. and Rudolph F.B. (1993). The highest levels of purine catabolic enzymes in mice are present in the proximal small intestine. *J. Biol. Chem.* 268, 23728-23733.
- Moriwaki Y., Kohjiro N., Itoh M., Nakatsuji Y., Okada M., Ishihara H., Tachibana I. and Kokubu T. (1989). Discrimination of tuberculous from carcinomatous pleural effusion by biochemical markers: Adenosine deaminase, lysozyme, fibronectin and carcinoembryonic antigen. *Jpn. J. Med.* 28, 478-484.
- Moriwaki Y., Yamamoto T., Nasako Y., Takahashi S., Suda M., Hiroishi K., Hada T. and Higashino. (1993). *In vitro* oxidation of pyrazinamide and allopurinol by rat liver aldehyde oxidase. *Biochem. Pharmacol.* 46, 975-981.
- Moriwaki Y., Yamamoto T., Yamaguchi K., Takahashi S. and Higashino K. (1996a). Immunohistochemical localization of aldehyde and xanthine oxidase in rat tissues using polyclonal antibodies. *Histochem. Cell Biol.* 105, 71-79.
- Moriwaki Y., Yamamoto T., Yamaguchi K., Suda M., Yamakita J., Takahashi S. and Higashino K. (1996b). Immunohistochemical

Enzymes of the purine metabolism

- localization of xanthine oxidase in human tissues. *Acta. Histochem. Cytochem.* 29, 153-162.
- Moriwaki Y., Yamamoto T. and Higashino K. (1997). Distribution and pathophysiological role of molybdenum-containing enzymes. *Histol. Histopathol.* 12, 513-524.
- Moriwaki Y., Yamamoto T., Yamakita J., Takahashi S. and Higashino K. (1998). Comparative localization of aldehyde oxidase and xanthine oxidoreductase activity in rat tissues. *Histochem. J.* 30, 69-74.
- Motojima K. and Goto S. (1990). Characterization of liver-specific expression of rat uricase using monoclonal antibodies and cloned cDNAs. *Biochim. Biophys. Acta* 1087, 316-322.
- Nagao H., Habara S., Morimoto T., Sano N., Takahashi M., Kida K. and Matsuda H. (1986). AMP deaminase activity of skeletal muscle in neuromuscular disorders in childhood. *Histochemical and biochemical studies. Neuropediatrics* 17, 193-198.
- Nagy J.I., LaBella L.A. and Buss M. (1984). Immunohistochemistry of adenosine deaminase: Implications for adenosine neurotransmission. *Science* 224, 166-168.
- Nakajima Y. and Bourne G.H. (1970). Histochemical studies on urate oxidase in several mammals with special reference to uricolytic ability of primates. *Histochemie* 22, 20-24.
- Noguchi T., Takada Y. and Fujiwara S. (1979). Degradation of uric acid to urea and glyoxylate in peroxisomes. *J. Biol. Chem.* 254, 5272-5275.
- Oliver J.M., Osborne W.R., Pfeiffer J.R., Child F.M. and Berlin R.D. (1981). Purine nucleoside phosphorylase is associated with centrioles and basal bodies. *J. Cell Biol.* 91, 837-847.
- Osada Y., Tsuchimoto M., Fukushima H., Takahashi K., Kondo S., Hasegawa M. and Komoriya K. (1993). Hypouricemic effect of the novel xanthine oxidase inhibitor, TEI-6720, in rodents. *Eur. J. Pharmacol.* 241, 183-188.
- Parella T.D. and Fox I.H. (1989). Hyperuricemia and gout. In: *The metabolic basis of inherited disease*. Vol. 1. 6th ed. Scriver C.R., Beaudet A.L., Sly W.S. and Valle D. (eds). McGraw-Hill. New York. p 965.
- Pawelczyk T. and Angielski S. (1988). Activities of the enzymes involved in the purine nucleotide cycle in the rat kidney cortex and medulla. *Kidney Int.* 33, 393.
- Pruslin F.H. and Reem G.H. (1980). Immunofluorescence; A sensitive and rapid method for the detection of purine nucleoside phosphorylase in single cells. *J. Immunol. Meth.* 34, 127-132.
- Rasanen L.A., Karvonen U. and Poso A.R. (1993). Localization of xanthine dehydrogenase mRNA in horse skeletal muscle by *in situ* hybridization with digoxigenin-labeled probe. *Biochem. J.* 292, 639-641.
- Robinson J.M. and Karnovsky M.J. (1983). Ultrastructural localization of 5'-nucleotidase in guinea pig neutrophils based upon the use of cerium as capturing agent. *J. Histochem. Cytochem.* 31, 1190-1196.
- Rodan G.A., Bourret L.A. and Cutler L.S. (1977). Membrane changes during cartilage maturation. Increase in 5'-nucleotidase and decrease in adenosine inhibition of adenylate cyclase. *J. Cell Biol.* 72, 493-501.
- Rohr G. and Mannherz H.G. (1979). The activation of actin: DNase I complex with rat liver plasma membranes. The possible role of 5'-nucleotidase. *FEBS Lett.* 99, 351-356.
- Ronchetti R., Lucarini N., Lucarelli P., Martinez F., Macri F., Carapella E. and Bottini E. (1984). A genetic basis for heterogeneity of asthma syndrome in pediatric ages: adenosine deaminase phenotypes. *J. Allergy Clin. Immunol.* 74, 81-84.
- Rubio R., Berne R.M. and Dobson J.G. Jr. (1973). Sites of adenosine production in cardiac and skeletal muscle. *Am. J. Physiol.* 225, 938-953.
- Rubio R. (1974). Purine nucleoside phosphorylase. In: *Electron microscopy of enzymes*. Vol. 3. Hayat. M.A. (ed). Van Nostrand Reinhold. New York. p 54-67.
- Rubio R. and Berne R.M. (1980). Localization of purine and pyrimidine nucleoside phosphorylase in heart, kidney, and liver. *Am. J. Physiol.* 239, H721-H730.
- Rubio R., Berne R.M. and Winn H.R. (1978). Cerebral vascular smooth muscle and its control. *Ciba Foundation Symposium* 56. Elsevier. Excerpta Medica. Amsterdam: North Holland. p 355-373.
- Rubio R., Wiedmeier T. and Berne R.M. (1972). Nucleoside phosphorylase; localization and role in the myocardial distribution of purines. *Am. J. Physiol.* 222, 550-555.
- Sackler M.L. (1966). Xanthine oxidase from liver and duodenum of the rat. Histochemical localization and electrophoretic heterogeneity. *J. Histochem. Cytochem.* 14, 326-333.
- Saez J.C., Ward P.H., Gunther B. and Vivaldi E. (1984). Superoxide radical involvement in the pathogenesis of burn shock. *Circ. Shock* 12, 229-239.
- Salas J.A., Johnstone K. and Ellar D.J. (1985). Role of uricase in the triggering of germination of *Bacillus fastidiosus* spores. *Biochem. J.* 229, 241-249.
- Samra Z.Q., Oguro T., Fontaine R. and Ashraf M. (1991). Immunocytochemical localization of xanthine oxidase in rat myocardium. *J. Submicrosc. Cytol. Pathol.* 23, 379-390.
- Sato S., Tatsumi K. and Nishino T. (1991). A novel xanthine dehydrogenase inhibitor (BOF-4272). *Adv. Exp. Med. Biol.* 309A, 135-138.
- Schad A., Fahimi H.D., Volkl A. and Baumgart E. (1996). Nonradioactive detection of mRNA encoding for peroxisomal proteins: heterogeneous hepatic lobular distribution after treatment with a single dose of bezafibrate. *J. Histochem. Cytochem.* 44, 825-834.
- Schmid T.C., Löffing J., Le Hir M. and Kaissling B. (1994). Distribution of ecto-5'-nucleotidase in the rat liver: effect of anaemia. *Histochemistry* 101, 439-447.
- Schoen S.W., Graeber M.B., Toth L. and Kreutzberg G.W. (1988). 5'-nucleotidase in postnatal ontogeny of rat cerebellum: a marker for migrating nerve cells? *Dev. Brain Res.* 39, 125-136.
- Schoen S.W., Kreutzberg G.W. and Singer W. (1993). Cytochemical redistribution of 5'-nucleotidase in the developing cat visual cortex. *Eur. J. Neurosci.* 5, 210-222.
- Schrader W.P. and West C.A. (1990). Localization of adenosine deaminase and adenosine deaminase complexing protein in rabbit heart. *Circ. Res.* 66, 754-762.
- Schrader W.P., West C.A. and Strominger N.L. (1987). Localization of adenosine deaminase and adenosine deaminase complexing protein in rabbit brain. *J. Histochem. Cytochem.* 35, 443-451.
- Schubert P., Komp W. and Kreutzberg G.W. (1979). Correlation of 5'-nucleotidase activity and selective transneuronal transfer of adenosine in the hippocampus. *Brain Res.* 168, 419-424.
- Schultz V. and Lowenstein J.M. (1976). Purine nucleotide cycle. Evidence for the occurrence of the cycle in brain. *J. Biol. Chem.* 251, 485-492.
- Sculley D.G., Dawson P.A., Beacham I.R., Emerson B.T. and Gordon R.B. (1991). Hypoxanthine-guanine phosphoribosyltransferase deficiency: analysis of HPRT mutations by direct sequencing and allele-specific amplification. *Hum. Genet.* 87, 688-692.
- SenGupta S., Petsche D., Gelfand E.W. and Chechik B.E. (1985). A

Enzymes of the purine metabolism

- flow cytometric method for the detection of adenosine deaminase in mononuclear cells. *J. Immunol. Meth.* 80, 155-162.
- Stefanovich V. (1982). Effects of administration of adenosine on cerebral energy metabolite levels in rats during 30s of anoxia. *IRCS Medical Science: Biochemistry: Cardiovascular System; Pharmacology; Physiology; Psychology and Psychiatry* 10, 1046.
- Stoop J.W., Zegers B.J.M., Hendrickx G.F.M., Siegenbeck van Heukelom H.L., Staal G.E.J., Wadman S.K. and Ballieux R.E. (1977). Purine nucleoside phosphorylase deficiency associated with selective cellular immunodeficiency. *N. Engl. J. Med.* 296, 651-655.
- Sullivan J.L., Osborn W.R.A and Wedgewood R.J. (1977). Adenosine deaminase activity in lymphocytes. *Br. J. Haematol.* 37, 157-158.
- Takada Y. and Noguchi T. (1986). Ureidoglycollate lyase, a new metalloenzyme of peroxisomal urate degradation in marine fish liver. *Biochem. J.* 235, 391-397.
- Terao M., Cazzaniga G., Ghezzi P., Bianchi M., Falciani F., Perani P. and Garatini E. (1992). Molecular cloning of a cDNA coding for mouse liver xanthine dehydrogenase. *Biochem. J.* 283, 863-870.
- Thomas J. and Trelease R.N. (1981). Cytochemical localization of glycolate oxidase in microbodies (glyoxisomes and peroxisomes) of higher plant tissue with the $CeCl_3$ technique. *Protoplasma* 108, 39-53.
- Thompson J.L., Sabina R.L., Ogasawara N. and Riley D.A. (1992). AMP deaminase histochemical activity and immunofluorescent isozyme localization in rat skeletal muscle. *J. Histochem. Cytochem.* 40, 931-946.
- Thompson L.F., Ruedi J.M., Low M.G. and Clement L.T. (1987). Distribution of ecto-5'-nucleotidase on subsets of human T and B lymphocytes as detected by indirect immunofluorescence using goat antibodies. *J. Immunol.* 139, 4042-4048.
- Trotta P.P and Balis M.E. (1977). Structural and kinetic alterations in adenosine deaminase associated with the differentiation of rat intestinal cells. *Cancer Res.* 37, 2297-2305.
- Tubaro E., Lotti B., Cavallo G., Croce C. and Borelli G. (1980a). Liver xanthine oxidase increase in mice in three pathological models. *Biochem. Pharmacol.* 29, 1939-1943.
- Tubaro E., Lotti B., Santiangeli C. and Cavallo G. (1980b). Xanthine oxidase increase in polymorphonuclear leukocytes and macrophage in mice in three pathological situations. *Biochem. Pharmacol.* 29, 1945-1948.
- Tubaro E., Lotti B., Santiangeli C. and Cavallo G. (1980c). Xanthine oxidase: an enzyme playing a role in the killing mechanism of polymorphonuclear leukocytes. *Biochem. Pharmacol.* 29, 3018-3020.
- Usuda N., Reddy M.K., Hashimoto K., Rao M.S. and Reddy J.K. (1988a). Tissue specificity and species differences in the distribution of urate oxidase in peroxisomes. *Lab. Invest.* 58, 100-111.
- Usuda N., Usman M.I., Reddy M.K., Hashimoto T., Reddy J.K. and Rao M.S. (1988b). Immunocytochemical localization of urate oxidase, fatty acyl CoA oxidase and catalase in bovine kidney peroxisomes. *J. Histochem. Cytochem.* 36, 253-258.
- Uusitalo R.J. and Karnovsky M.J. (1977). 5'-nucleotidase in different populations of mouse lymphocytes. *J. Histochem. Cytochem.* 25, 97-103.
- Van den Bosch K.A. (1986). Light and electron microscopic visualization of uricase by immunogold labelling of sections of resin-embedded soybean nodules. *J. Microsc.* 143, 187-197.
- Van den Munckhof R.J.M., Vreeling-Sindelarova H., Schellens J.P.M. and Frederiks W.M. (1994). Localization of uric acid oxidase activity in core and matrix of peroxisomes as detected in unfixed cryostat sections of rat liver. *J. Histochem. Cytochem.* 42, 177-183.
- Van den Munckhof R.J.M., Vreeling-Sindelarova H., Schellens J.P.M., van Noorden C.J.F. and Frederiks W.M. (1995). Ultrastructural localization of xanthine oxidase activity in the digestive tract of the rat. *Histochem. J.* 27, 897-905.
- Van der Weyden M.B. and Kelley W.N. (1976). Human adenosine deaminase. Distribution and properties. *J. Biol. Chem.* 251, 5446-5456.
- Van Reempts J., Van Deuren B., Haseldonkx M., Van de Ven M., Thone F. and Borgers M. (1988). Purine nucleoside phosphorylase; a histochemical marker for glial cells. *Brain Res.* 462, 142-147.
- Vaughn K.C., Duke S.O. Duke S.H. and Henson C.A. (1982). Ultrastructural localization of urate oxidase in nodules of *Sesbania exaltata*, *Glycine max*, and *Medicago sativa*. *Histochemistry* 74, 309-318.
- Veenhuis M. and Wendelaar Bonga S.E. (1979). Cytochemical localization of catalase and several hydrogen peroxide-producing oxidases in the nucleoids and matrix of rat liver peroxisomes. *Histochem. J.* 11, 561-572.
- Volkl A., Baumgart E. and Fahimi H.D. (1988). Localization of urate oxidase in the crystalline cores of rat liver peroxisomes by immunocytochemistry and immunoblotting. *J. Histochem. Cytochem.* 36, 329-336.
- Wada I., Eto S., Himeno M. and Kato K. (1987). 5'-nucleotidase in rat liver lysosomes. *J. Biochem.* 101, 1077-1085.
- Watt W.B. (1972). Xanthine dehydrogenase and pteridine metabolism in *Colias* butterflies. *J. Biol. Chem.* 247, 1445-1451.
- Widnell C.C. (1972). Cytochemical localization of 5'-nucleotidase in subcellular fractions isolated from rat liver. I. The origin of 5'-nucleotidase activity in microsomes. *J. Cell Biol.* 52, 542-558.
- Wilson P.D. and Hodges G.M. (1979). Focal distribution of surface marker enzymes after long-term culture of adult rat bladder epithelium and methylnitrosourea (MNU)-induced bladder tumors. *J. Histochem. Cytochem.* 27, 1236-1246.
- Witte D.P., Wiginton D.A., Hutton J.J. and Aronow B.J. (1991). Coordinate developmental regulation of purine catabolic enzyme expression in gastrointestinal and postimplantation reproductive tracts. *J. Cell. Biol.* 115, 179-190.
- Wyngaarden J.B. and Kelley W.N. (1976). *Gout and hyperuricemia*. Grune & Stratton. New York.
- Xu P., Huecksteadt T.P., Harrison R. and Hoidal J.R. (1994). Molecular cloning, tissue expression of human xanthine dehydrogenase. *Biochem. Biophys. Res. Commun.* 199, 998-1004.
- Yamamoto K. and Fahimi H.D. (1987). Biogenesis of peroxisomes in regenerating rat liver. I. Sequential changes of catalase and urate oxidase detected by ultrastructural cytochemistry. *Eur. J. Cell Biol.* 43, 293-300.
- Yamamoto T., Geiger J.D., Daddona P.E. and Nagy J.I. (1987). Subcellular, regional and immunohistochemical localization of adenosine deaminase in various species. *Brain Res. Bull.* 19, 473-484.
- Yamamoto T., Kario K., Suda M., Moriwaki Y., Takahashi S. and Higashino K. (1991). A case of xanthinuria: a study on the metabolism of pyrazinamide and allopurinol. *Jpn. J. Med.* 30, 430-434.
- Yamamoto T., Moriwaki Y., Suda M., Takahashi S., Hada T., Nanahoshi M., Agbedana E.O. and Higashino K. (1992). An immunoreactive xanthine oxidase protein-possessing xanthinuria and her family.

Enzymes of the purine metabolism

- Clin. Chim. Acta 208, 93-98.
- Yip L.C., Chang V. and Balis E.M. (1982). Membrane-associated purine metabolising enzyme activities of human peripheral blood cells. *Biochemistry* 21, 6972-6978.
- Yokota S. and Nagata T. (1974). Studies on mouse liver urate oxidase III. Fine localization of urate oxidase in liver cells revealed by means of ultracytomy-immunoferritin method. *Histochemistry* 39, 243-250.
- Yokota S., Oka J., Ozasa H. and Itoh R. (1988). Immunocytochemical localization of cytosol 5'-nucleotidase in chicken liver. *J. Histochem. Cytochem.* 36, 983-989.
- Zhang S.X., Kobayashi T., Okada T., Garcia del Saz E. and Seguchi H. (1991). Alkaline phosphatase, 5'-nucleotidase and magnesium-dependent adenosine triphosphatase activities in the transitional epithelium of the rat urinary bladder. *Histol. Histopathol.* 6, 309-315.
- Zimmermann H. (1992). 5'-nucleotidase: molecular structure and functional aspects. *Biochem. J.* 285, 345-365.

Accepted April 26, 1999