

HERPESVIRUS HEPATITIS IN A PIGEON IN SPAIN

Hepatitis por herpesvirus en un palomo en España

Bernabé, A.; Gómez, M.A.; Navarro, J.A.; Gómez, S.; Sánchez, J.

Histología y Anatomía Patológica, Facultad de Veterinaria, Universidad de Murcia, Apartado de correos 4021, E-30071 Murcia, Spain.

Recibido: 10 Febrero 1994
Aceptado: 6 Noviembre 1994

ABSTRACT

A male pigeon (*Columba livia*) dead with no clinical signs was investigated of having hepatitis. Light microscopy revealed intranuclear inclusion bodies, that ultrastructurally were shown to be herpesvirus-like particles. The particles were also found in the cytoplasm. These findings are consistent with previous reports of the disease in the pigeon. This is the first time the disease has been reported in Spain.

Key words: hepatitis, herpesvirus, pigeon.

RESUMEN

Se describe un caso de hepatitis por herpesvirus en un palomo que no presentó signos clínicos de enfermedad. Se observó hepatitis con cuerpos de inclusión intranucleares y, a veces, intracitoplasmáticos, que ultraestructuralmente se corresponden con partículas de naturaleza vírica, tipo herpesvirus. Esta es la primera mención de la enfermedad en España.

Palabras clave: Hepatitis, herpesvirus, palomo.

INTRODUCTION

Herpesvirus infections have been reported in a wide variety of birds, including exotic species (GÓMEZ-VILLAMANDOS *et al.*, 1991), wild birds (MARE and GRAHAM, 1973; DO-

CHERTY and HENNING, 1980) and domestic poultry (BIGGS, 1982). Pigeon herpesvirus infection has been reported in the USA (SAIK *et al.*, 1986 and additional references therein) and in different countries of Europe (CORNWELL *et al.*, 1967; JYLLING, 1967; KRUPICKA *et*

al., 1970; VETESI and TANY, 1975; VINDEVOGEL and PASTORET, 1980; LANDRE *et al.*, 1982), but not in Spain.

Histopathologic studies are the basis of diagnosed herpesvirus infection (MARTHEDAL and JYLLING, 1966; LEHNER *et al.*, 1967) and have been thoroughly corroborated by electron microscopy studies (CORNWELL *et al.*, 1967; KRUPICKA *et al.*, 1970; GÓMEZ-VILLAMANDOS *et al.*, 1991).

The clinical and pathologic signs of pigeon herpesvirus infection are variable. In general clinical signs may include depression (SAIK *et al.*, 1986), inactivity, anorexia (CORNWELL *et al.*, 1967), conjunctivitis, dyspnea, ataxia, tremors (LEHNER *et al.*, 1967), mucoid nasal discharge (SAIK *et al.*, 1986; THOMPSON *et al.*, 1976), emaciation, cachexia (SAIK *et al.*, 1986) and green, loose droppings (CALLINAN *et al.*, 1979; SAIK *et al.*, 1986). The major pathologic changes associated with a herpesvirus infection consist of multifocal necrosis in the liver and spleen with formation of eosinophilic intranuclear inclusion bodies (GÓMEZ-VILLAMANDOS *et al.*, 1991).

The purpose of the present paper is to report the appearance of a case of herpes viral hepatitis in a pigeon of the region of Murcia (Spain) and to describe the anatomopathological signs.

MATERIAL AND METHODS

An adult male pigeon (*Columba livia*) dead without any clinical signs was brought to the Service of Pathology of the Veterinary Faculty of Murcia. Other animals living together with it had died also without any clinical signs. The necropsy showed hepatomegaly and a scattered focal yellowish decoloration (1-3 mm) of the liver. Except for the enlargement of the intestine with vascular injection no other abnormalities were found.

Samples from various organs (liver, lung, spleen, kidney, intestine) were fixed in 10% buffered formalin, processed by routine methods

for paraffin sectioning, sectioned at 3 to 4 μm , and stained by the hematoxylin-eosin. For the ultrastructural study small pieces of tissue were washed in buffer, fixed in glutaraldehyde and post-fixed in osmium tetroxide, embedded in epoxy resin, sliced into 60 nm sections and contrasted with uranyl acetate and lead citrate.

RESULTS

No lesions were observed in organs other than liver. The histopathologic examination of this organ revealed a marked variation in size and appearance of hepatocyte nuclei and isolated necrotic cells. Many hepatocytes had enlarged nuclei which frequently contained a single intranuclear inclusion body (Fig. 1). These inclusions varied from small centrally located eosinophilic and basophilic masses, surrounded by a clear halo with peripheral chromatin margination, to larger amorphous amphophilic masses that filled up the entire nucleus. Ultrastructurally the inclusion was made up of filamentous structures irregularly arranged, granular material, and a large number of intranuclear viral particles consisting of incomplete capsids and nucleocapsids (Fig. 2). Similar viral particles were found going through the nuclear envelope and in the cytoplasm of some hepatocytes (Fig. 3, 4). Size of nucleocapsids was 130 nm in diameter, and the cores were 80 nm in diameter.

DISCUSSION

A diagnosis of hepatitis due to pigeon herpesvirus infection was based on focal necrosis of the liver, characteristic intranuclear inclusion bodies, and electron microscopy figures corresponding to herpesvirus. The ultrastructural characteristics observed are in agreement with previous reports (JYLLING, 1967; MILLER *et al.*, 1979; CARTWRIGHT *et al.*, 1985).

Most reported cases of pigeon herpesvirus infections resulted in severe disease in birds under 6 months of age (CORNWELL *et al.*,

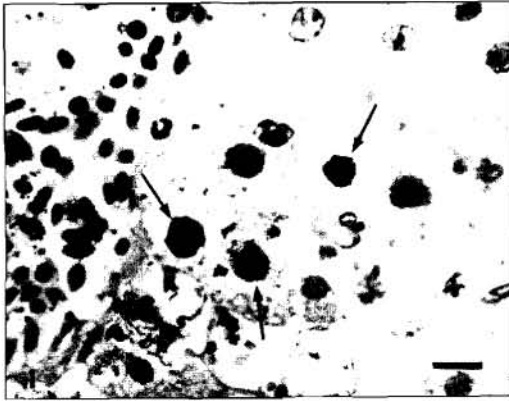


FIGURE 1. Intranuclear inclusion bodies in hepatocytes (arrows). HE. Bar: 20 nm.




FIGURE 3. Acquisition of an envelope by the viral particles on its passage through the inner nuclear membrane (arrows). Bar: 0.5 nm.

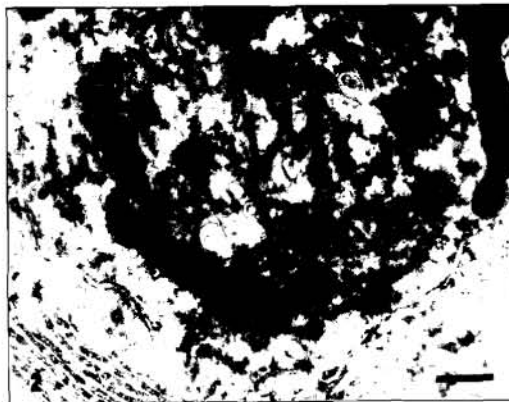


FIGURE 2. Intranuclear body showing viral particles, filamentous structures irregularly arranged and granular material. Bar: 0.5 nm.

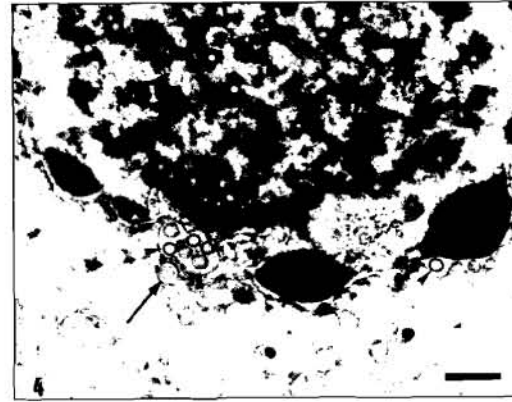


FIGURE 4. Intranuclear viral particles among the fibrillar particulate material, nuclear envelope (arrowheads) and cytoplasm (arrow). Bar: 0.5 nm.

1967; THOMPSON *et al.*, 1976; CALLINAN *et al.*, 1979). Although adults can be affected clinically they are often asymptomatic carriers (PANIGRAPHY and GRUMBLES, 1983). This represents a problem for controlling the infection in domestic pigeons.

The presence of acidophilic intranuclear inclusion bodies in hepatocytes is regarded as typical of herpesvirus infection. However, acidophilic and basophilic inclusion bodies have been found in this study and in other adenoviral infections (SCOTT *et al.* 1986; GÓMEZ-VILLAMANDOS

et al., 1991; KETTERER *et al.*, 1992), so the staining is not a specific criterion for assessing the occurrence of herpesvirus. A definitive diagnosis was achieved by electron microscopy.

The finding of the infection together with the death of animals living together with the affected pigeon suggest that it is necessary to carry out an epidemiological investigation of the disease in the region of Murcia, in which there is a great number of flocks (particularly for sport racing) and an active interchange of pigeons with other regions.

ACKNOWLEDGEMENTS

We gratefully acknowledge the technical assistance of J. Sánchez in light microscopy and F. Calderon and M. García in electron microscopy, and the critical revision of the final manuscript of Dr. Serrano.

REFERENCES

- BIGGS, P.M. (1982). The epidemiology of avian herpesviruses in veterinary medicine. *Dev. Biol. Standardization*, **52**: 3-11.
- CALLINAN, R.B., KEFFORD, B., BORLAND, R., GARRET, R. (1979). An outbreak of disease in pigeons associated with a herpesvirus. *Aus. Vet. J.*, **55**: 339-341.
- CARTWRIGHT, M., SPARKER, T.R., McCLUGGAGE, D. (1985). Psittacine inclusion body hepatitis in an aviary. *J. Amer. Vet. Med. Assoc.*, **187**: 1045-1046.
- CORNWELL, H.J.C., WEIR, A.R., FOLLET, E.A.C. (1967). A herpesvirus infection of pigeons. *Vet. Rec.*, **81**: 267-268.
- DOCHERTY, D.E., HENNIG, D.J. (1980). The isolation of a herpesvirus from captive cranes with an inclusion body disease. *Avian Dis.*, **24**: 278-283.
- GÓMEZ-VILLAMANDOS, J.C., MOZOS, E., SIERRA, M.A., FERNÁNDEZ, A., DÍAZ, F. (1991). Mortality in psittacine birds resembling Pacheco's disease in Spain. *Avian Pathol.*, **20**: 541-547.
- JYLLING, B. (1967). Oesophagitis in pigeons. *Nord. Veterinaermed.*, **19**: 415-419.
- KALINER, G. (1975). Intranuclear hepatic inclusion bodies in an African grey parrot. *Avian Dis.*, **19**: 640-642.
- KETTERER, P.J., TIMMIS, B.J., PRIOR, H.C., DINGLE, J.G. (1992). Inclusion body hepatitis associated with an adenovirus in racing pigeons in Australia. *Aus. Vet. J.*, **69**: 90-91.
- KRUPICKA, V., SMID, B., VALICEK, L., PLEVA, V. (1970). Isolation of a herpesvirus from a pigeon on the chorioallantoic membrane of embryonated eggs. *Vet. Med. (Prague)*, **15**: 609-612.
- LANDRE, F., VINDEVOGEL, H., PATORET, P.P., SCHWERS, A., THIRY, E., ESPINASSE, J. (1982). Frequence de l'infection du pigeon par le pigeon herpesvirus 1 et le virus de la Maladie de Newcastle dans le Nord de la France. *Rec. Méd. Vét. Ec. Alfort*, **158**: 523-528.
- LEHNER, N.D.M., BULLOCK, B.C., CLARKSON, T.B. (1967). Intranuclear inclusion disease of pigeons. *J. Amer. Vet. Med. Assoc.*, **151**: 939-941.
- MARE, C.J., GRAHAM, D.L. (1973). Falcon herpesvirus, the etiologic agent of inclusion body disease of falcons. *Infect. Immun.*, **8**: 118-119.
- MARTHEDAL, H.E., JYLLING, B. (1966). Oesophagitis in pigeons—presumably caused by virus. *Nord. Veterinaermed.*, **18**: 565-568.
- MILLER, T.D., MILLAR, D.L., NAGI, S.A. (1979). Isolation of Pacheco's disease herpesvirus in Texas. *Avian Dis.*, **23**: 753-756.
- PANIGRAPHY, B., GRUMBLES, L.C. (1983). Pacheco's disease in psittacine birds. *Avian Dis.*, **28**: 808-812.
- SAIK, J.E., WEINTRAUB, E.R., DITERS, R.W., EGY, M.A. (1986). Pigeon Herpesvirus: Inclusion body hepatitis in a free-ranging pigeon. *Avian Dis.*, **30**: 426-429.
- SCOTTO, P.C., CONDRON, R.J., REECE, R.L. (1986). Inclusion body hepatitis associated with adenovirus-like particles in a cockatiel (*Psittaciformes: Nymphicus hollandicus*). *Aust. Vet. J.*, **63**: 337-338.
- THOMPSON, E.J., GUMBRELL, R.C., WATSON, P.R. (1976). Herpesvirus infection of pigeons. *N. Z. Vet. J.*, **25**: 74.
- VETESI, F., TANY, J. (1975). Occurrence of a pigeon disease in Hungary caused by a herpesvirus. *Magy. Allatorv. Lapja*, **3**: 193-197.
- VINDEVOGEL, H., PASTORET, P.P. (1980). Pigeon herpesvirus infection: natural transmission of the disease. *J. Comp. Pathol.*, **90**: 409-413.